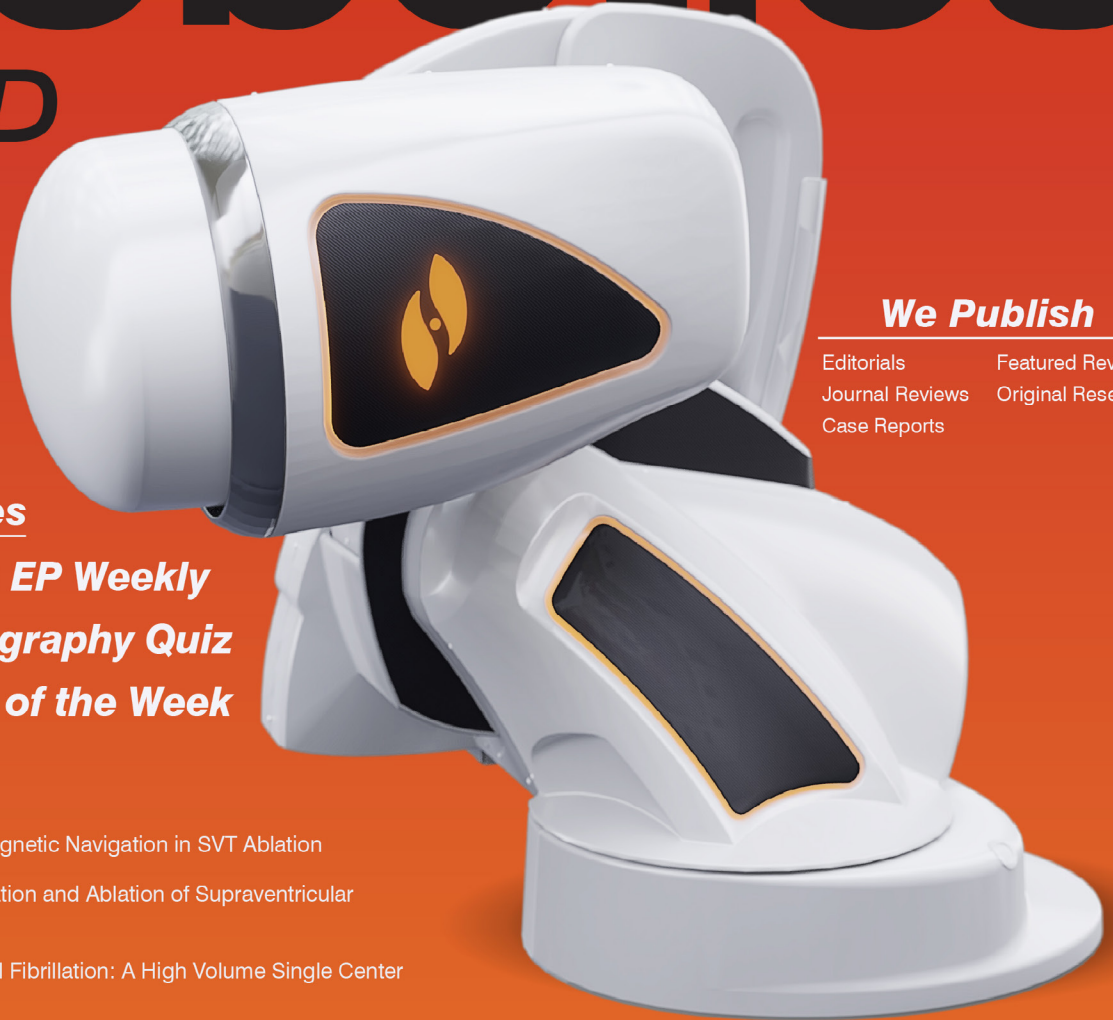

# Robotics

*in EP*



## **We Publish**

Editorials	Featured Reviews
Journal Reviews	Original Research
Case Reports	

## **Other Features**

**Ultrasound in EP Weekly**  
**Electrocardiography Quiz**  
**Case Snippet of the Week**

- Outcomes of Remote Magnetic Navigation in SVT Ablation
- Robotic Magnetic Navigation and Ablation of Supraventricular Tachycardia
- Robotic Ablation for Atrial Fibrillation: A High Volume Single Center Experience
- Remote Magnetic Ablation versus Manual Catheter Navigation in the Ablation of Accessory Pathways in Adults
- Remote Magnetic Catheter Ablation of Ventricular Arrhythmias with Rhythmia™ High Resolution Mapping System
- Telerobotic Navigation – A Comparison of Remote Magnetic Navigation in A Phantom with Operators 1200 km Apart
- Coronary Ostia Mapping With Remote Magnetic Navigation Can Facilitate Safe Mapping and Ablation of Outflow Tract Ventricular Arrhythmias

### **Editor-in-Chief**

Andrea Natale

### **Deputy Editors**

Amin M. Al-Ahmad | Luigi Di Biase  
Dhanunjaya Lakkireddy

### **Special Editors**

Tamas Szili-Török  
J.Peter Weiss

# Contents

May 2022

Robotics Special Issue



---

## INTRODUCTION:

### **Introductory Statement**

6

Tamas Szili-Török, J.Peter Weiss

---

### **Foreword: A Historical Review and Present day Evolution of Robotic Magnetic Navigation**

7

Gery Tomassoni

---

## ROBOTICS IN ATRIAL FIBRILLATION:

### **A Novel, Highly Efficient And Effective Minimally-Invasive Ablation Strategy for Remote Magnetic Navigation Guided Pulmonary Vein Isolation**

11

Anna M.E. Noten, Tamas Szili-Torok

---

### **Robotic Ablation for Atrial Fibrillation: A High Volume Single Center Experience**

17

Raffaele Corbisiero, Adam Guss

---

### **The Impact of Adoption of Fluoroless Robotic Navigation Ablation for Atrial Fibrillation on Procedural Time**

21

Pedram Kazemian, Adam Guss, Xu Lei

---

**ROBOTICS IN VENTRICULAR ARRHYTHMIAS:****A Review on the use of Remote Magnetic Navigation for Ventricular Tachycardia Ablation****26**

Adnan Ahmed, Rishi Charate, Naga Venkata K Pothineni, Domenico G. Della Rocca, Arshad Muhammad Iqbal, David Burkhardt, Luigi Di Biase, Amin Al-Ahmad, Rakesh Gopinathainnair, Andrea Natale, Dhanunjaya Lakkireddy

**Coronary Ostia Mapping With Remote Magnetic Navigation Can Facilitate Safe Mapping and Ablation of Outflow Tract Ventricular Arrhythmias****33**

William Reichert, Emrie Tomaiko-Clark, Wilber Su, Michael S. Zawaneh, Roderick Tung, J. Peter Weiss

**Acute and Long-Term Results of Catheter Ablation of Outflow Tract Arrhythmias Using Remote Magnetic Navigation with Catheter-Tissue Contact Feedback Technology: Comparison with Manual Ablation****38**

Leonor Parreira, Pedro Carmo, Rita Marinheiro, Jose Venancio, Duarte Chambel, Silvia Nunes, Joana Pinho, Rui Coelho, Diogo Cavaco, Francisco Costa, Pedro Adragao

**Robotic Magnetic Navigation in Premature Ventricular Complex Ablation****47**

Fengwei Zou, John D. Burkhardt, Xiaodong Zhang, Aung Naing Lin, Domenico Giovanni Della Rocca, Sanghamitra Mohanty, Amin Al-Ahmad, Dhanunjaya Lakkireddy, Andrea Natale, Luigi Di Biase

---

## **ROBOTICS IN SVTs:**

### **Remote Magnetic versus Manual Catheter Navigation in the Ablation of Accessory Pathways in Adults**

**52**

Gregory P. Siroky, Ameesh Isath, Hieu Huynh, Mena Yacoub, Asad Mohammad, Seth Keller, Ranjit Suri, Patrick Lam, Davendra Mehta

---

### **Outcomes of Remote Magnetic Navigation in SVT Ablation**

**57**

Krishna Akella, Rahul Doshi, Parker Lavigne, Rohan Trivedi, Sunil Pathak, Lydia Taranto, Juan Siordia, Adnan Ahmed, Mayank Sardana, David Riggio, Kethes Waram, Jamie Howard, Zoya Ahmad, Adam Sabbath, Nikhil Iyengar, David Rizik, Dhanunjaya Lakkireddy, J.Peter Weiss

---

### **Robotic Magnetic Navigation and Ablation of Supraventricular Tachycardia**

**62**

Gery Tomassoni, Kristie Schneider, Julie Ayers, Katie Nolan, Gwyn Middleton, Peter Gallagher

---

## **OPENEP: COLLABORATIVE TECHNOLOGY:**

### **First Human Experience with Catheter Ablation Using Dipole Charge Density Mapping Integrated in Robotics in The Management of Atrial Fibrillation**

**67**

Rita B. Gagyi, Anna M.E. Noten, Sip Wijchers, Sing-Chien Yap, Rohit E. Bhagwandien, Mark G. Hoogendijk, Tamas Szili-Torok

---



---

**Radiofrequency Ablation of Paroxysmal and Persistent Atrial Fibrillation Using EnSite Precision Mapping System and Robotic Magnetic Navigation: The Efficacy, Long-Term Follow-Up Outcome and Recurrence Risk Factors**

**73**

Shipeng Dang, Christian Jeons, Peter Karl Jacobsen, Steen Pehrson, Ru-Xing Wang, Xu Chen

---

**Remote Magnetic Catheter Ablation of Ventricular Arrhythmias with Rhythmia™ High Resolution Mapping System**

**81**

Johan D. Aasbo, Kristie Schneider, Gery F. Tomassoni

---

**Combined Use of Noninvasive ECG Localization and Robotic Catheter Manipulation for the Ablation of Ventricular Arrhythmias**

**89**

Sandeep G. Nair, Sean P. Mazer, Yaw A. Adjei-Poku, Michael T. Bestawros, and Michael H. Hoskins

---

**TELEROBOTICS:**

**Telerobotic Navigation – A Comparison of Remote Magnetic Navigation in A Phantom with Operators 1200 Km Apart**

**94**

Stefan Ailoei, Sam Griffiths, Piers Wright, Sabine Ernst

---



## Introductory Statement

Dear Readers,

On behalf of the Society for Cardiac Robotic Navigation, we wish to thank you for your interest in this issue of the Journal of Atrial Fibrillation and Electrophysiology focused on the use of Robotic Magnetic Navigation in the treatment of cardiac arrhythmias. For over a decade, magnetic navigation has been utilized in the treatment of virtually every arrhythmia that can be approached with ablation therapy. While the cadre of routine users to date has been relatively limited, the evolution of this technology and increasing recognition of its unique characteristics has created what seems to be an important inflection point. As Electrophysiologists continue to seek the optimization of safety, efficacy, and efficiency in the care of arrhythmia patients, the increasing adoption of robotics and automation is poised to play an essential role. The included manuscripts have been selected to present a broad range of experiences with this technology as described by expert providers. We hope that they provide education, motivation, and inspiration to all who are interested in moving the field forward.

For those who would like to become further involved, join us at [www.scrn-global.com](http://www.scrn-global.com)

Sincerely,




Dr. Tamas Szili-Török, MD  
Erasmus Medical Center, Rotterdam,  
The Netherlands



Dr. J. Peter Weiss, MD, MSC  
Banner University Medical Center  
Phoenix, AZ USA

Special thanks to our special edition reviewer,  
Brent Hagen, BSEE, MBA



## Foreword: A Historical Review and Present-day Evolution of Robotic Magnetic Navigation

Gery Tomassoni<sup>1</sup>

<sup>1</sup>Baptist Health Lexington, Lexington, Kentucky

### Description of the system

Robotic Magnetic Navigation (RMN) refers to a unique surgical robotic technology that utilizes precise externally applied magnetic fields to allow for direct distal tip control of flexible endovascular devices. The currently available RMN system (Stereotaxis, Inc., St Louis, MO, USA) consists of two computer-controlled large external magnets held by robotic arms next to the patient table, a computer interface, and magnetically tipped steerable endovascular devices. Through the generation of precise magnetic fields, the system directs and digitally controls the distal tip of endovascular devices within the heart and coronary/peripheral vasculature. The magnetic fields are less than 10% of the typical generated magnetic field strength by standard MRI equipment (generally 0.08-0.10 Tesla compared to 1.5-3.0 Tesla for MRI). The physician, seated outside the operating room in a control cockpit, uses an intuitive computer interface to maneuver a catheter or guidewire by adjusting the magnetic field around the patient. The generated magnetic field does not push or pull the device. Instead, the magnetic field changes the direction of the device by deflecting its distal tip omnidirectionally in 3D space. The operator can advance or retract the device in the cardiovascular anatomy with the aid of a computerized motor drive system. The mechanism of action eliminates the need for traditional stiff endovascular devices with pull-wires.

RMN results in the delivery of a soft tipped catheter or guidewire that is not only safe to advance within the vascular space but also allows for precise control, stability, and excellent maneuverability. Because the catheter or guidewire tip is controlled by the external magnetic fields, the physician has the same degree of control regardless of the number or type of turns, or the distance traveled in order to arrive at its final position.

### Key Words

Remote Magnetic Navigation, Stereotaxis

### Corresponding Author

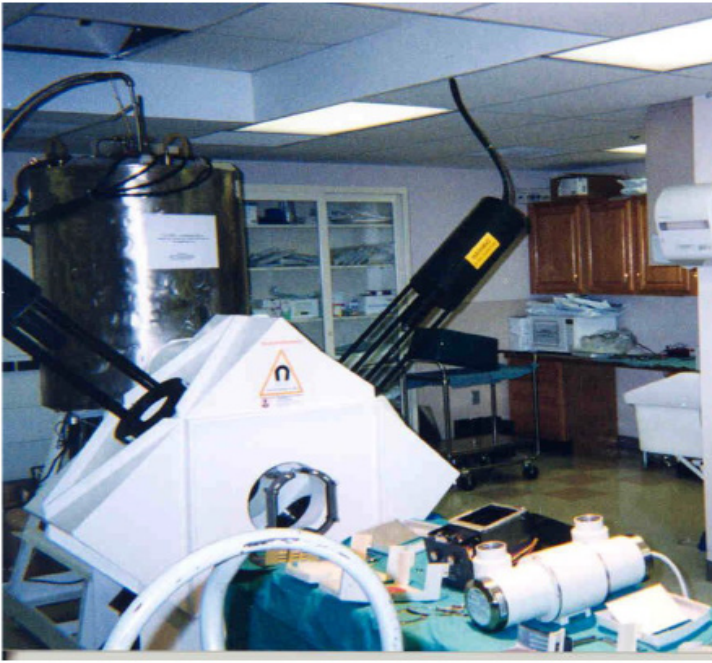Gery Tomassoni,  
Baptist Health Lexington, Lexington, Kentucky

### The Beginning

RMN was originally conceived in 1984 as a way to provide true stereotactic navigation to treat brain tumors using electromagnets. The technology was first tested in 1987, with magnetic “seeds” successfully being navigated to target sites in a canine brain. Stereotaxis as a company was founded in 1988 to bring to clinical fruition the work of Drs. Howard, Grady, and Ritter. A first-generation interventional workstation (Figure 1) was installed at Barnes-Jewish Hospital in St. Louis in 1995 where pre-clinical work continued. In 1996, catheter delivery of therapies added a new mode of magnetic navigation, leading to a successful brain biopsy technique in the first human clinical trial in 1998.

As the technology continued to develop, it became apparent that the inherent advantages of magnetic navigation had broader applicability than neurology. In 2000, the FDA approved the commencement of human trials for its first endovascular applications: cardiac electrophysiology (EP) and interventional neuroradiology using the new electromagnetic Telstar system (Figure 2). In 2001, the first human EP procedure was performed using Stereotaxis confirming its safety for intracardiac navigation, recording, and pacing. FDA approval of the first magnetic guidewire in 2002 led to both coronary and peripheral vasculature use. Subsequently from 2001 to 2008, the development of several new guidewire models led to expanding indications for its use in both neurovascular and peripheral arterial disease (PAD).

While the electromagnet approach was successful as proof-of-concept, the required infrastructure for hospitals to support the system proved too great for broad adoption. In 2001, Stereotaxis began developing a newer system utilizing permanent magnets, called the Niobe system. The first installation of this system (Figure 3) occurred in 2003 at Central Baptist Hospital in Lexington, Kentucky. The first European system was installed at St. George in Hamburg, Germany later that same year.



**Figure 1:** MS-6 installed at Barnes-Jewish Hospital

The Niobe system was followed by the development of a Niobe II system in 2004, which added the ability to tilt the magnetic pods to support steeper imaging angles and allow use in larger patients. This product drove a significant increase in the use of both interventional cardiology (IC) coronary/peripheral guidewire applications and in EP. At that time, Stereotaxis was used in EP procedures for guidewire directed coronary sinus lead delivery during cardiac resynchronization therapy (CRT) implant. Development of a magnetic ablation catheter and integration with a 3D catheter localization/mapping system (CARTO, Biosense, Johnson & Johnson, Irvine, CA) resulted in direct real-time catheter visualization without fluoroscopy, creation of electrical anatomical maps, and guided radiofrequency energy delivery for ablation of arrhythmias. This led to a more widespread adoption of Stereotaxis in the expanding catheter ablation arena for the treatment of supraventricular tachycardia (SVT), atrial fibrillation (AF), and ventricular tachycardia (VT).

### Focus on EP

It quickly became evident through the early experience in EP that there was a need for additional technology in order for RMN to reach its full potential. Allowing physicians to perform the majority of a catheter ablation procedure in the control room provided the unique opportunity to have direct hands-on utilization of the recording, mapping, and ablation systems. Unfortunately, significant practical limitations existed in interacting with multiple systems as each system had their own monitor, keyboard, and mouse. The large monitor screen solutions that were available at that time allowed consolidation of the multiple systems' data by organizing their images on a single large screen. Unfortunately, the recording, mapping, and ablation devices were not controlled by a single system. Therefore, the Odyssey system was conceived to not only allow a user to see all relevant data/images on a single screen but also to provide a single keyboard and mouse to control each system. The first Odyssey system was installed in 2007, with subsequent installation of a higher resolution system in 2009.

With the release of irrigated ablation catheters in 2008, the growing interest in Stereotaxis for complex cardiac ablation procedures drove the decision to focus on EP exclusively. Over the ensuing few years, several additional products were developed. Odyssey Cinema added the ability to both record and observe procedures remotely. Vdrive provided a mechanical robotic platform to manipulate sheaths and diagnostic catheters without the need for magnetic navigation. Niobe ES was introduced in 2011 resulting in faster response times to user inputs, new computer-assisted catheter navigation, and a simplified interface. At that time, the following RMN advantages were observed: 1) significant reduction in procedural complications and radiation exposure to both the patient and physician, 2) the ability of the catheter to reach even the most challenging locations, 3) improved catheter stability with stable continual contact with cardiac tissue, and 4) enhanced physician comfort with lead burden reduction. The next piece of the puzzle was to focus on procedural efficiency. A best practices program was introduced in 2012 that would enable physicians to significantly reduce procedure times while maintaining the advantages previously described.

### Data & Benefits of RMN Today

Today, RMN in EP has resulted in the treatment of more than 130,000 patients in institutions ranging from small community hospitals to larger teaching and academic centers (Figure 4). The impact of RMN on catheter ablation of AF, VT, and SVT in both pediatric, congenital, and adult populations has been demonstrated in over 400 journal articles. While still a small part of the EP ecosystem, RMN has demonstrated distinct clinical advantages over other catheter-based approaches.

In a recent meta-analysis of RMN for VT ablation which included 13 studies and 1348 patients, Blandino et al.<sup>1</sup> showed superior acute ablation success rates, a better safety profile, and significant fluoroscopy reduction with RMN compared to both standard and contact-force sensing catheters. In AF ablation, a second meta-analysis of RMN including 14 studies and 3375 patients (Ghadban et al.<sup>2</sup>) demonstrates lower complication rates and fluoroscopy time (mean difference 18.01 minutes), with similar success rates. Noten et al.<sup>3</sup> showed significantly reduced recurrence rates in patients treated for AVRT with RMN compared to both manual catheter ablation as well as cryoablation. After a mean follow-up of 5.5 years, recurrence rates were 4.3% for RMN, 15.6% for manual ablation, and 54.5% for cryoablation,  $p < 0.001$ . They postulated that the improved outcome of RMN in AVRT ablation is an affirmation of improved catheter stability.

Congenital heart disease patients with complex arrhythmias have benefitted greatly from RMN. The omnidirectional steering capability of the magnetic catheter provides the ability to reach the desired target even in the most tortuous anatomies. SVT RMN procedures using the retrograde aortic approach in patients with previous intra-atrial baffle procedures or interrupted IVC access<sup>4</sup> have been reported and are just some of the complex arrhythmias ablated in this complicated patient population.

The reduction in fluoroscopy time benefits not only patients, but also physicians. The overall reduction in radiation exposure reported does not even include major advantages to the physician who is completely



out of the radiation field during much of the procedure. Prolonged physician radiation exposure has been linked to cancer<sup>5</sup>, cataracts<sup>6</sup>, and infertility<sup>7</sup>. Reducing fluoroscopy exposure by 20 minutes per procedure for a physician doing 200 ablations a year for 30 years would reduce lifetime exposure by 2,000 hours.

While not formally studied, there is growing evidence that RMN can reduce a physician's risk of developing chronic muscular and orthopedic disorders by removing the burden of lead and need for prolonged standing. When using the Stereotaxis system, electrophysiologists with chronic orthopedic issues can still conduct even the most complex procedures, potentially allowing them to practice for a longer period of time. Finally, RMN has the ability to provide remote support via a call center. This not only includes procedure and system diagnostics support, but also includes physician-to-physician proctoring which has been particularly useful during the recent pandemic.

### New Technological Advances & Future Direction

Despite growing clinical evidence supporting the benefits of RMN in EP for both patients and physicians, overall adoption of RMN has remained limited. Only about 1% of cardiac ablation procedures globally are performed with RMN. Since 2017, new management in Stereotaxis has led to an innovative strategy with the following key goals: 1) making robotics broadly accessible by reducing structural and cost barriers to adoption, 2) revitalizing the EP portfolio by facilitating an open ecosystem around robotics and next generation catheters with improved performance, 3) expanding RMN as a platform technology that addresses endovascular navigation challenges more broadly, and 4) advancing digital surgery as an added dimension to robotics that improves connectivity, intelligence, and automation in the operating room.

Genesis, introduced in 2020 (Figure 5), was the first significant structural redesign in an RMN system since the original launch of Niobe. It incorporated a new "center of mass" design that allows for smaller magnets placed closer to the patient to generate the same magnetic field strength. The system reduced the overall size, weight, and complexity of constructing a RMN lab. Also, it addressed long-standing latency in Niobe and is significantly faster than Niobe ES with near instantaneous responsiveness. Along with Genesis, Stereotaxis introduced the Model S fluoroscopy system as a tightly integrated imaging solution. By offering both large capital systems in combination, Stereotaxis was able to reduce the cost of acquisition and complexity of installation. Next generation RMN systems are being developed with the goal of further simplifying the installation process by requiring no construction of operating rooms whatsoever. As a result, alternative financing models can be employed which will allow more hospitals to adopt and benefit from the technology.

In EP, an exclusive ecosystem that allowed for only one ablation catheter and mapping integration has gradually evolved towards a robust open ecosystem around RMN. A new software upgrade introduced the Open Mapping API architecture supporting broader use of RMN with various intraoperative and preoperative mapping systems. The AcQMap System from Acutus Medical (Carlsbad, CA) was the first mapping system to utilize this new capability in 2021. Preoperative Imaging Import allows for the use of advanced diagnostic

tools via the import of 3D models including VIVO (Catheter Precision, Ledge wood, NJ, USA), inHEART (Pessac, France) and ADAS 3D systems (Barcelona, Spain). Stereotaxis has also developed a new investigational catheter. The catheter has increased magnet strength, optimized magnet placement for improved navigation, reduced irrigation flow requirements, an improved ablation tip, and will support an open ecosystem. Development of the catheter has facilitated a pipeline of future catheters that will include different energy sources such as pulsed field and cryoablation.

Beyond EP, Stereotaxis looks to address emerging endovascular medical device markets where complex vasculature is difficult to navigate. Five specific clinical areas with unmet medical need are currently under investigation: neuro intervention, coronary angioplasty, tumor embolization, peripheral arterial disease, and abdominal aortic aneurysm grafts. New magnetic guidewires, microcatheters, and guide catheters are under development to facilitate expansion into these areas. The use of RMN will allow for precise and efficient navigation through tortuous vasculature with improved safety and reduced radiation.

Finally, Stereotaxis has been advancing the nascent concept of digital surgery. Odyssey Cinema, along with Open Mapping API and Preoperative Imaging Import have laid the foundation in the emerging area of digital surgery. Broad connectivity in operating rooms leveraging Odyssey Cinema's connectivity technology will improve technical and clinical support by industry, collaboration between physicians, education and training on new technology, and remote procedures. The incorporation of various preoperative and intraoperative patient-specific imaging into the RMN system allows for image guided surgery with improved display of relevant patient data to the physician operator. Automation algorithms are being developed and improved to enable autonomous navigation of devices in an efficient and safe fashion.

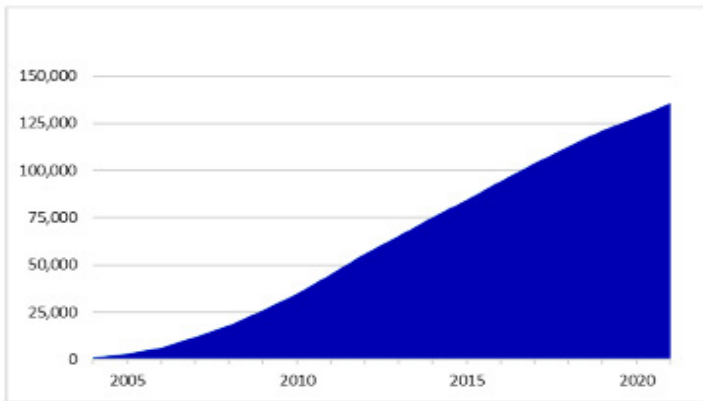
The promise of broad availability of Stereotaxis systems with a family of compatible EP and endovascular devices, enhanced with the intelligence of digital surgery, point to RMN becoming an increasingly relevant and necessary technology for the modernization of endovascular intervention and improvement of care in our field.

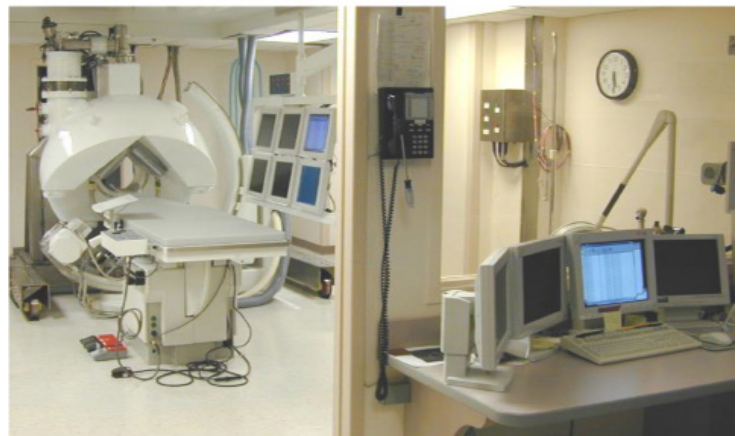
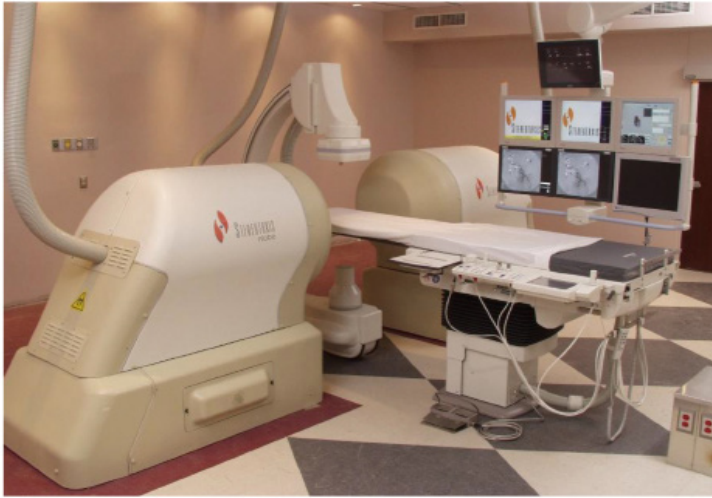
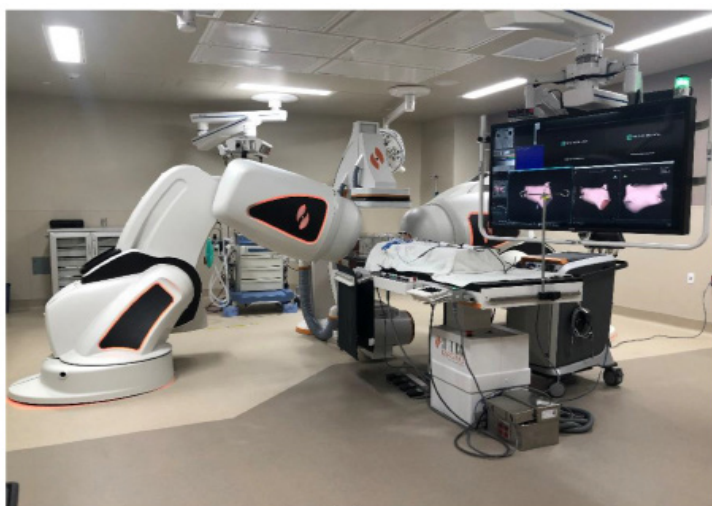Figure 2: First Telstar installation at Barnes-Jewish Hospital



**Figure 3:** First Niobe installation at Central Baptist Hospital.



**Figure 4:** Global Cumulative RMN Procedures using Stereotaxis since 2004



**Figure 5:** Genesis at Banner University Medical Center.

## References

1. Blandino A, Bianchi F, Sibona Masi A, Mazzanti A, D'Ascenzo F, Grossi S, Musumeci G. Outcomes of manual versus remote magnetic navigation for catheter ablation of ventricular tachycardia: a systematic review and updated meta-analysis. *Pacing Clin Electrophysiol.* 2021 Jun;44(6):1102-1114.
2. Ghadban R, Giffit K, Luebbing Z, Sodhi S, Cooper D, Enezate T. Radiofrequency atrial fibrillation ablation with irrigated tip catheter using remote magnetic navigation compared with conventional manual method. *J Interv Card Electrophysiol.* 2021 Oct;62(1):95-102.
3. Noten AME, Kammeraad JAE, Ramdat Misier NL, Wijchers S, van Beynum IM, Dalinghaus M, Krasemann TB, Yap SC, de Groot NMS, Szili-Torok T. Remote magnetic navigation shows superior long-term outcomes in pediatric atrioventricular (nodal) tachycardia ablation compared to manual radiofrequency and cryoablation. *Int J Cardiol Heart Vasc.* 2021 Oct;1(37):100881.
4. Ernst S, Babu-Narayan S, Keegan J, Horduna I, Lyne J, Till J, Kilner P, Pennell D, Rigby M, Gatzoulis M. Remote-Controlled Magnetic Navigation and Ablation With 3D Image Integration as an Alternative Approach in Patients With Intra-Atrial Baffle Anatomy. *Circ Arrhythmia Electrophysiology.* 2012;5(1):131-139.
5. Roguin A, Goldstein J, Bar O, Goldstein JA. Brain and neck tumors among physicians performing interventional procedures. *Am J Cardiol.* 2013;111(9):1368-72.
6. Vano E, Leiman NJ, Duran A, Romano-Miller M, Rehani MM. Radiation-associated lens opacities in catheterization personnel: results of a survey and direct assessments. *J Vasc Interv Radiol.* 2013;24(2):197-204.
7. Anderson M, Goldman R. Occupational Reproductive Hazards for Female Surgeons in the Operating Room: A Review. *JAMA Surg.* 2020;155(3):243-249.





### A Novel, Highly Efficient And Effective Minimally-Invasive Ablation Strategy for Remote Magnetic Navigation Guided Pulmonary Vein Isolation

Anna M.E. Noten<sup>1</sup>, Tamas Szili-Torok<sup>1</sup>

<sup>1</sup>Department of Cardiology, Erasmus MC, University Medical Center, Rotterdam, the Netherlands

#### Abstract

**Background:** Atrial fibrillation (AF) is the most common cardiac arrhythmia for which catheter ablation (CA) is considered a first-choice treatment option. Because of the expanding AF pandemic, there is need for highly efficient and effective CA strategies. Pulmonary vein isolation (PVI) is a pivotal part of any AF ablative strategy. Currently, multiple ablation techniques are being utilized to realize PVI, including Remote Magnetic Navigation (RMN) guided radiofrequency (RF) ablation. This study aimed to systematically describe and evaluate a novel, minimally-invasive RMN-guided PVI strategy.

**Methods:** This study retrospectively included a series of consecutive patients diagnosed with AF who were treated with a novel minimally-invasive RMN-guided PVI strategy between September 2020 and March 2021. Primary outcomes were both procedural efficiency (i.e. LA access time, mapping time, procedure time) and efficacy (first-pass isolation (FPI) and acute success rates).

**Results:** This case series included 14 patients. Efficiency outcomes: The mean total procedure time was  $63.1 \pm 13.5$  minutes. LA access time was  $6.5 \pm 1.9$  minutes. Mapping was completed in  $7.1 \pm 1.4$  minutes. Efficacy outcomes: We observed a 100% FPI rate in right-sided and a 57% FPI rate in left-sided PVs. In all cases there was successful PV isolation at the end of procedure. There were no adverse events.

**Conclusion:** In conclusion, a novel, minimally-invasive RMN guided PVI strategy yields high efficiency, with short procedure and fluoroscopy times, in addition to efficacious PVI.

#### Introduction

Atrial fibrillation (AF) is the most common cardiac arrhythmia with a reported adult prevalence between 2 and 4%<sup>1</sup>. Due to the increasing life expectancy and growing incidence of risk factors of AF, a 2.3 fold rise of the AF burden is expected the next decades<sup>1-3</sup>. Furthermore, AF has a progressive disease course which is characterized by progressive structural atrial remodeling and worsening atrial cardiomyopathy during the transition of a paroxysmal to persistent state<sup>4,5</sup>.

Early rhythm control interventions such as catheter ablation (CA) offer an opportunity to halt the progressive anatomical changes associated with AF<sup>6</sup>. Therefore, CA is considered a first-choice treatment option for symptomatic patients with AF, especially once treatment with anti-arrhythmic drugs (AAD) has failed<sup>1</sup>. A pivotal

part of any AF ablative strategy is the electrical isolation of the pulmonary veins (PVs)<sup>7</sup>, which can be achieved by multiple ablation techniques. These include manual point-by-point radiofrequency (RF) ablation and manual ablation using single-shot devices such as the cryoballoon<sup>1,8,9</sup>. Long-term recurrence rates and adverse events were comparable between these two techniques, whereas cryoablation had a slightly shorter procedure time, but higher fluoroscopy exposure, when compared to manual point-by-point RF ablation<sup>8,9</sup>.

Remote magnetic navigation (RMN)-guided ablation provides an alternative RF CA strategy. In RMN, two external permanent magnets are utilized to remotely direct the movement of the ablation catheter by magnetic fields.<sup>10</sup> Various publications reported on the benefits of RMN due to precision of catheter movement, its soft tip and its stability, causing superior lesion formation<sup>11</sup> and improved procedural safety<sup>12-14</sup>. In addition, RMN exhibited significant improvement of procedural efficiency in AF ablation during the last years<sup>15</sup>. Because of the expanding AF pandemic, there is need for highly efficient and effective ablation strategies. Therefore, we present a novel, rapid, effective and minimally-invasive RMN-guided CA strategy for PVI.

#### Key Words

Remote Magnetic navigation; Radiofrequency Ablation; Pulmonary Vein Isolation; Atrial Fibrillation

#### Corresponding Author

Tamas Szili-Torok, MD, PhD  
Thoraxcenter, Department of Clinical Electrophysiology, Erasmus MC  
Postbus 2040, 3000 CA Rotterdam, The Netherlands

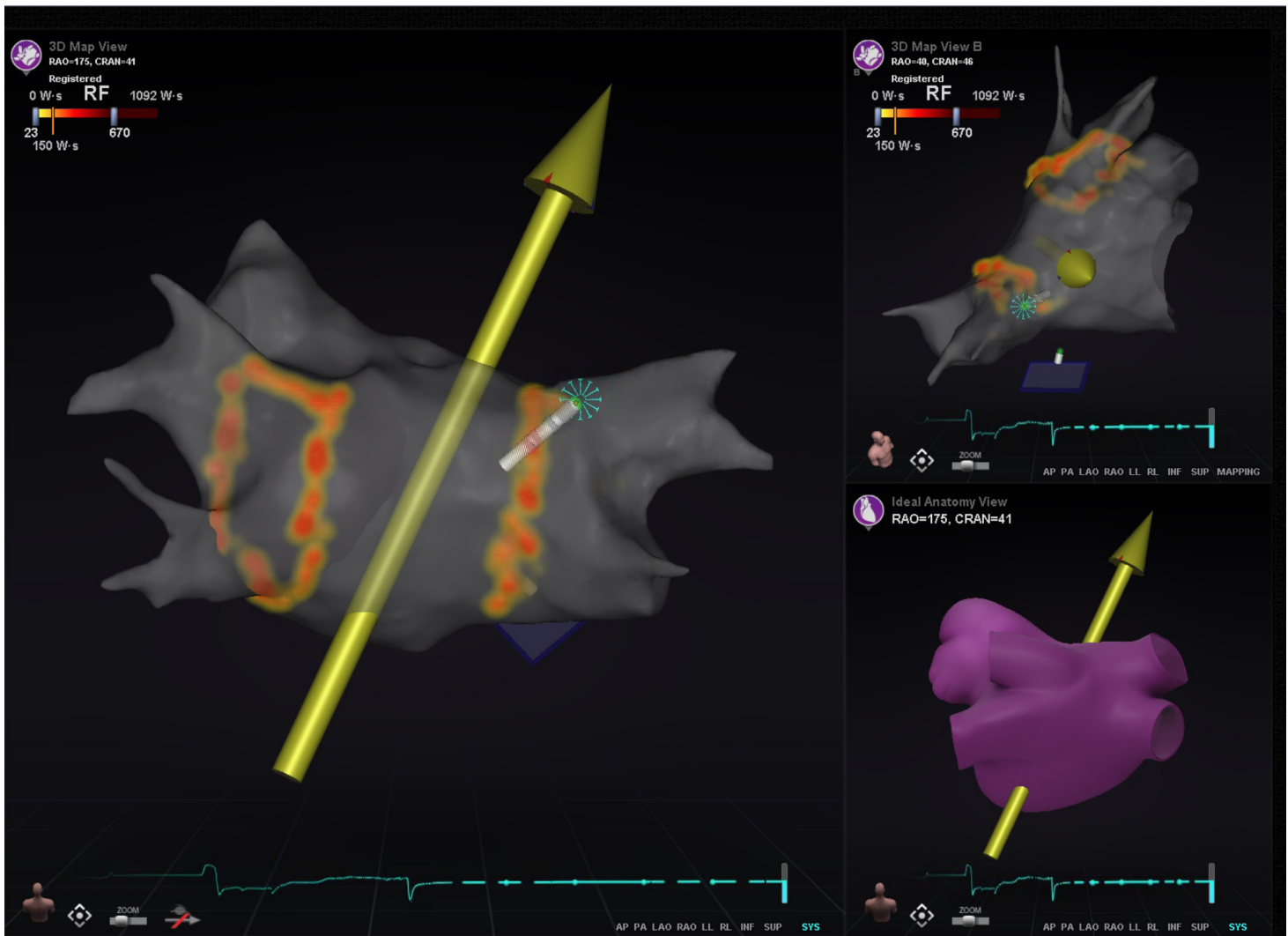


Figure 1:

## Carto 3-D image of completed PVI

This figure displays the Carto 3-D images of one of the patients included in this study at the end of the procedure. At the left panel a postero-anterior view of the LA is presented. The Ablation History feature shows the applied therapy of the left-sided and right-sided WACA lines in yellow-orange. The ablation catheter is in good contact with myocardial tissue, as is displayed to the operator by a dense blue starburst at the catheter tip.

LA: left atrium, PVI: pulmonary vein isolation, WACA: wide area circumferential ablation

## Methods

### Design and population

This case series retrospectively included patients diagnosed with AF who were treated with our novel minimally-invasive RMN-guided pulmonary vein isolation (PVI) strategy. Patients were included between the 1st of September 2020 and the 30th of March 2021. Redo procedures were excluded. All patients were eligible for AF ablation based on the current ESC Guideline recommendations<sup>1</sup>. Primary outcomes were both procedural efficiency and efficacy. Procedural efficiency was characterized by the following parameters: total procedure time, time to left atrial (LA) access, total mapping time, total ablation time. Efficacy parameters included: first pass isolation rates, touch up (TU) rates, acute procedure success (i.e. successful isolation of all PVs at the end of procedure) and AF recurrence rates during follow-up. Patients were included from a single, high-volume CA center. Because of the large appliance of adjunctive therapies, as well as participation in other studies of this center, only a few patients were

initially selected to be treated by this novel ablation approach. The study protocol conforms to the ethical guidelines of the 1975 Declaration of Helsinki. The local medical ethics committee determined this study protocol (as part of the Safety and Efficacy Registry of Catheter Ablation registry - SERCA2 - MEC number 2021-029I) was not subject to the Dutch Medical Research Involving Human Subjects Act (WMO). Written informed consent was obtained from all the patients prior to the ablation procedure.

### Data collection

Baseline demographic and clinical characteristics were collected from the institutional electronic patient dossier. Procedural data was derived both from the electronic medical files, as well as from the electronic procedural log files recorded with the Claris (Abbot, St. Paul, MN, USA) and Odyssey Cinema (Stereotaxis Inc., St. Louis MO, USA) systems. All patient information was de-identified.

**Table 1: Baseline demographic and clinical data**

	All Patients (N = 14)
Age (years)	56.5 ± 11.5
Female	4 (28.6%)
BMI (kg/m <sup>2</sup> )	27.9 ± 2.6
Paroxysmal AF	10 (71.4%)
Hypertension	8 (57.1%)
Diabetes Mellitus	1 (7.1%)
Heart failure	2 (14.3%)
Ischemic heart disease	1 (7.1%)
HCM	2 (14.3%)
OSAS	1 (7.1%)
CVA / TIA	0 (0.0%)
Pulmonary embolism	1 (7.1%)
CHA <sub>2</sub> DS <sub>2</sub> -VASC 0	4 (28.6%)
CHA <sub>2</sub> DS <sub>2</sub> -VASC 1	1 (7.1%)
CHA <sub>2</sub> DS <sub>2</sub> -VASC ≥ 2	9 (64.3%)
Beta-blocker	8 (57.1%)
Amlodaron	1 (7.1%)
Flecainide	3 (21.4%)
Sotalol	3 (21.4%)
Verapamil	1 (7.1%)
Ritmoforine	1 (7.1%)
DOAC	14 (100.0%)
LV EF ≥ 55%	10 (71.4%)
LV EF 45 - 54%	4 (28.6%)
LAVI (ml/m <sup>2</sup> )	39.7 ± 10.5

AF: atrial fibrillation, BMI: body mass index, CVA: cerebrovascular accident, DOAC: direct-acting oral anticoagulant, EF: ejection fraction, HCM: hypertrophic cardiomyopathy, LAVI: left atrial volume indexed to body surface area, LV: left ventricular, OSAS: obstructive sleep apnea syndrome, TIA: transient ischemic attack

### Novel Minimally-Invasive PVI strategy

Pre-operatively, PV anatomy was evaluated in all patients with a CT-scan, as well as evaluation of presence of an intra-cardiac thrombus by trans-esophageal echocardiography (TEE). All procedures were performed under general anesthesia. The procedure started with a single groin, double puncture to obtain vascular access. Then, two 8.5 Fr sheaths were placed in the right femoral vein. Subsequently TEE guided transseptal puncture (TSP) was performed, using an EP Swartz SL1 sheath (Abbott, Chicago, IL, USA) and an NRG transseptal needle (Baylis Medical, Mississauga, Canada). In this case series we did not use ICE-guidance for TSP. Passive recrossing of the intra-atrial septum was performed using the Agilis 8.5Fr NTX medium curl sheath (Abbott) and a flexible wire, to obtain double transseptal LA access. A 20-electrode Lasso 2515 variable mapping catheter (Biosense Webster, Diamond Bar, CA, USA) and the ablation catheter (via the Agilis sheath) were advanced into the LA subsequently. We did not position any other diagnostic catheters, not even in the coronary sinus.

Anatomic FAM/CARTO mapping of the body of the LA was performed sweeping the Lasso catheter around the LA. Once the map of the body of the LA (low FAM resolution) was created, all side branches of all PVs in the LA were mapped more in-detail using the ablation

catheter (switched to high FAM resolution > 15). After completion of mapping, PVI was performed by wide-area-circumferential-ablation (WACA) of the PVs. At first ablation of both left-sided PVs was performed until successful isolation, followed by isolation of both right-sided PVs, or vice versa. The WACA's were applied using relatively high power settings, with continuous dragging of the ablation catheter while ablating. Catheter positioning was constantly optimized using real-time feedback provided by the 'Ablation History' and 'e-Contact Module' (ECM). RMT specific power settings were: posterior wall- 45 W, flow 17ml/min, maximum 43°C; other LA locations- 50 W, flow 17ml/min, maximum 43°C. When the PV encirclement (i.e. completion of the WACA-line) did not result in successful isolation of the PVs, additional TU's were performed until PV isolation. After successful isolation of both left- and right-sided PVs, a standard of ten minutes waiting time was applied to identify early PV reconnection. Sheaths and catheters were removed when there was complete electrical isolation of all PVs at the end of the waiting time. The Niobe ES Remote Magnetic Navigation system (Stereotaxis, St Louis, MO, USA), the CARTO (Biosense Webster, Diamond Bar, CA, USA) mapping system and the Navistar RMT Thermocool catheter (Biosense Webster) were used in all cases. All procedures were performed by a single operator.

### The Ablation History

Ablation History provides a 3-dimensional visual display of the history of the catheter's power output and duration of energy application at each location at the Carto map during the ablation. Based on the applied Watt\*s at every location, targets are colored yellow (short application duration and/or low power applied) to orange (long application duration and/or high power applied) on the 3D Carto screen (Figure 1). This is real-time visualized to the operator while ablating. Post-procedurally, we were able to calculate and evaluate the applied therapy from the ablation history data. Based on the location of the applications as visualized in the ablation history, ablation lines were drawn for both WACA lines. Each WACA ablation line is smoothed by using a moving average of the original line points within +/- 4mm. A square with dimensions 10x10mm is swept across the ablation line with 0.5mm steps; at each step the square is centered on the smoothed line, oriented so the squares normal points in the direction of the smoothed line. Each 1mm cubical voxel intersected by the square is sampled to find the maximum Watt\*s value of the square on that position. The average Watt\*s of each WACA line is then calculated by averaging the maximum Watt\*s values across the line.

### The e-Contact Module

The e-Contact Module (ECM) is a hardware and software module compatible with the Niobe ES RMN system, that incorporates 16 variables of three categories (including: electrical impedance measurements, cardiac induced motion of the tip, and the torque being applied by the magnetic field) to determine whether the RMN-guided catheter is in contact with cardiac tissue or not. The characteristics of the ECM have previously been described more in-detail<sup>16</sup>. The contact assessment is real-time visualized to the user as a starburst near the catheter tip. When there is minimally contact, the starburst is small, whereas in optimal contact the starburst is bold (Figure 1). This allows the operator to constantly optimize catheter contact while ablating.



**Table 2: Procedural Efficiency**

	All Patients (N = 14)
LA access time (min)	6.5 ± 1.9
Mapping time (min)	7.1 ± 1.4
Ablation time (min)	33.7 ± 9.1
Total procedure time (min)	63.1 ± 13.5
Fluoroscopy time (min)	12.0 ± 3.8
Fluoroscopy dose (mGy)	105.4 ± 33.6
DAP (mGy*cm <sup>2</sup> )	8565 ± 2215
Application duration (s)	1137 ± 186
Application count	15 ± 5

DAP: dose area product, LA: left atrium

## Definitions

Total procedure time was defined as the time from first puncture until the removal of sheaths. LA access time was defined as the time from first groin puncture until double transseptal LA access was achieved. The mapping time was described by the time from first mapping point taken until completion of the map, whereas ablation time was defined as the time from first RF application until last RF application. First pass isolation (FPI) was regarded when completion of the WACA-line resulted in successful PV isolation. If this first encirclement of PVs did not result in isolation of the PV, additional applications were regarded TU. Acute procedure success was regarded when there was complete electrical isolation of all PVs at the end of procedure, to be demonstrated by either: entry block or exit block of paced or spontaneous beats or exit block of PV ectopy.

## Statistical analysis

Normality was assessed by the Shapiro-Wilk test. Mean and standard deviation (SD) were calculated for normally distributed continuous variables. Median and interquartile range (IQR) were computed for continuous variables with non-normal distribution. Descriptive statistics for categorical data were expressed in absolute numbers and percentages. The data was analyzed using SPSS 26.0 (SPSS Inc., Chicago, IL, USA).

## Results

### Baseline Demographic and Clinical data

In total, 14 consecutive patients were included into this analysis using the novel ablation strategy within the mentioned time frame. Baseline demographic and clinical data is presented in Table 1. Patients had a mean age of 56.5 ± 11.5 years and mean body mass index (BMI) of 27.9 ± 2.6 kg/m<sup>2</sup>. The majority of patients had paroxysmal AF (78.6%) and used various types of AAD as rhythm control treatment strategy. Most patients had a normal left ventricular (LV) ejection fraction (EF) (71.4%) and mild LA dilatation (mean LAVI 39.7 ± 10.5 ml/m<sup>2</sup>).

### Procedural Efficiency

The mean time from groin puncture to double transseptal access (LA access time) was 6.5 ± 1.9 minutes. Mapping was completed in 7.1 ± 1.4 minutes. The ablation part of the procedure took 33.7 ± 9.1 minutes, with an average of 15 ± 5 applications and application duration of 1137 ± 186 seconds. This resulted in a mean total procedure time of 63.1 ±

13.5 minutes. The fluoroscopy time was 12.0 ± 3.8 minutes, with a mean dosage of 105.4 ± 33.6 mGy being applied.

### Procedural Efficacy and Safety

In left-sided PVs, FPI was observed in 57.1% of cases, whereas a 100.0% FPI rate was noted regarding right-sided WACA's. Early PV reconnection was observed in 2 patients (14.3%), for which additional applications resulted in complete PV isolation at the end of procedure. A 100.0% acute success rate was observed. The Ablation History data showed that the mean applied therapy at left-sided WACA was 341.27 ± 208.3 W\*s. Regarding right-sided WACA's the mean therapy applied was 305.6 ± 195.1 W\*s.

At a mean follow-up of 6.7 months, 80.0% of patients were free from paroxysmal AF recurrence. This study included few patients with persistent AF, in which AF recurrence was more frequently observed (2 out of 4 patients; 50.0%). No peri-procedural adverse events occurred in this study. During follow-up, one patient had a mildly elevated right-sided hemidiaphragm possibly caused by phrenic nerve injury.

## Discussion

This series of cases presents a novel, minimally-invasive ablation strategy for RMN-guided PVI. Our main finding is that this approach resulted in a highly efficient procedures, in addition to quasi perfect acute efficacy and, regarding paroxysmal AF, respectable 6-month recurrence rates.

### Procedural Efficiency

In this series of cases, a novel, very efficient RMN-guided PVI strategy is demonstrated with a procedure time just above one hour. Previously, several large meta-analysis reported much longer procedure times, ranging from 112 to 276 minutes<sup>17-19</sup>. Cryoballoon utilization had a slight advantage on the total procedure time compared to point-by-point RF guided PVI<sup>8,9,17-19</sup>. A recently published, global cryoablation AF registry – including almost 3000 patients – reported an improved mean procedure time of 82 minutes<sup>20</sup>. Procedure times observed in this study, are considerably lower than any of the reported major trials in literature. We attribute the improved procedural efficiency to several developments in our procedural set-up as well as our ablation strategy. First of all, we used a minimally invasive approach employing double puncture of a single groin, using only two sheaths and catheters. In this manner, double transseptal access was achieved well within 10 minutes. Second, mapping was advanced by the use of a 20-electrode Lasso catheter to create a general map of the LA body, which has the

**Table 3: Procedural Efficacy**

	All Patients (N = 14)
FPI left WACA	8 (57.1%)
TU left WACA	6 (42.9%)
FPI right WACA	14 (100.0%)
TU right WACA	0 (0.0%)
Intraprocedural PV reconnection with reablation	2 (14.3%)
Acute success	14 (100.0%)
Freedom of Paroxysmal AF*	8 out of 10 (80.0%)

\* at a mean follow-up duration of 6.7 months

FPI: first pass isolation, PV: pulmonary vein, TU: touch-up, WACA: wide area circumferential ablation

advantage of assembling multiple mapping points while it is swept across the LA. Third, the standard 30 minutes of waiting time to identify early PV reconnection were reduced to 10 minutes. Intraprocedural testing for PV reconnection with a 30 min waiting phase, ATP testing, or a combination of both did not improve freedom from AF at 3 years of follow-up in a randomized trial<sup>21</sup>. In addition to the changes in procedural set-up, the ablation strategy itself was improved. Real-time feedback on catheter position, tip-tissue contact (provided by the ECM) and the applied therapy (provided by the Ablation History), enabled comfortable moving of the catheter without the need of fluoroscopy confirmation of catheter position. This saved both time and fluoroscopy exposure. This is illustrated by a lower mean fluoroscopy time in our case series, compared to fluoroscopy times ranging 17–61 minutes in literature<sup>17–20</sup>. Furthermore, continuous dragging of the catheter with high power settings results in homogeneous WACA lines with increased lesion continuity. This is illustrated by the high first pass isolation rates observed in the current study. High first pass isolation rates prevent excessive time being spent to identify gaps in the line, which again contributes to procedural efficiency. The observed paroxysmal AF 6-month efficacy is comparable with literature<sup>20</sup>, which in our opinion is an affirmation of the quality of our ablation strategy. Inclusion numbers of patients with persistent AF were too small in the current study for fair conclusions. Future comparative studies are needed to clearly define the impact of our novel RMN guided PVI strategy on procedural and long-term outcomes, however, we believe this series of cases illustrates promising results.

### High power short duration

While conventional settings during RF ablation involve applying low power for long times, a new setting based on high power and short duration has recently been suggested as safer and more effective<sup>22–25</sup>. Overall, high-power short-duration lesions were significantly wider and of similar depth compared to standard settings<sup>22</sup>. These characteristics are most beneficial in PVI due to increased lesion-to-lesion uniformity and linear continuity, given the larger lesion diameter. The high power settings used in the current study contributed to efficient PVI and appeared to be safe, as we did not observe any adverse events. Whether high power settings result in improved long-term AF recurrence rates should be the focus of future research.

### Conclusion

A novel, minimally-invasive RMN guided PVI strategy yields high efficiency, with short procedure and fluoroscopy times, in addition to efficacious PVI.

### References

- Hindricks G, Potpara T, Dagres N, Arbelo E, Bax JJ, Blomström-Lundqvist C, et al. 2020 ESC Guidelines for the diagnosis and management of atrial fibrillation developed in collaboration with the European Association for Cardio-Thoracic Surgery (EACTS). *Eur Heart J*. 2021;42(5):373–498.
- Chugh SS, Havmoeller R, Narayanan K, Singh D, Rienstra M, Benjamin EJ, et al. Worldwide epidemiology of atrial fibrillation: a Global Burden of Disease 2010 Study. *Circulation*. 2014;129(8):837–47.
- Colilla S, Crow A, Petkun W, Singer DE, Simon T, Liu X. Estimates of current and future incidence and prevalence of atrial fibrillation in the U.S. adult population. *Am J Cardiol*. 2013;112(8):1142–7.
- Wijffels MC, Kirchhof CJ, Dorland R, Allesie MA. Atrial fibrillation begets atrial fibrillation. A study in awake chronically instrumented goats. *Circulation*. 1995;92(7):1954–68.
- Michaud GF, Stevenson WG. Atrial Fibrillation. *N Engl J Med*. 2021;384(4):353–61.
- Andrade JG, Wells GA, Deyell MW, Bennett M, Essebag V, Champagne J, et al. Cryoballoon or Drug Therapy for Initial Treatment of Atrial Fibrillation. *N Engl J Med*. 2021;384(4):305–15.
- Haissaguerre M, Jais P, Shah DC, Takahashi A, Hocini M, Quiniou G, et al. Spontaneous initiation of atrial fibrillation by ectopic beats originating in the pulmonary veins. *N Engl J Med*. 1998;339(10):659–66.
- Kuck KH, Brugada J, Furnkranz A, Metzner A, Ouyang F, Chun KR, et al. Cryoballoon or Radiofrequency Ablation for Paroxysmal Atrial Fibrillation. *N Engl J Med*. 2016;374(23):2235–45.
- Luik A, Radzewitz A, Kieser M, Walter M, Bramlage P, Hormann P, et al. Cryoballoon Versus Open Irrigated Radiofrequency Ablation in Patients With Paroxysmal Atrial Fibrillation: The Prospective, Randomized, Controlled, Noninferiority FreezeAF Study. *Circulation*. 2015;132(14):1311–9.
- Faddis MN, Blume W, Finney J, Hall A, Rauch J, Sell J, et al. Novel, magnetically guided catheter for endocardial mapping and radiofrequency catheter ablation. *Circulation*. 2002;106(23):2980–5.
- Bhaskaran A, Barry MA, Al Raisi SI, Chik W, Nguyen DT, Poulipoulos J, et al. Magnetic guidance versus manual control: comparison of radiofrequency lesion dimensions and evaluation of the effect of heart wall motion in a myocardial phantom. *J Interv Card Electrophysiol*. 2015;44(1):1–8.
- Pappone C, Vicedomini G, Frigoli E, Giannelli L, Ciaccio C, Baldi M, et al. Irrigated-tip magnetic catheter ablation of AF: a long-term prospective study in 130 patients. *Heart Rhythm*. 2011;8(1):8–15.
- Jin QI, Pehrson S, Jacobsen PK, Chen XU. Efficacy and Safety of Atrial Fibrillation Ablation Using Remote Magnetic Navigation: Experience from 1,006 Procedures. *J Cardiovasc Electrophysiol*. 2016;27 Suppl 1:S23–8.
- Blandino A, Bianchi F, Masi AS, Mazzanti A, D'Ascenzo F, Grossi S, et al. Outcomes of manual versus remote magnetic navigation for catheter ablation of ventricular tachycardia: a systematic review and updated meta-analysis. *Pacing Clin Electrophysiol*. 2021.
- Elisabeth Notén AM, Kis Z, Akca F, Bhagwandien R, Wijchers S, Yap SC, et al. Robotic navigation shows superior improvement in efficiency for atrial fibrillation ablation. *J Atr Fibrillation*. 2019;11(5):2108.
- Notén AME, Géczy T, Yap S-C, Kis Z, Szili-Torok T. Introducing a novel catheter-tissue contact feedback feature in robotic navigated catheter ablation: Utility, feasibility, and safety. *Heart Rhythm*. 2020;17(2):103–10.
- Chen CF, Gao XF, Duan X, Chen B, Liu XH, Xu YZ. Comparison of catheter ablation for paroxysmal atrial fibrillation between cryoballoon and radiofrequency: a meta-analysis. *J Interv Card Electrophysiol*. 2017;48(3):351–66.
- Buiatti A, von Olshausen G, Barthel P, Schneider S, Luik A, Kaess B, et al. Cryoballoon vs. radiofrequency ablation for paroxysmal atrial fibrillation: an updated meta-analysis of randomized and observational studies. *Europace*. 2017;19(3):378–84.
- Murray MI, Arnold A, Younis M, Varghese S, Zeiher AM. Cryoballoon versus radiofrequency ablation for paroxysmal atrial fibrillation: a meta-analysis of randomized controlled trials. *Clin Res Cardiol*. 2018;107(8):658–69.
- Chun KRJ, Okumura K, Scuzzuso F, Keun On Y, Kueffer FJ, Braegelmann KM, et al. Safety and efficacy of cryoballoon ablation for the treatment of paroxysmal and persistent AF in a real-world global setting: Results from the Cryo AF Global Registry. *J Arrhythm*. 2021;37(2):356–67.
- Jiang R, Chen M, Yang B, Liu Q, Zhang Z, Zhang F, et al. Intraprocedural endpoints to predict durable pulmonary vein isolation: a randomized trial of four post-ablation

- techniques. *Europace*. 2020;22(4):567-75.
22. Coderch-Navarro S, Berjano E, Camara O, González-Suárez A. High-power short-duration vs. standard radiofrequency cardiac ablation: comparative study based on an in-silico model. *Int J Hyperthermia*. 2021;38(1):582-92.
  23. Mulder BA, Luermans J, Hindricks G, Blaauw Y. Innovations and paradigm shifts in atrial fibrillation ablation. *Europace*. 2021;23(Supplement\_2):ii23-ii7.
  24. Winkle RA, Mead RH, Engel G, Kong MH, Salcedo J, Brodt CR, et al. High-power, short-duration atrial fibrillation ablations using contact force sensing catheters: Outcomes and predictors of success including posterior wall isolation. *Heart Rhythm*. 2020;17(8):1223-31.
  25. Sun X, Lu J, Lin J, Feng T, Suo N, Zheng L, et al. Efficiency, Safety, and Efficacy of High-Power Short-Duration Radiofrequency Ablation in Patients with Atrial Fibrillation. *Cardiol Res Pract*. 2021;2021:8821467.





## Robotic Ablation for Atrial Fibrillation: A High Volume Single Center Experience

Raffaele Corbisiero<sup>1</sup>, Adam Guss<sup>1</sup>

<sup>1</sup>Deborah Heart and Lung Center, Browns Mills, New Jersey, USA

### Abstract

Population based projections show that the prevalence of atrial fibrillation (AF) will continue to grow. Since 2017, the HRS consensus statement has ruled catheter ablation as a reasonable first line treatment for atrial fibrillation. As the popularity of catheter ablation continues to increase, several factors need to be considered to facilitate the growth in procedures. The number of electrophysiologists must increase or their productivity must be enhanced. If the former, additional hospital space will also be required. Enhancing productivity will require the continued efforts of both healthcare professionals and industry to bring new, more efficient techniques and products to the procedure room.

### Introduction

Population based projections show that the prevalence of atrial fibrillation (AF) will continue to grow<sup>1</sup>. Since 2017, the HRS consensus statement has ruled catheter ablation as a reasonable first line treatment for atrial fibrillation<sup>2</sup>. As the popularity of catheter ablation continues to increase, several factors need to be considered to facilitate the growth in procedures. The number of electrophysiologists must increase or their productivity must be enhanced. If the former, additional hospital space will also be required. Enhancing productivity will require the continued efforts of both healthcare professionals and industry to bring new, more efficient techniques and products to the procedure room.

More consideration will also need to be given to the human cost of such treatment. Cardiac ablation is physically demanding on the physician. While data specific to electrophysiologists is lacking, a meta-analysis has shown the rate of degenerative cervical spine disease and degenerative lumbar spine disease for surgeons and interventionalists has increased by 18.3% and 27% respectively from 1997 to 2015; pooling prevalence also estimate that between 35% and 60% of interventionalists report work related pain<sup>3</sup>. Additionally, the significant time investment in post graduate medical training limits appropriate expansion of the EP physician workforce in comparison to the current increase in procedural volume.

### Key Words

Robotic ablation, Atrial Fibrillation

### Corresponding Author

Raffaele Corbisiero  
Deborah Heart and Lung Center,  
Browns Mills, New Jersey, USA.

As demand for AF ablation increases, preserving proceduralist physical well-being while improving EP lab and AF ablation efficiency must remain a primary concern. Alongside physician wellness, reproducible and efficient procedural times will be critical for scheduling as the rate of required procedures per day is increased. Robotic Magnetic Navigation (RMN) is an emerging technology that can assist with both aspects. In this paper, we describe our acute RMN AF ablation workflow that produces procedure times that are comparable with the latest manual conventional navigation (MCN) AF ablation while the physician is seated safely outside the radiation field.

Treating 149 consecutive AF patients with RMN in our lab, we experienced the following acute outcomes: 100% acute PVI, zero adverse events, and average total procedure time of 61.4 minutes. This efficiency in RMN PVI procedures is previously unreported and shows the ability to combine the safety and fluoroscopy reduction of RMN with a high-volume complex ablation practice. Our intention in this reporting is to both present our experience as well as to provide practical advice to those considering RMN ablation techniques in a high volume setting, especially wherein procedural efficiency remains a primary limitation.

### RMN Early Experience

As is often the case with new technologies, the early focus of RMN was applied to understanding the strengths of the dramatically different approach of directly manipulating the catheter tip using magnetic fields. Several advantages were identified: improved safety profile, reduced fluoroscopy, enhanced catheter stability, and improved reach.

**Table 1: Comparison of procedure times for RMN and MCN AF ablation (2010-2017)**

Title	Author	RMT Procedure Time (Minutes)	MCN Procedure Time (Minutes)
Remote Magnetic Navigation With Irrigated Tip Catheter for Ablation of Paroxysmal Atrial Fibrillation	Miyazaki et al. 2010	246 ± 50	153 ± 51
Atrial Fibrillation Ablation Using Magnetic Navigation Comparison With Conventional Approach During Long Term Follow Up.	Aksu et al. 2015	286	228
Safety and Long-Term Outcomes of Catheter Ablation of Atrial Fibrillation Using Magnetic Navigation versus Manual Conventional Ablation: A Propensity Score Analysis	Adragao et al. 2016	213 ± 58	152 ± 52
Robotic magnetic navigation for ablation of human arrhythmias.	Da Costa et al 2016	213 ± 58	152 ± 52
Radiofrequency catheter ablation of atrial fibrillation: Electrical modification suggesting transmuralty is faster achieved with remote magnetic catheter in comparison with contact force use.	Bun et al 2017	224 ± 38	217 ± 36

Given the significance of these differences, it is understandable that the focus was not devoted to maximizing efficiency.

### Fluoroscopy and Safety

Robotic Magnetic Navigation (RMN) allows the physician to conduct the procedure without exposure to ionizing radiation from the relative safety of a control room and PC console. This significantly reduces or eliminates the requirement to wear lead after access and transseptal puncture. A recent meta-analysis of 14 papers, with a patient population of 3375 demonstrated RMN had fluoro times that were a mean of 18.01 minutes shorter than manual navigation<sup>4</sup>. The stability of RMN catheter tip to tissue contact and compliant nature are the most likely drivers in this reduction of fluoroscopy. The overall reduction in fluoroscopy is beneficial to the patient, support team, and physician.

Early studies identified the preferable safety profile of RMN relative to Manual Conventional Navigation (MCN)<sup>5</sup>. Overall complications – specifically pericardial effusion and tamponade – are higher in the MCN group most likely due to the stiffness of MCN catheters. It should be noted that vascular complication rates between RMN and MCN are similar<sup>4</sup>, but this is expected as venous vascular access is the same in both procedures.

### Stability v. Contact Force

A major factor to the long-term success of AF ablation is the catheter stability during ablation. Long term success rates of RMN and MCN – including those in direct comparison to contact force – have been demonstrated to be similar<sup>6,7</sup>. Head-to-head comparisons have examined differences in lesion characteristics between the two technologies and postulated how lesion quality and lesion size result in similar long-term efficacy.

In vitro studies have shown that robotic catheters are more stable on simulated wall motion relative to their MCN counterparts<sup>8</sup>. The

increase in stability allows for less dispersion of RF energy, leading to higher quality lesions.

Grossi et al further confirmed this by measuring signal fragmentation and shrinkage as markers of lesion quality, in these proxies RMN outperformed contact force sensing catheters. Lesion dimension was surrogated by signal energy attenuation and impedance drop, in these categories contact force outperformed RMN<sup>9</sup>. Ultimately, both achieved similar success rates, so lesion size and quality are synonymous in the context of creating contiguous transmural lesion sets.

### Procedure Time

The majority of early studies suggested the tradeoff to gain RMN benefits was longer overall procedure times compared to MCN<sup>10,11,12,13</sup>. In these earlier studies, Table 1 shows there are universally longer procedural times with RMN relative to MCN.

More recently, a greater focus has been placed on efficiency with the release of the third generation RMN system (Niobe ES) and development of a robust Best Practices program. These advances have driving reductions in procedure time to where they are comparable<sup>7,14,15</sup>. In a comparison of first to second generation modalities RMN achieved the greatest reduction in overall procedure time while maintaining the highest rate on first pass isolation<sup>15</sup>. Over the last 3 years, there has been a huge shift in terms of closing the gap in procedure time between RMN and MCN<sup>15</sup>. Until such a point, the greatest improvements in procedure time were observed with MCN – where current procedure times are published to be 71 ± 19 minutes<sup>16</sup>.

**Table 2: Advances in RMN technology and workflow enhances procedure times**

Title	Author	RMT Procedure Time (Minutes)	MCN Procedure Time (Minutes)	Other Comparisons Procedure Time (Minutes)
Remotely controlled steerable sheath improves result and procedural parameters of atrial fibrillation ablation with magnetic navigation.	Errahmouni et al. 2015	227 ± 36	Robotic Sheath	254 ± 62 Fixed Sheath
Significant reduction in procedure duration in remote magnetic-guided catheter ablation of atrial fibrillation using the third-generation magnetic navigation system.	Maurer et al. 2017	139.7 ± 22.6		263.9 ± 81.9
Robotic Navigation Shows Superior Improvement in Efficiency for Atrial Fibrillation Ablation.	Noten et al. 2019	113 ± 48.1	Niobe ES	153 ± 52.0 MCN 293 ± 65.1 Niobe II
Procedural outcomes and learning curve of cardiac arrhythmias catheter ablation using remote magnetic navigation: Experience from a large-scale single-center study.	Li et al. 2020	143.5 ± 41.5 (Average time of 502 AF ablations)		
Utilization of steerable sheath improves the efficacy of atrial fibrillation guided by robotic magnetic navigation compared with fixed-curve sheath.	Luo et al. 2022	111.9 ± 25.2	Fixed Sheath	90.4 ± 20.7 Deflectable Sheath

**Table 3: Table of RMN AF ablation procedure metrics at Deborah Heart & Lung Center in 2021**

Pre-Ablation time (minutes)	Ablation Time (minutes)	Procedure time (Minutes)	RF Time (Minutes)
15.0	46.4	61.4	24.6

Workflow considerations, such as use of steerable sheaths, are also driving procedural efficiencies. Using a steerable sheath presents a number of advantages in the setting of RMN AF ablation. With a fixed sheath, optimizing transseptal puncture location is critical to effectively ablate the RPVs, the criticality is diminished when a steerable sheath is used<sup>17</sup>. Implementing use of a steerable sheath reduced RF, mapping and ablation time<sup>17</sup>. Figure 2 demonstrates that advances in magnetic navigation technology and workflow best practices are closing the gap in procedure time between RMN and MCN AF ablation.

While currently published data studying the efficiency of RMT in PVI procedures shows a considerable improvement over time, these procedural times are still likely greater than what is necessary in a busy EP lab, and do not match our experience at Deborah Heart and Lung.

By following a set list of best practices specific to RMT technique, we've been able to achieve highly efficient and reproducible procedure times comparable to conventional techniques. Average acute procedural data for 149 consecutive AF patients treated at Deborah Heart and Lung in 2021 are listed in Figure 3. Data was collected retrospectively and these procedures represent all AF patients, including re-do or persistent patients with additional targeted ablation, specific to the needs of each patient, which may include roofline, posterior wall isolation, targeting of CFAE, and CTI flutter line. In addition to the procedure times reported below, we validated pulmonary vein isolation in 100% of patients and zero adverse events.

### Procedural Technique

Under ultrasound guidance three venous access sheaths were placed within the right common femoral vein. A steerable duodecapolar catheter was positioned in the right atrium and coronary sinus. A single transseptal puncture was performed using a standard fixed-curve sheath (Fast-Cath SL0, Abbott), under direct visualization of the intra-atrial septum using an ACUSON AcuNav Ultrasound Catheter to select a low and anterior position. Mapping of the left atrium was achieved using a 20-pole high-density mapping catheter (Pentaray, Biosense Webster Inc.), which was then switched for a 3.5mm tip irrigated magnetic catheter (NaviStar RMT Thermocool, Biosense Webster Inc.). The SL0 was positioned directed posteriorly, with 1cm of sheath in the left atrium. Circumferential wide-area isolation was achieved with RF applied in continuous fashion using 50W and 30ml/min irrigation, moving the catheter every 5-10 seconds on the posterior wall and 10-20 seconds anteriorly. Lesion assessment was achieved using Ablation History (Stereotaxis) and Visitags (Biosense Webster, Inc). Confirmed electrical isolation of each pulmonary vein was validated with the ablation catheter, with additional circumferential pacing to check for exit block. Physicians newer to the technology should consider utilizing a small-curl deflectable sheath, advanced to the LSPV and directed towards the right-sided veins to routinely

isolate the RSPV and RIPV. Additionally, the application of point-by-point lesions may help better assess each individual lesion while still in the learning curve at a small cost to efficiency. After confirmation of bi-directional block, the ablation catheter and sheath are removed from the left atrium under echocardiographic guidance, and catheters are withdrawn to the inferior vena cava. Protamine driven reversal of heparin is administered. Subsequent hemostasis of the groin access site with suture placement (purse string, or figure-of-eight), and manual hemostasis at the time of sheath removal is completed and patient is taken from the lab for further recovery.

### Conclusion


Our experience as a high volume ablation center shows procedural times with RMN can further be reliably improved and become competitive with manual catheter ablation. This increase in efficiency is required to allow further productivity in an era of first line ablation therapy. RMT additionally offers significant improvements in physician well being and reductions in fluoroscopy exposure that should extrapolate into longer physician career lengths. Ultimately, RMN provides a competitive toolset and ability to complete rapid and safe pulmonary vein isolation and left atrial ablations with an excellent safety profile, reduced radiation exposure for patient and physician, and reduced operator fatigue.

### References

- Colilla, Susan, Ann Crow, William Petkun, Daniel Singer, Teresa Simon, and Xianchen Liu. 2013. "Estimates of Current and Future Incidence and Prevalence of Atrial Fibrillation in the U.S. Adult Population." *The American Journal of Cardiology* 1142-1147.
- Calkins, Hugh, Gerhard Hindricks, Riccardo Cappato, Young Hoon Kim, Eduardo B Saad, Luis Aguinaga, Joseph G Akar, et al. 2017. "2017 HRS/EHRA/APHSR/SOLAECE expert consensus statement on catheter and surgical ablation of atrial fibrillation: executive summary." *Journal of Interventional Cardiac Electrophysiology* 1-55.
- Epstein, Sherise, Emily H Sparer, and Bao N Tran. 2018. "Prevalence of Work-Related Musculoskeletal Disorders Among Surgeons and Interventionalists: A Systematic Review and Meta-analysis." *JAMA Surgery*.
- Ghadban, Rugheed, Kristina Giff, Zachary Luebering, Sandeep Sodhi, Daniel Cooper, and Tariq Enezate. 2020. "Radiofrequency atrial fibrillation with irrigated tip catheter using remote magnetic navigation compared with conventional manual method." *Journal of Interventional Cardiac Electrophysiology* 95-102.
- Szili-Torok, Tamas, and Ferdi Akcaq. 2012. "Remote magnetic navigation in atrial fibrillation." *Expert Reviews Medical Devices* 249-255.
- Weiss, J Peter, Heidi T May, Tami L Bair, Brian G Crandall, Michael J Cutler, John D May, Jeffrey S Osborn, Charles Mallender, and T Jared Bunch. 2016. "A Comparison of Remote Magnetic Irrigated Tip Ablation versus Manual Catheter Irrigated Tip Catheter Ablation With and Without Force Sensing Feedback." *Journal of Cardiovascular Electrophysiology* S5-S19.
- Yuan, Shiwen, Fredrik Holqvist, Ole Kongstad, Steen M Jensen, Lingwei Wang, Erik Ljungstrom, Eva Hertervig, and Rasmus Borgquist. 2017. "Long-term outcomes of the current remote magnetic catheter navigation technique for ablation of atrial fibrillation." *Scandinavian Cardiovascular Journal* 308-315.
- Bhaskaran, Abhishek, Tony Barry, Sara I Al Raisi, William Chik, Doan Trang Nguyen, Jim Poulipoulos, Christian Nallian, et al. 2015. "Magnetic guidance versus manual control: comparison of lesion dimensions and evaluation of the effect of heart wall motion in a myocardial phantom." *Journal of Interventional Cardiac Electrophysiology*.

9. Grossi, Stefano, Francesco Grassi, Lorenzo Galleani, Francesca Bianchi, and Maria Rosa Conta. 2018. "A comparison of contact force and remote magnetic navigation on lesion formation for the ablation of atrial fibrillation." *Pacing and Clinical Electrophysiology* 450-458.
10. Aksu, Tolga, Serdar Bozyel, Ebru Golcuk, Kyvanc Yalin, and Tumer Erdem Guler. 2015. "Atrial Fibrillation Ablation Using Magnetic Navigation Comparison With Conventional Approach During Long Term Follow Up." *Journal of Atrial Fibrillation*.
11. Adragao, Pedro Pulido, Diogo Cavaco, Antonio Miguel Ferreira, Francisco Moscoso Costa, Leonor Parreira, Pedro Carmo, Francisco Bello Morgado, et al. 2016. "Safety and Long-Term Outcomes of Catheter Ablation of Atrial Fibrillation Using Magnetic Navigation versus Manual Conventional Ablation: A Propensity Score Analysis." *Journal of Cardiovascular Electrophysiology* S11-S16.
12. Da Costa, Antoine, Jean Baptiste Guichard, Cecile Romeyer-Bouchard, Antoine Gerbay, and Karl Isaaz. 2016. "Robotic magnetic navigation for ablation of human arrhythmias." *Medical Devices: Evidence and Research* 331-339.
13. Bun, Sok-Sithikun, Anas Ayari, Decebal Gabriel Latcu, Abdelkarim Errahmouni, and Nadir Saoudi. 2017. "Radiofrequency catheter ablation of atrial fibrillation: Electrical modification suggesting transmural ablation is faster achieved with remote magnetic catheter in comparison with contact force use." *Journal of Cardiovascular Electrophysiology* 1-9.
14. Maurer, Tilman, Christian Sohns, Sebastian Deiss, Laura Rottner, Peter Wohlmuth, Bruno Reissmann, Christian H Heeger, et al. 2017. "Significant reduction in procedure duration in remote magnetic-guided catheter ablation of atrial fibrillation using the third-generation magnetic navigation system." *Journal of Interventional Cardiac Electrophysiology* 219-226.
15. Noten, Anna Maria Elisabeth, Zsuzsanna Kis, Ferdi Akca, Rohit Bhagwandien, Wijchers, Sing Chien Yap, and Tamas Szili-Torok. 2019. "Robotic Navigation Shows Superior Improvement in Efficiency for Atrial Fibrillation Ablation." *Journal of Atrial Fibrillation*.
16. Mulder MJ, et al. "Ablation Index guided point-by-point ablation versus Grid annotation-guided dragging for pulmonary vein isolation: A randomized controlled trial" *J Cardiovasc Electrophysiol*. 2022 Jan; 33(1):64-72 doi: 10.1111/jce.15294. Epub 2021 Nov 24
17. Luo, Qingzi, Yun Xie, Yangyang Bao, Yue Wei, Changjian Lin, Ning Zhang, Tianyou Ling, et al. 2022. "Utilization of steerable sheath improves the efficacy of atrial fibrillation guided by robotic magnetic navigation compared with fixed-curve sheath." *Clinical Cardiology*.
18. AlTurki, Ahmed, and Ricardo Proietti. 2018. "Remote Magnetic Navigation versus Contact Force Technology." *Pacing and Clinical Electrophysiology: PACE* 447-449.
19. Ariyarantha, Nilshan, Saurabh Kumar, Stuart P Thomas, William G Stevenson, and Gregory F Michaud. 2018. "Role of Contact Force Sensing in Catheter Ablation of Cardiac Arrhythmias: Evolution or History Repeating Itself?" *Journal of the American College of Cardiology* 707-723.
20. Errahmouni, Abdelkarim, Decebal Gabriel Latcu, Sok-Sithikun Bun, Nicolas Rijo, Dugourd Celine, and Nadir Saoudi. 2015. "Remotely controlled steerable sheath improves result and procedural parameters of atrial fibrillation ablation with magnetic navigation." *Europace*.
21. Grossi, Stefano, Francesco Grassi, Lorenzo Galleani, Francesca Bianchi, and Maria Rosa Conta. 2018. "A comparison of contact force and remote magnetic navigation on lesion formation for the ablation of atrial fibrillation." *Pacing and Clinical Electrophysiology* 450-458.
22. Jia, Kangni, Qi Jin, Ao Liu, and Liqun Wu. 2019. "Remote magnetic navigation versus manual control navigation for atrial fibrillation ablation: A systemic review and meta-analysis." *Journal of Electrophysiology* 78-86.
23. Kataria, Vikas, Benjamin Berte, Yves Vandereckhove, Rene Tavernier, and Mattias Duystchaever. 2017. "Remote Magnetic versus Manual Navigation for Radiofrequency Ablation of Paroxysmal Atrial Fibrillation: Long-term, Controlled Data in a Large Cohort." *BioMed Research International*.
24. Kim, Michael H, Stephen S Johnston, Bong-Chul Chu, Mehul R Dalal, and Kathy L Schulman. 2011. "Estimation of Total Incremental Health Care Costs in Patients With Atrial Fibrillation in the United States." *Circulation: Cardiovascular Quality and Outcomes* 313-320.
25. Li, Xiang, Qi Jin, Ning Zhang, Tianyou Ling, Changjian Lin, Kangni Jia, Yangyang Bao, et al. 2020. "Procedural outcomes and learning curve of cardiac arrhythmias catheter ablation using remote magnetic navigation: Experience from a large-scale single-center study." *Clinical Cardiology*.
26. Shipeng Danh, Ru-Xing Wang, Christian Jons, Peter Karl Jacobsen, Steen Perhson and Xu Chen. 2022. "Comparison of the Anterior Septal Line and Mitral Isthmus Line for Perimitral Atrial Flutter Using Robotic Magnetic Navigation." *Journal of Interventional Cardiology*.





## The Impact of Adoption of Fluoroless Robotic Navigation Ablation for Atrial Fibrillation on Procedural Time

Pedram Kazemian<sup>1</sup>, Adam Guss<sup>1</sup>, Xu Lei<sup>1</sup>

<sup>1</sup>Deborah Heart and Lung Center, NJ, USA.

### Abstract

**Introduction:** Exposure to ionizing radiation occurs during most EP procedures and is associated with increased risk of cancers and orthopedic complications associated with wearing heavy protective apparel. The use of fluoroless ablation technique has been gaining popularity over the past decade and has been shown to be safe and efficient although the data has been limited to the manual catheter ablation. Fluoroless robotic navigation (RMN) ablation procedure for atrial fibrillation has not been described previously and the impact of its adoption on procedural time and safety is unknown.

**Material and Methods:** The impact of adoption of fluoroless AF ablation was studied in this single-operator time-series analysis. A total of 58 consecutive patients undergoing RMN AF ablation were included in this study and different components of the procedural duration were assessed before and after the introduction of fluoroless technique. A meta-analysis of previously published procedural times using manual fluoroless technique was performed and used for comparison.

**Results:** Upon introduction of fluoroless RMN ablation, there was an increase in the access and mapping time of the procedure by 16.9±4.3 min (P<0.001). However, this increase was counteracted by a reduction in the ablation time and as a result the total procedure time was not significantly impacted (increase of 5.2±15.7 min, P=0.7). The total procedure time was comparable to previously published data on fluoroless manual AF ablation. No major intra-procedural complications occurred.

**Conclusion:** Zero fluoroscopy using Remote Magnetic Navigation is safe and efficient. The total procedural time is not significantly impacted after adoption of fluoroless technique.

### Introduction

A significant number of patients and physicians are exposed to ionizing radiation. In 2014, close to 3.7 million cardiovascular procedures were performed on Medicare beneficiaries using ionizing radiation of which 250,000 were clinical electrophysiologic procedures.<sup>1</sup> Compared to early 1980s, in 2006, Americans were exposed to more than seven times as much ionizing radiation from medical procedures.<sup>2</sup> Although acute radiation toxicity is dose dependent and relatively rare, long-term stochastic radiation-induced damage to cellular DNA occurs frequently and may lead to increased risk of cancer in patients and staff. Stochastic effects are probabilistic in nature and do not require a definite dose threshold.<sup>1</sup> Furthermore, wearing the required heavy personal radiation protective apparel has been shown to be associated with multitudes of orthopedic injuries in operators and staff.<sup>3</sup> These

deleterious effects are more pronounced with longer procedures such as atrial fibrillation ablation.

Over the past decade, the advent and wider availability of intra-cardiac echocardiography as well as increased accuracy of mapping technologies have allowed for EP ablation procedures to achieve significant reduction in radiation exposure without prolonging procedural time or increasing complication rates.<sup>4</sup> Despite increasing popularity of fluoroless technique for manual AF ablation, to date there has been no published data regarding procedural feasibility of Robotic Magnetic Navigation (RMN)-guided AF ablation and its safety and efficacy. The aim of this paper is to describe the fluoroless RMN-guided AF procedure and provide data regarding its safety and efficacy.

### Material and Methods

#### 1- Effect on procedural time

The data from 33 consecutive atrial fibrillation ablation procedures prior and 25 after adoption of fluoroless technique from a single operator were included in the study. RMN catheter navigation was performed using the Stereotaxis Niobe<sup>®</sup> Robotic Magnetic Navigation

### Key Words

Robotic Navigation; Ablation; Atrial Fibrillation; Fluoroless

### Corresponding Author

Pedram Kazemian,  
Deborah Heart and Lung Center, NJ, USA,  
4 Oxford Court, Lawrenceville, NJ 08648 USA.

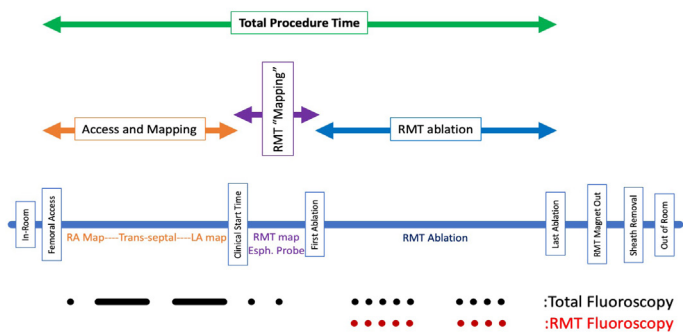


Figure 1:

**Components of the total procedure time. Procedural began with access and mapping period which included all the steps from obtaining femoral access and trans-septal puncture to left atrial mapping using a multipolar catheter. RMN mapping included additional mapping with RMN catheter and insertion of esophageal probe. RMN ablation time encompasses the radiofrequency ablation component of the procedure.**

system.<sup>5</sup> The total procedure time was divided into 3 major components: access and mapping, RMN mapping, and RMN ablation (Figure 1) and were individually measured for each procedure. Access and mapping time included all the steps from obtaining femoral access and trans-septal puncture to left atrial mapping using a multipolar catheter. RMN mapping included additional mapping with RMN catheter and insertion of esophageal probe. Finally, RMN ablation time was defined as the interval between the application of the first and last RF lesion.

In order to provide a point of comparison and reference for the procedural time of the fluoroless RMN AF ablation, a meta-analysis of published studies of fluoroless ablation was performed.

Fluoroless atrial fibrillation ablation procedure technique has not been previously described and involves 6 steps as described below.

## 2- Fluoroless RMN ablation technique

Fluoroless RMN-guided AF ablation as was performed in this study has not previously been described and involves 6 major steps:

1- Pre-procedural preparation: The use of Foley catheter and invasive arterial blood pressure monitoring was limited and used infrequently only in patients who had significant cardiovascular risk. Deep sedation with propofol administration, monitored by nurse anesthetists and anesthesiologists was utilized for the majority of procedures. In rare cases, general anesthesia was deemed preferable by anesthesiologists often due to patients' body habitus or suboptimal respiratory status. After induction of anesthesia, an esophageal temperature probe was placed in mid-esophageal region adjacent to the left atrial posterior wall in order to monitor changes of temperature during ablation. A quadripolar diagnostic catheter was placed in the lumen of the temperature probe and connected to the mapping system to allow for visualization and adjustment of the probe throughout the procedure without fluoroscopy (Appendix-Figure 1). Fluoroscopic registration of the RMN catheter is required by some robotic navigation systems and was achieved using a standard x-ray image (Appendix-Figure 2).

2- Vascular access and placement of catheters: After patient was prepped and draped in sterile fashion the right femoral region was

anesthetized and three venous accesses were obtained with ultrasound guidance. Heparin bolus and infusion was immediately started and titrated throughout the procedure to maintain an ACT of 350-400 seconds. Intracardiac Echo (ICE) catheter was advanced via a 9F short femoral sheath to the right atrium. Navigation of the ICE catheter without fluoroscopy requires careful tracking of the venous ultrasound contour and maneuvering (rotation and deflection) of the probe through venous branches (Video 1). A PENTARAY® catheter was subsequently advanced via the short 8F sheath to the right atrium if no resistance was felt. In rare situations, if there was difficulty in advancement of the mapping catheter, ICE probe was retracted from right atrium and used to guide maneuvering of the mapping catheter under direct visual ultrasound guidance (Video 1).

3- Right atrial mapping: With the aid of a multipolar catheter and under the guidance of ICE, a limited electroanatomic map of the right atrium including HIS bundle location, fossa ovalis, and coronary sinus (or CS ostium) was created (Video 2). A deflectable deca-polar catheter was advanced to the right atrium and placed in the previously mapped coronary sinus (Video 3). Mapping catheter was removed from the right atrium and a medium curve deflectable sheath was placed in the superior vena cava over a J wire and under ICE guidance.

4- Trans-septal access: ICE probe was deflected posteriorly and leftward to visualize superior vena cava and the deflectable sheath. A Brockenbrough™ (BK) curved needle was placed inside the deflectable catheter and advanced up to 1 inches from the proximal end of the sheath. Sheath and needle assembly were slowly pulled back under ultrasound guidance until tenting of the inter-atrial septum was visualized and BK needle was advanced completely. A SafeSept® Trans-septal Guidewire (135 cm, 0.014 inch) was used to cross the inter-atrial septum. The location of SafeSept® wire in the left upper or lower pulmonary vein was confirmed by ICE before advancing the sheath/needle assembly into the left atrium. Subsequently, dilator, needle and guide wire were removed and a multipolar mapping catheter (PENTARAY® NAV ECO) was advanced via the sheath to the left atrial cavity (Video 4).

5- Left atrial mapping: An electroanatomic map of the left atrium was created using either the multipolar mapping catheter or RMN ablation catheter. Location of each anatomic structure was confirmed with ICE image. After completion of mapping, multipolar catheter was replaced with RMN ablation catheter under ICE guidance. Deflectable sheath was retracted to the level of inter-atrial septum (Video 5).

6- Ablation: RMN irrigated ablation catheter was maneuvered around pulmonary vein ostia using Stereotaxis console. Ablation was performed while pacing at 15 mA, using 40-50 Watts of energy. Adequacy of tissue contact was confirmed by the following parameters: contact meter reading, ultrasound visualization, sharp EGM signal, and capture during pacing. If esophageal temperature increased by more than 1 degree centigrade, ablation was temporary halted to allow for tissue cooling to occur. Upon completion of pulmonary vein isolation, bidirectional block was confirmed using the multi-electrode mapping catheter (Video 5).



### 3- Statistical analysis

In order to compare the changes in procedural time before and after the introduction of fluoroless technique, an interrupted time series analysis was performed.<sup>6</sup> Since procedural time is affected by the operator experience and is expected to improve over time, the measurements are autocorrelated. Interrupted time series analysis controls for the auto-correlated changes and estimates the treatment effect over multiple periods.

Meta-analysis of published data on fluoroless atrial fibrillation ablation was conducted by searching PubMed, Embase, Web of Science, and Cochrane Database for articles describing procedural time in patients undergoing catheter ablation of AF using fluoroless technique from 2009–2020. The search was limited to randomized controlled trials, case–control studies, cohort studies, and case series. Citations were appraised by 2 independent reviewers (P.K., A.G.), with differences resolved by consensus. Selected publications were analyzed for the total procedure time. DerSimonian and Laird method was used for fitting the random effects model for pooled-parameter estimation. Meta-regression was performed to investigate the change in procedural time over time. Statistical analysis was performed using Stata software (Stata/IC 15.1 for Mac, StataCorp LLC), OpenMetaAnalyst, and R Programming Software (Version 1.2.1335).

## Results

### 1- Effect of fluoroless atrial fibrillation ablation on procedural time

Of the 58 consecutive patients included in the study, fluoroscopy was used in the first 33 (age  $66 \pm 12$  years, 44% male) and fluoroless method in the last 25 (age  $63 \pm 9$ , 51% male) ablations. Majority of ablations were performed in patients with paroxysmal atrial fibrillation (76.1%) and this ratio was not statistically different in pre- versus post-fluoroless groups ( $P=0.1$ ).

In the pre-fluoroless group, 80% of fluoroscopy occurred during non-RMN portions of the ablation (non-RMN fluoroscopy time  $6.3 \pm 2.8$  min vs RMN fluoroscopy time  $1.4 \pm 1.2$  min) and the average fluoroscopy and procedure times were  $7.7 \pm 3.7$  and  $130.5 \pm 32.2$  minutes, respectively. Immediately after adoption of fluoroless technique, the access and mapping time of the procedure increased initially by  $16.9 \pm 4.3$  min ( $P < 0.001$ ) but demonstrated a trend towards reduction over the ensuing 25 procedures (a reduction of 0.25 minutes for each additional procedure,  $P=0.3$ ) (Figure 2). This increase, however, was counterbalanced by a reduction in RMN ablation time of  $17.2 \pm 12.8$  minutes after fluoroless technique implementation ( $P=0.18$ ). As a result, fluoroless technique did not result in a statistically significant increase in the total procedure time ( $5.2 \pm 15.7$  min,  $P=0.7$ ) (Figure 3).

In the fluoroless period of the study, there were rare occasions when brief fluoroscopy was used (in one case, a very brief fluoroscopy was needed to achieve trans-septal access and on few occasions, to locate and repositions esophageal probe resulting in an average fluoroscopy time of  $8.4 \pm 23.4$  seconds) mostly for the repositioning of the esophageal probe or guidance for trans-septal puncture fluoroless group. Complete PV isolation was achieved in all patients.

No acute major intra-procedural complications occurred during the study including pericardial effusion, vascular access complications or cerebrovascular accidents.

### 2- Historical trends in procedural duration of manual fluoroless AF ablation

Search of databases identified 15 papers from 2009 to 2019 that were included in the meta-analysis.<sup>4, 7-20</sup> The weighted average of procedure time for the fluoroless manual ablation was 155.5 minutes (95% CI, 133.9-177.2). No published data was available on fluoroless ablation using RMN. There was a trend towards reduction of procedural duration over time from 208 minutes in 2009 to 108.6 minutes in 2019 (Figure 4).

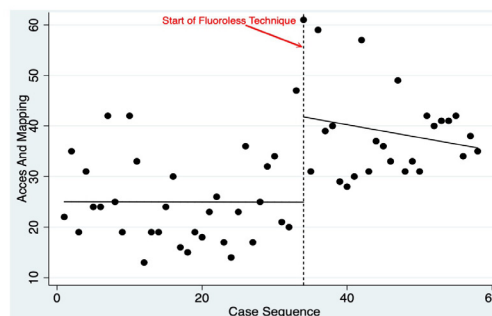
## Discussion

Despite rising popularity and more than a decade experience with fluoroless manual ablation, no published data is available specifically regarding the methodology of RMN fluoroless ablation and the impact of its adoption on procedural time.

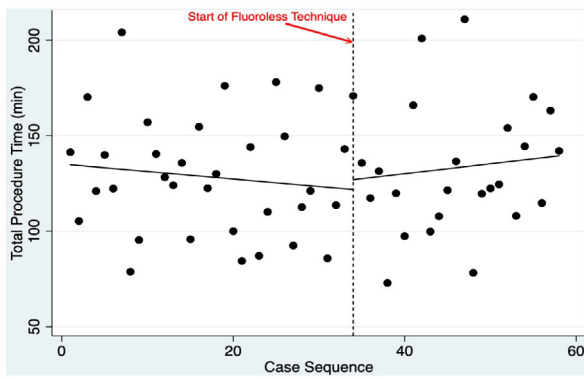
This paper for the first time outlines steps involved in fluoroless RMN atrial fibrillation ablation and many of the same fluoroless techniques can be used for other ablation procedures.

Adoption of fluoroless RMN-guided atrial fibrillation ablation results in an initial statistically insignificant prolongation of the total procedure time by 5 minutes ( $P=0.7$ ). However, there is a trend towards gradual reduction of the access and mapping time with subsequent procedures.

Similar to other procedures in electrophysiology, novel technologies are often initially associated with longer procedural time and possibly higher complication rates. However, the current study confirms that adoption of fluoroless technique using RMN is not only safe but also does not significantly prolong procedure time. Previous studies have demonstrated RMN-guided ablation to be associated with superior safety and efficiency. Virk et al in their meta-analysis of 15 published trials confirmed that AF ablation performed using RMN is associated with reduced peri-procedural complications and fluoroscopy exposure although it was associated with slightly longer procedural duration compared to manual ablation.<sup>21</sup>



**Figure 2:** Adoption of fluoroless technique results in an initial increase in “Access and Mapping” portion of the procedure ( $16.9 \pm 4.3$  min,  $P < 0.001$ ) with a trend in reduction in the ensuing procedures ( $-0.25$  min per case,  $P=0.3$ ).

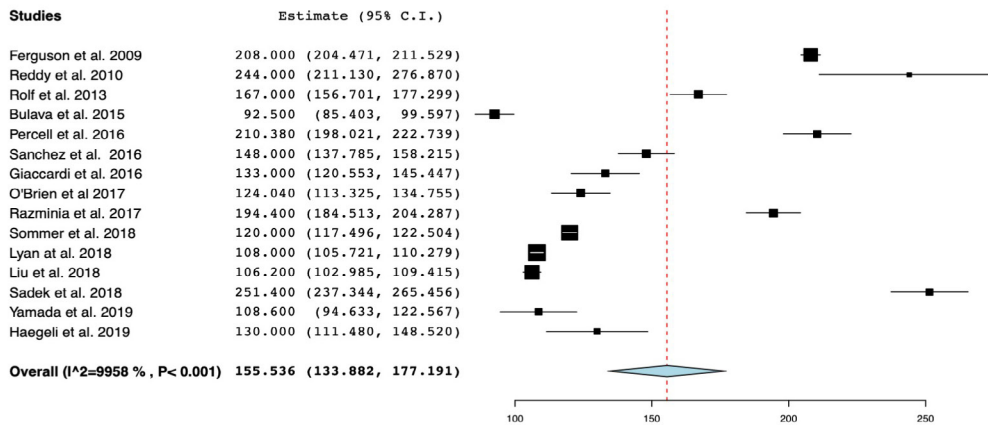


**Figure 3:** Adoption of fluoroless technique does not increase the total procedure time (5.2±15.7 min, P=0.7).

In order to provide a point of comparison, meta-analysis of published data on fluoroless manual AF ablation was performed. This clearly demonstrated that the total procedural time of fluoroless RMN-guided AF ablation (133.2 min) was indeed comparable to the reported published results for the fluoroless manual ablation (155.5 min).

This is a retrospective single-center, single-operator study which is one of its weaknesses. However, to address the issue of auto-correlation of data, which arises from this limitation, a time-series analysis was performed. Furthermore, the findings of this study favorably compares with other similar published studies of manual fluoroless AF ablation as demonstrated in the meta-analysis.

Due to the retrospective nature of the study, no follow-up data were available to compare the long-term clinical success in terms of freedom from recurrent atrial fibrillation in the fluoroless cohort compared to



**Figure 4:** Adoption of fluoroless technique does not increase the total procedure time (5.2±15.7 min, P=0.7).

the standard RMN ablation. Nonetheless, procedural PV isolation was achieved in all patients, which likely portends similar long-term clinical outcomes in both groups.

The findings, however, remain to be validated by a larger multi-center, multi-operator trial that also includes long-term clinical outcomes.

**Conclusion**

Zero Fluoroscopy using Remote Magnetic Navigation is safe and efficient. Procedure times are not significantly affected by adoption of fluoroless technique.

**Please Click below Links for Videos**


- Maneuvering of ICE to RA**
- Mapping RA 1**
- LA mapping and ablation**
- CS Positioning**
- Trans-septal access**

**Appendix - Content**

**References**

- Hirshfeld, J.W., Jr., et al., 2018 ACC/HRS/NASCI/SCAI/SCCT Expert Consensus Document on Optimal Use of Ionizing Radiation in Cardiovascular Imaging: Best Practices for Safety and Effectiveness: A Report of the American College of Cardiology Task Force on Expert Consensus Decision Pathways. *J Am Coll Cardiol*, 2018. 71(24): p. e283-e351.
- Schauer, D.A. and O.W. Linton, NCRP report No. 160, ionizing radiation exposure of the population of the United States, medical exposure—are we doing less with more, and is there a role for health physicists? *Health physics*, 2009. 97(1): p. 1-5.
- Goldstein, J.A., Orthopedic afflictions in the interventional laboratory: tales from the working wounded. *J Am Coll Cardiol*, 2015. 65(8): p. 827-829.
- Sadek, M.M., et al., Completely nonfluoroscopic catheter ablation of left atrial arrhythmias and ventricular tachycardia. *J Cardiovasc Electrophysiol*, 2019. 30(1): p. 78-88.
- Stereotaxis Niobe® Robotic Magnetic Navigation system. April 6, 2022; Available from: <https://www.stereotaxis.com/products/#!/niobe>.
- Schaffer, A.L., T.A. Dobbins, and S.A. Pearson, Interrupted time series analysis using

- autoregressive integrated moving average (ARIMA) models: a guide for evaluating large-scale health interventions. *BMC Med Res Methodol*, 2021. 21(1): p. 58.
7. Yamada, S., et al., The Accuracy and Clinical Applicability of a Sensor Based Electromagnetic Non-fluoroscopic Catheter Tracking System. *Korean Circ J*, 2019. 49(1): p. 84-96.
  8. Haegeli, L.M., et al., Feasibility of zero or near zero fluoroscopy during catheter ablation procedures. *Cardiol J*, 2019. 26(3): p. 226-232.
  9. Sommer, P., et al., Safety profile of near-zero fluoroscopy atrial fibrillation ablation with non-fluoroscopic catheter visualization: experience from 1000 consecutive procedures. *Europace*, 2018. 20(12): p. 1952-1958.
  10. Lyan, E., et al., Nonfluoroscopic catheter ablation of paroxysmal atrial fibrillation. *Pacing Clin Electrophysiol*, 2018. 41(6): p. 611-619.
  11. Liu, X. and J. Palmer, Outcomes of 200 consecutive, fluoroless atrial fibrillation ablations using a new technique. *Pacing Clin Electrophysiol*, 2018. 41(11): p. 1404-1411.
  12. Razminia, M., et al., Fluoroless Catheter Ablation of Cardiac Arrhythmias: A 5-Year Experience. *Pacing Clin Electrophysiol*, 2017. 40(4): p. 425-433.
  13. O'Brien, B., et al., Fluoroscopy-free AF ablation using transesophageal echocardiography and electroanatomical mapping technology. *J Interv Card Electrophysiol*, 2017. 50(3): p. 235-244.
  14. Sanchez, J.M., et al., Fluoroless catheter ablation in adults: a single center experience. *J Interv Card Electrophysiol*, 2016. 45(2): p. 199-207.
  15. Percell, J., E. Sharpe, and R. Percell, SANS FLUORO (SAy No Series to FLUOROscopy): A First-Year Experience. *Journal of Innovations in Cardiac Rhythm Management*, 2016. 7(11): p. 2529-2534.
  16. Giaccardi, M., et al., Near-zero x-ray in arrhythmia ablation using a 3-dimensional electroanatomic mapping system: A multicenter experience. *Heart Rhythm*, 2016. 13(1): p. 150-6.
  17. Bulava, A., J. Hanis, and M. Eisenberger, Catheter Ablation of Atrial Fibrillation Using Zero-Fluoroscopy Technique: A Randomized Trial. *Pacing Clin Electrophysiol*, 2015. 38(7): p. 797-806.
  18. Rolf, S., et al., Catheter ablation of atrial fibrillation supported by novel nonfluoroscopic 4D navigation technology. *Heart Rhythm*, 2013. 10(9): p. 1293-300.
  19. Reddy, V.Y., et al., Catheter ablation of atrial fibrillation without the use of fluoroscopy. *Heart Rhythm*, 2010. 7(11): p. 1644-53.
  20. Ferguson, J.D., et al., Catheter ablation of atrial fibrillation without fluoroscopy using intracardiac echocardiography and electroanatomic mapping. *Circ Arrhythm Electrophysiol*, 2009. 2(6): p. 611-9.
  21. Virk, S.A. and S. Kumar, Remote Magnetic Versus Manual Catheter Navigation for Atrial Fibrillation Ablation: A Meta-Analysis. *Circ Arrhythm Electrophysiol*, 2019. 12(10): p. e007517..



### A Review on the use of Remote Magnetic Navigation for Ventricular Tachycardia Ablation

Adnan Ahmed<sup>1</sup>, Rishi Charate<sup>1</sup>, Naga Venkata K Pothineni<sup>1</sup>, Domenico G. Della Rocca<sup>2</sup>, Arshad Muhammad Iqbal<sup>3</sup>, David Burkhardt<sup>2</sup>, Luigi Di Biase<sup>4</sup>, Amin Al-Ahmad<sup>2</sup>, Rakesh Gopinathbainnair<sup>1</sup>, Andrea Natale<sup>2</sup>, Dhanunjaya Lakkireddy<sup>1</sup>

<sup>1</sup> Kansas City Heart Rhythm Institute, Overland Park, Kansas, USA

<sup>2</sup> Texas Cardiac Arrhythmia Institute, Austin, Texas, USA

<sup>3</sup> Department of Cardiovascular Medicine, University of Missouri, Columbia, Missouri, USA

<sup>4</sup> Montefiore Medical Center, Bronx, New York, USA

#### Abstract

Ventricular tachycardia (VT) is a life-threatening arrhythmia associated with sudden cardiac death (SCD). Antiarrhythmic drugs (AADs) are used frequently but their long-term efficacy is often limited by the adverse effect profile. With improved understanding of the pathophysiology of ventricular arrhythmias and significant technological advances in mapping and ablation techniques, catheter ablation is now a commonly performed procedure. Due to operator dependence, prolonged radiation exposure and procedure complications in manual navigation (MAN), remote magnetic navigation (RMN) evolved to become a valuable tool for VT ablation. In the last two decades, RMN use gained popularity, as its acute procedural success, complication rates and procedural times have shown superiority over MAN. The added benefit of decreased fluoroscopy exposure for physician and patients makes it a valuable approach in long VT ablations, since RMN eliminates operator fatigue, optimizes catheter contact on ablation site and improves maneuverability in complex anatomy. The learning curve for operators and the costs for its set up in centers remain a matter of debate. In this review, we discussed about the clinical experience using remote magnetic navigation in contemporary VT ablation.

#### Introduction

Ventricular tachycardia (VTs) is often a life-threatening arrhythmia associated with sudden cardiac death (SCD). Almost 80% of patients with VTs have underlying ischemic heart disease. The incidence of VTs and SCD is estimated to be 5.6%, claiming 350,000 to 400,000 lives annually in the United States alone<sup>1</sup>. Although implantable cardioverter defibrillators (ICD) improve survival outcomes by detecting and interrupting life-threatening ventricular arrhythmias, they do not prevent their onset. VTs recurrence and multiple ICD therapies are related to increase morbidity and mortality. Antiarrhythmic drugs (AADs) are used frequently for the treatment of VTs but have a narrow therapeutic index, and are limited by their adverse effect profiles<sup>2</sup>.

#### Key Words

Stereotaxis, VT Ablation, RMN-Catheter Ablation, Manual Navigation (MAN)

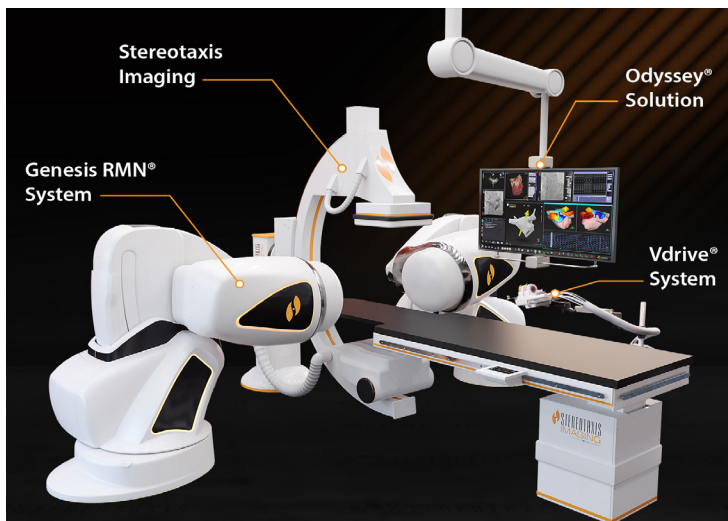#### Corresponding Author

Dhanunjaya Lakkireddy, MD, FACC, FHRS  
Executive Medical Director  
The Kansas City Heart Rhythm Institute (KCHRI) @ HCA MidWest,  
Professor of Medicine, the University of Missouri - Columbia

Over the years, a better understanding of the pathophysiology of ventricular arrhythmias and significant advances in percutaneous approaches, catheter ablation has become the standard of care for patients with drug refractory ventricular arrhythmias. Catheter ablation of ventricular arrhythmias is a complex procedure. It is important to obtain accurate mapping, which can often be difficult to achieve due to variable anatomy of the heart or any underlying structural heart disease<sup>3</sup>. Also, the success rate is significantly linked to operator experience and catheter handling abilities. Catheter stability and maneuverability are important determinants of success for VTs ablation.

Procedures are often long and expose the patient and operator to prolonged radiation exposure with significant orthopedic and ergonomic stress impacting their physical health. One study reported that 49% of cardiologists working in cath labs have suffered from one or more orthopedic injury as a direct result of their work<sup>4</sup>. Also 50% of cardiologists and 41% of cath nurses have been noted to have significant subcapsular lens changes impacting their vision<sup>5</sup>. Another study reported 85% of interventional physicians with brain tumors were located on the left side of the brain, which typically faces the x ray source<sup>6</sup>.





**Figure 1:** The remote magnetic navigation system.

In the last two decades, remote magnetic navigation (RMN) has evolved as a promising technology to overcome some of the limitations of manual navigation (MAN). RMN offers decreased radiation exposure, greater catheter stability, increased precision, and better clinical outcomes with lower periprocedural complications<sup>7</sup>. In this review we aimed at providing an overview of RMN and discussing its impact on procedural outcomes and overall safety.

### Remote magnetic navigation system

Robotic magnetic navigation (RMN) was first introduced and commercialized by Stereotaxis (Niobe<sup>®</sup>) in 2003. The system consists of two robotically controlled magnets next to the fluoroscopy table (Figure 1). They create a uniform magnetic field (0.08-0.1T) of approximately 20 cm diameter inside the chest of the patient. The direction of the magnetic field can be changed by tilting, rotating, and moving the magnets, thereby allowing the movements of the magnetically enabled mapping/ablation catheter in different planes<sup>8</sup>. The operator interfaces with the system via the Navigant<sup>™</sup> Navigation Workstation software (Stereotaxis, Inc., St. Louis, MO, USA) using a mouse, keyboard, joystick, and the ODYSSEY<sup>®</sup> viewing screen. The system is fully integrated with both fluoroscopy and electro-anatomical mapping systems (CARTO RMT, Biosense Webster, Inc., Diamond Bar, CA, USA). The operator is seated in the control room as compared to standing next to the patient, which allows for lesser operator fatigue and radiation exposure (Figure 2). This provides a significant ergonomic advantage in long VTs ablations.<sup>9,10</sup>

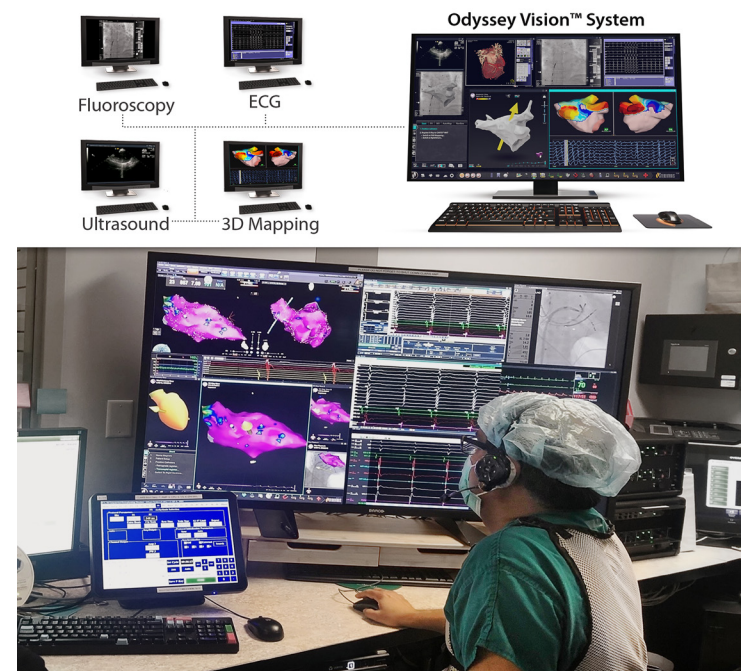
The magnetic catheter contains a permanent magnet in the tip and is highly flexible. The magnetic field helps the catheter align itself with the direction of the external magnets. Maximal force is exerted when the catheter is perpendicular to the magnetic field and minimal when parallel to the magnetic field. This gives the magnetic catheter advantages over conventional catheters regarding maneuverability and lower incidence of complications (Figures 3 & 4) (Videos 1 & 2). With real-time three-dimensional mapping during the procedure, the change in magnetic vector allows micro movements in increments of 1 mm to 9 mm<sup>8,11</sup>.

During the procedure, catheter is controlled by a bedside robotic navigation system (Figure 5) that receives signal inputs from the operator in the control room. The operator can steer the catheter to the intra-cardiac area of interest based on multiple inputs, visual feedback from fluoroscopic images, 3D electro-anatomic maps and ICE images.

### Clinical Experience with use of remote magnetic navigation systems in VTs

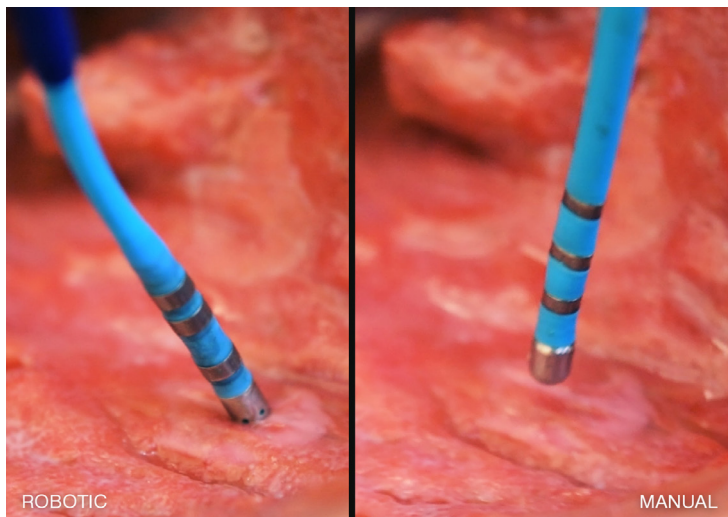
VTs ablation requires accurate mapping and advanced operator skills to manipulate the catheter through complex ventricular anatomy. Poor catheter tissue contact during ablation can lead to poor outcomes. Catheter manipulation with stiff catheters comes at the risk of complications like cardiac perforation or tamponade. RMN and contact force catheters (CFS) came with the promise to improve these outcomes. In the section below we discuss in detail procedural outcomes with the use of RMN for VT ablation.

The earliest RMN experience was reported by Thornton et al regarding mapping and ablating VTs originating from the RVOT. RMN use allowed for successful navigation at selected points of the RVOT. Median procedure time was 144 minutes and acute success was reported in all patients with shorter fluoroscopy times<sup>13</sup>. A large case series evaluating 110 patients with ventricular arrhythmias originating from the left ventricle (LV) reported 100% acute success rate with use of 3.5 mm magnetic open irrigated catheters. Only 14% of patients required cross over to manual ablation. RMN group had a significantly higher number of mapping points both endocardially and epicardially with longer procedural (3.3 ± 1.1 hours vs 2.9 ± 1.2 hours) and radiofrequency delivery times (33 ± 18 minutes vs 24 ± 12 minutes) in comparison to MAN<sup>14</sup>.



**Figure 2:** The navigation workstation

(a) Describes the different possible inputs to of the Odyssey navigation system. (b) The operator sits in the control room and maneuvers the catheter to intra-cardiac area of interest based on multiple inputs, visual feedback from fluoroscopic images, 3D electro-anatomic maps and ICE images.



**Figure 3:** Stable contact force during the beating heart

Further study by Dinov et al reported comparable acute and long-term success between MAN and RMN with no difference in total procedural times ( $156.85 \pm 40.26$  minutes vs  $148.44 \pm 49.56$  minutes,  $P = 0.42$ ). However, RF time was shorter with RMN. The overall complication rate was 2.94% which was comparable to previous studies and only one death was reported in the MAN group<sup>15</sup>. One study on the efficacy of RMN in cases of repeat catheter ablation also reported similar acute success and recurrence when compared to MAN. There was no difference for the median number of RF applications, total RF application time, and procedure time. RMN remained associated with decreased fluoroscopy times ( $22.8 \pm 14.7$  vs.  $41.2 \pm 10.8$  min,  $P=0.011$ )<sup>16</sup>.

Efficacy of RMN has also shown promise in treatment of electrical storm with severe ischemic heart disease. A total of 40 patients were included with a total of 84 VTs induced in the entire patient population (mean number  $2.1 \pm 1$  VTs per patient). VTs was successfully ablated in 95% of the patients during the first ablation. Two patients still had VTs, but their electrical storm was controlled with a combination of ablation and medication. No cross over to MAN was reported in the study. The total procedure and fluoroscopy times were  $105 \pm 27$  min and  $7.5 \pm 4.8$  min, respectively. The duration of total RF ablation time was  $16.5 \pm 8.8$  min. No major complications, including cardiac tamponade, thromboembolic events or major bleeding were observed; one patient did require replacement of atrial lead in the ICD<sup>17</sup>.

Qian et al were the first to report that RMN-guided VTs ablation was associated with overall higher procedural success (80% vs 60%;  $p=0.01$ ). They further reported better clinical outcomes in terms of survival and overall lower recurrence of arrhythmia in subgroup of ischemic cardiomyopathy. They observed that longer procedural time was attributed to multiple inducible VTs morphologies, indicating that longer ablation and procedural time was related to more VTs circuits<sup>18</sup>.

An earlier pooled analysis of<sup>7</sup> studies that included 779 patients


(RMN = 433 & MAN = 339) reported higher acute procedural success (OR 2.13 95% CI 1.40–3.23,  $p = 0.0004$ ) in RMN. However no significant differences were noted in SHD (OR 0.61, 95% CI 0.34–1.1,  $p = 0.1$ ) when compared to MAN. They also reported that use of RMN led to reduced fluoroscopy time and mean procedure duration by 10.42 and 9.79 minutes respectively. Significant reduction in complication rates up to 65% (OR 0.35, 95% CI 0.17–0.74,  $p = 0.0006$ ) was also seen in RMN group.

RMN use was also associated with 39% lower risk of VT recurrence with trends favoring even in the SHD group with no differences between RMN and MAN was noted in idiopathic VTs cases<sup>7</sup>.

A recent updated pooled meta-analysis of 13 studies by Blandino et al included 1348 patients and reported higher success rates for nonstructural heart disease compared to those with structural heart disease group. This was likely attributed to the small number of patients (267/1348) in the structural heart disease group<sup>19</sup>. They further noted no significant difference in long term follow up in terms of VTs recurrence, which is different than described by Turagam et al earlier.<sup>7</sup> Pooled analysis by Guandalini et al also did not observe any difference in procedure times ( $186 \pm 83$  mins in RMN vs  $186 \pm 49$  mins in MAN group). The mean RF time was  $17 \pm 15$  mins with RMN offering reduced RF time only in non-structural heart disease patients. Mean fluoroscopy time was  $29 \pm 14$  mins ( $22 \pm 9$  mins in RMN vs  $37 \pm 14$  mins in MAN), offering reduced fluoroscopy time of about ~40% in the total study population.<sup>19</sup>

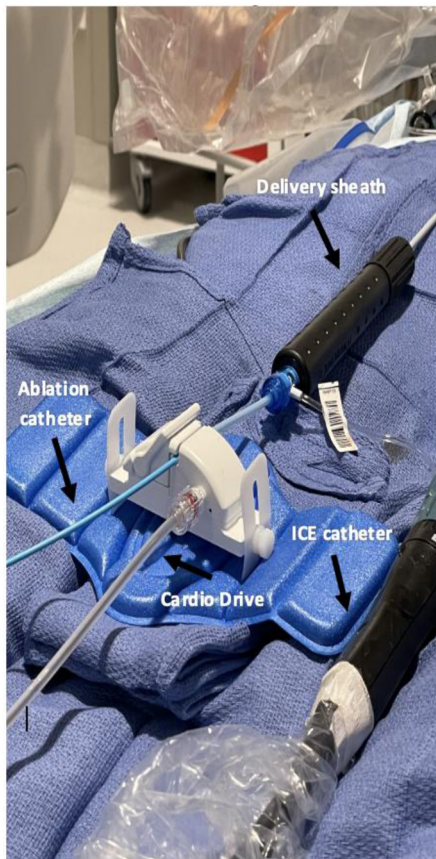
RMN guided procedures were associated with significantly lower major complications (cardiac perforation, major bleeding, permanent AV block and mortality): 6/638 (0.9%) vs 25/590 (4.2%). Similar favorable outcomes were noted for minor complications between RMN vs MAN (5.6% vs 12.4%).<sup>14,19,20</sup>

Figure 6 summarizes the efficacy and safety outcomes from prior systemic review and meta-analysis<sup>7,19</sup>. RMN utilization offers better acute success, lower fluoroscopy times and lower risk of major complications including cardiac perforation and mortality. However procedural time and VTs recurrence has varied among studies, and



**Figure 4:** Comparing flexibility of the RMN to rigid manual catheters





**Figure 5: Bedside robotic navigation system**

this could be a result of a learning curve with utilization of RMN in comparison to MAN.

MAGNETIC VTs, a prospective, randomized, single blind, post market study comparing RMN to MAN ablation outcomes for guided substrate mapping in low LVEF population is currently underway and will provide further outcome data<sup>21</sup>.

### Use of Remote Magnetic Navigation in Non-Ischemic Cardiomyopathy and Epicardial VT ablation

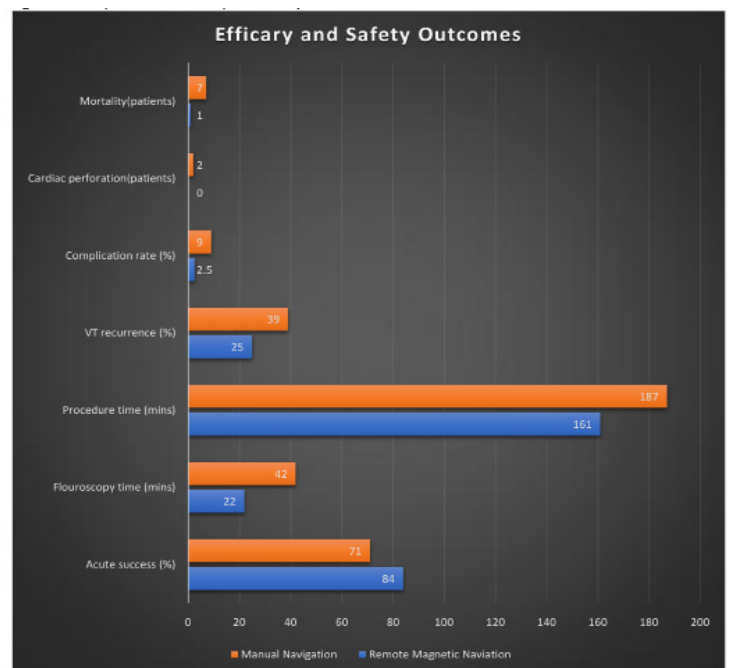
Non-ischemic cardiomyopathy (NICM), an umbrella term which includes dilated cardiomyopathy (DCM), hypertrophic cardiomyopathy (HCM) restrictive cardiomyopathy, arrhythmogenic right ventricular (ARVC) and left ventricular noncompaction (LVNC) cardiomyopathies<sup>22</sup> often times presents with ventricular arrhythmias that are difficult to ablate as they may be arising from both endocardial and epicardial substrates. Sosa et al highlighted that epicardial mapping alone will not lead to successful endocardial ablation and prompted for epicardial ablation<sup>23</sup>. Prevalence of epicardial VTs ranges from 14%-33% in patients with history of myocardial infarction<sup>24</sup>. Overall prevalence of epicardial VTs in patients with NICM seems to be higher, as they typically have re-entry circuits located over the basal lateral LV near the mitral or aortic valves. Hence, identifying low voltage wide fractionated EGMs can identify targets for epicardial ablation<sup>25</sup>. The success rate of catheter ablation is also lower in NICM and is reported to be only 38-67% vs 56-77% in ICM population<sup>26</sup>.

ARVC is a genetic condition that causes replacement of myocytes with fibrofatty tissue in the RV especially in the epicardial surface<sup>27</sup>. So, endocardial only ablation will only lead to suboptimal outcomes with acute success ranging from 43% to 73% in one study<sup>28</sup>. However, in a case series of 13 patients where endo-epicardial mapping and ablation was performed in population where endocardial only ablation had previously failed led to no recurrent VTs in 77% of the patients at 18 month follow up<sup>29</sup>.

Efficacy of endo-epicardial approach is seen in cases of viral drug refractory myocarditis as 30% of patients did not respond to endocardial ablation only<sup>30</sup>. Similarly, a systemic review demonstrated that 18% of patients required epicardial ablation following endocardial ablation in cardiac sarcoidosis. As the scar can be multifocal in sarcoidosis the average number of VTs was 4 and freedom from recurrence is approximately 50% with 25% of patients requiring repeat ablation procedures<sup>31,32</sup>.

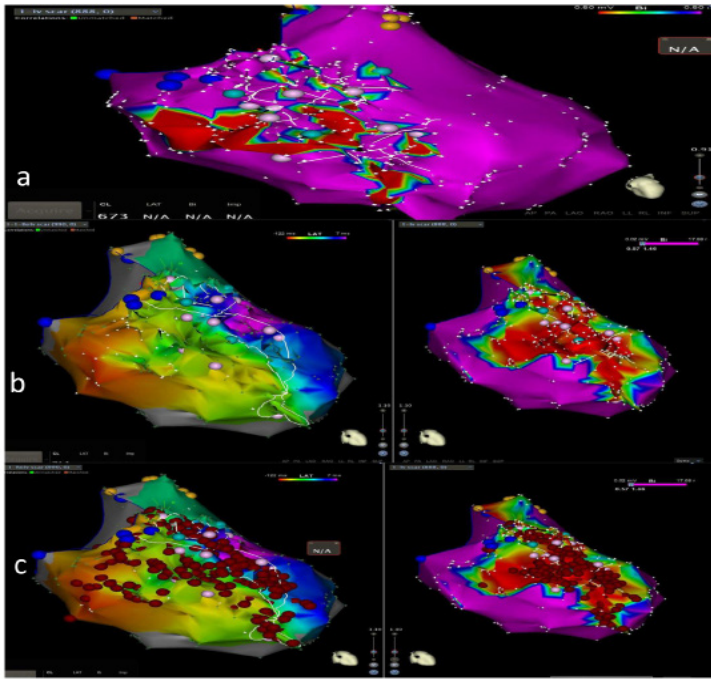
Aryana et al in their early experience with non-ischemic scar VTs demonstrated safety and efficacy of endocardial and epicardial substrate mapping in a variety of cardiac pathologies like DCM, ARVC, HCM and sarcoidosis with good success. Utilization of MAN in such scenarios are often limited by operator skill and catheter manipulation. So, utilization of RMN allows for accurate mapping and ablation that is independent of operator skill. The study population included ARVC (13%), DCM (13%), sarcoidosis (4%) and prior myocardial infarction (62%) substrates for VTs.

They further commented that use of RMN provided all the necessary tools for a successful substrate mapping and ablation, like identifying the diseased myocardium and the arrhythmogenic areas within the scar



**Figure 6: Comparison of efficacy and safety outcomes**

This bar diagram is a representation of efficacy outcomes between remote magnetic navigation and manual navigation.



**Figure 7:** Bipolar EAM of a dense LV Scar

(a) Bipolar EAM showing dense scar at the inferior wall of LV. (b) Left panel is LAT of scar at the LV whereas right panel shows voltage map of the scar. (c) Left panel, red dots represent ablation points and scar optimization is seen in the right panel.

and delivering RF energy to terminate the induced VTs<sup>33</sup>.

A recent study by Guckel et al reported a 82% success rate with an overall recurrence of 39%. Although there were no differences in early outcomes, VTs recurrences rates were higher in NICM<sup>34</sup>. The earlier HELP-VTs study has reported a higher VTs recurrence rate of 40.5% in NICM vs 57% in ICM population, supporting the hypothesis of atypical scar formation in NICM<sup>35</sup>. On the contrary one small single center study reported better acute success and long-term survival with MAN in cases of NICM as compared to RMN<sup>36</sup>.

### Use of Remote Magnetic Navigation System in Brugada Syndrome

Ventricular arrhythmias are common in Brugada syndrome and ICD implantation remains the standard of care for preventing life threatening arrhythmias. But frequent ICD shocks can be challenging for patients and treating electrophysiologists. Newer evidence suggests that anterior right ventricular outflow tract (RVOT) epicardium is the arrhythmogenic substrate<sup>37</sup> as older studies have revealed low efficacy of endocardial mapping for Brugada substrates, which are characterized by low voltage fractionated late potentials. A study by Nademanee et al reported that most patients with Brugada have a large epicardial VF substrate without reciprocal abnormal endocardial sites<sup>38</sup>. Ablation of RVOT and anterior inferior right ventricle utilizing RMN has shown promising results in case reports with an overall lower complication rate and lower procedural and fluoroscopic times<sup>39</sup>.

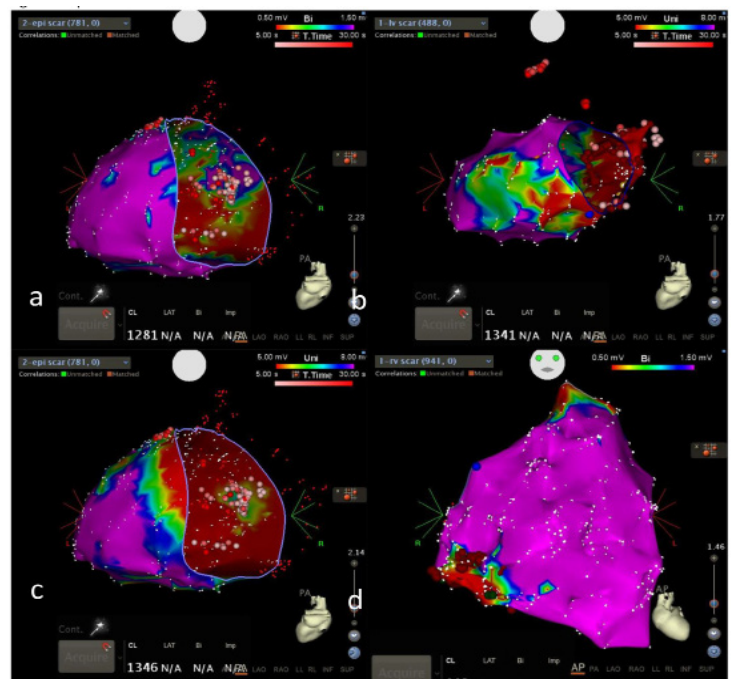
### Use of Remote Magnetic Navigation in Papillary muscle VTs

Ventricular arrhythmias arising from the LV and RV papillary

muscles can be challenging to map and ablate due to complex anatomy. They are also associated with lower success rate in comparison to ablation performed on arrhythmias arising from fascicular and idiopathic outflow tract. Catheter stability and mapping multiple arrhythmic exit sites after initial ablation are the most important factors that determine the outcome of the procedure. Basil et al were the first to report a large case series of 35 patients comparing procedural outcomes with use of RMN vs MAN in ventricular arrhythmias arising from papillary muscles. They reported similar acute success rates between RMN and MAN groups (74% vs 73%;  $P=1$ ), with 2 patients in RMN required cross over to MAN after failure to abolish the clinical papillary ventricular arrhythmia. Median fluoroscopy times were significantly lower in RMN (7.3 mins) vs MAN (23 mins). However, retrograde transaortic access to target ventricular arrhythmias was higher in MAN as compared to RMN (46 vs. 4%, respectively;  $P = 0.005$ ). The study reported a decrease in PVC burden from 16% to 3.6% at median follow up of 81 days<sup>40</sup>. A study by Li et al reported 88% acute success rate with RMN in ventricular arrhythmias originating from LV posterior papillary muscles. However, arrhythmias originating from these structures required longer procedural time when compared to arrhythmias originating from posterior mitral annulus and left ventricular fascicle<sup>41</sup>. Larger prospective studies are needed to determine long-term efficacy of utilizing RMN in ventricular arrhythmias originating from papillary muscles.

### Specific clinical scenarios

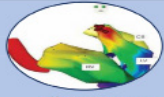


While manual navigation using a steerable catheter is routinely performed, specific anatomical constraints limit the operator's ability to maneuver the catheter in the ventricles. Examples of these



**Figure 8:** Epicardial EAM of LV and RV.

(a) Epicardial voltage map with extensive right ventricular scar tissue with some basal left ventricular scarring. (b) Endocardial map showing basal scar with lateral wall as well as the left ventricular outflow tract scar tissue. (c) Epicardial map showing scar along the right ventricle and base of the right ventricular outflow tract mixed tissue which was the area of reentry. This area was successfully updated with radio-frequency ablation. (d) Epicardial map of a patient who had a reentrant tachycardia from the antero-lateral base of the right ventricular epicardium near the tricuspid valve.



	 Efficacy, Catheter maneuverability & Outcomes	 Remote Magnetic Navigation (RMN)	 Manual Navigation (MAN)
Acute Success	++++	++++	++
Precision and Mapping	++++	++++	++
Navigation	++++	++++	++
Flexibility	++++	++++	+
Stability	++++	++++	++
Challenging anatomy	++++	++++	+
Tissue contact force	++++	++++	+++
Lesion time	++	++	++
Fluoroscopy time	+	+	++++
Ergonomic comfort	++++	++++	+

**Figure 9:** Central Illustration comparing efficacy and outcomes between RMN and MAN

complex anatomical locations include crevices in the right ventricle, navigating intracavitary structures such as the RV moderator band and the papillary muscles. The enhanced freedom of movement with the magnetic ablation catheter can enable more acute turns and reach areas of the heart that are very difficult to access manually. The magnetically steered catheter is not stiff; on one hand, it can prolapse on itself in different orientations enhancing safety of catheter movement; and at the same time, it remains in a fixed position when not manipulated providing stability in high flow motion in the ventricular system. This can be extremely helpful in patients with adult congenital heart disease who often have very complex anatomical limitations to catheter ablation. Figure 7 shows endocardial substrate modification of a dense LV inferior wall scar while figure 8 shows voltage maps of ventricles with scar modification. Use of RMN in these cases allowed for a more detailed substrate mapping and better scar homogenization.

### No interaction with cardiac implantable devices

After the release of remote magnetic navigation, there were theoretical concerns with its use in patients with ICDs, pacemakers and other cardiac implantable devices. There was concern of short-term asynchronous pacing and likely needing reprogramming of these devices based on magnetic field interference. However real world experiences report no short or long-term complications<sup>42</sup>.

### Advantages of remote magnetic navigation

- Higher acute success rate as compared to MAN.
- RMN offers 1mm/1° precision and allows navigation from the catheter tip rather than the shaft.
- It provides better exploration and navigation of the anatomic structures that are often unreachable.
- The RMN catheters have more flexible shafts and do not require pull-wires in comparison to traditional catheters which are rigid as they are designed to translate hand movements from the handle to the tip.
- Catheters are controlled remotely, which can help avoid operator fatigue during these time-consuming ablation procedures.
- It provides effective catheter-tissue contact force as compared to manual catheters.
- Operator sits in the control room unscrubbed reducing fluoroscopy

exposure and time in lead, avoiding cumulative impact of daily radiation exposure.

### Limitations of remote magnetic navigation

- Requires a learning curve
- Installation cost and creating a set up
- Delay in incorporation of newer catheters

### Conclusion

RMN use provides better procedural outcomes and lower complication rates. Although learning curve and installation cost in centers remain a matter of debate, RMN should certainly be advocated for prolonged VTs ablations and in cases of complex anatomy where manual catheter ablation may increase the risk of complications. A case based approach is highly recommended.

### References

1. Go AS, Mozaffarian D, Roger VL, et al. Heart disease and stroke statistics--2014 update: a report from the American Heart Association. *Circulation* 2014;129(3):e28-e292 doi: 10.1161/01.cir.0000441139.02102.80.
2. Lo R, Chia KK, Hsia HH. Ventricular Tachycardia in Ischemic Heart Disease. *Card Electrophysiol Clin* 2017;9(1):25-46 doi: 10.1016/j.ccep.2016.10.013.
3. Guandalini GS, Liang JJ, Marchlinski FE. Ventricular Tachycardia Ablation: Past, Present, and Future Perspectives. *JACC Clin Electrophysiol* 2019;5(12):1363-83 doi: 10.1016/j.jacep.2019.09.015.
4. Klein LW TY, Garratt KN, Powell W, Lopez-Cruz G, Chambers C, et al. Occupational health hazards of interventional cardiologists in the current decade: Results of the 2014 SCAI membership survey. *Catheter Cardiovasc Interv*. 2015;86(5):913-24.
5. Vano E LN, Duran A, Romano-Miller M, Rehani MM. Radiation-associated lens opacities in catheterization personnel: results of a survey and direct assessments. *J Vasc Interv Radiol*. 2013;24(2):197-204.
6. Roguin A GJ, Bar O, Goldstein JA. Brain and neck tumors among physicians performing interventional procedures. *Am J Cardiol*. 2013;111(9):1368-72.
7. Turagam MK, Atkins D, Tung R, et al. A meta-analysis of manual versus remote magnetic navigation for ventricular tachycardia ablation. *J Interv Card Electrophysiol* 2017;49(3):227-35 doi: 10.1007/s10840-017-0257-3.
8. Ernst S, Ouyang F, Linder C, et al. Initial experience with remote catheter ablation using a novel magnetic navigation system: magnetic remote catheter ablation. *Circulation* 2004;109(12):1472-5 doi: 10.1161/01.CIR.0000125126.83579.1B.
9. Faddis MN, Chen J, Osborn J, Talcott M, Cain ME, Lindsay BD. Magnetic guidance system for cardiac electrophysiology: a prospective trial of safety and efficacy in humans. *J Am Coll Cardiol* 2003;42(11):1952-8 doi: 10.1016/j.jacc.2003.07.023.
10. Pappone C, Vicedomini G, Manguso F, et al. Robotic magnetic navigation for atrial fibrillation ablation. *J Am Coll Cardiol* 2006;47(7):1390-400 doi: 10.1016/j.jacc.2005.11.058.
11. Faddis MN, Blume W, Finney J, et al. Novel, magnetically guided catheter for endocardial mapping and radiofrequency catheter ablation. *Circulation* 2002;106(23):2980-5 doi: 10.1161/01.cir.0000038704.84304.6f.
12. Aagaard P NA, Di Biase L. Robotic navigation for catheter ablation: benefits and challenges. *Expert Rev Med Devices*. 2015;12(4):457-469. doi:10.1586/17434440.2015.1052406. Robotic navigation for catheter ablation: benefits and challenges. 2015
13. Thornton AS, Jordaens LJ. Remote magnetic navigation for mapping and ablating right ventricular outflow tract tachycardia. *Heart Rhythm* 2006;3(6):691-6 doi: 10.1016/j.hrthm.2006.01.028.
14. Di Biase L, Santangeli P, Astudillo V, et al. Endo-epicardial ablation of ventricular arrhythmias in the left ventricle with the Remote Magnetic Navigation System and

- the 3.5-mm open irrigated magnetic catheter: results from a large single-center case-control series. *Heart Rhythm* 2010;7(8):1029-35 doi: 10.1016/j.hrthm.2010.04.036.
15. Dinov B, Schonbauer R, Wojdyla-Hordynska A, et al. Long-term efficacy of single procedure remote magnetic catheter navigation for ablation of ischemic ventricular tachycardia: a retrospective study. *J Cardiovasc Electrophysiol* 2012;23(5):499-505 doi: 10.1111/j.1540-8167.2011.02243.x.
  16. Akca F, Theuns DA, Abkenari LD, de Groot NM, Jordaens L, Szili-Torok T. Outcomes of repeat catheter ablation using magnetic navigation or conventional ablation. *Europace* 2013;15(10):1426-31 doi: 10.1093/europace/eut051.
  17. Jin Q, Jacobsen PK, Pehrson S, Chen X. Acute and long term outcomes of catheter ablation using remote magnetic navigation for the treatment of electrical storm in patients with severe ischemic heart failure. *Int J Cardiol* 2015;183:11-6 doi: 10.1016/j.ijcard.2015.01.066.
  18. Qian P, De Silva K, Kumar S, et al. Early and long-term outcomes after manual and remote magnetic navigation-guided catheter ablation for ventricular tachycardia. *Europace* 2018;20(suppl\_2):ii11-ii21 doi: 10.1093/europace/euy057.
  19. Blandino A, Bianchi F, Sibona Masi A, et al. Outcomes of manual versus remote magnetic navigation for catheter ablation of ventricular tachycardia: a systematic review and updated meta-analysis. *Pacing Clin Electrophysiol* 2021;44(6):1102-14 doi: 10.1111/pace.14231.
  20. Wazni OM, Barrett C, Martin DO, et al. Experience with the Hansen robotic system for atrial fibrillation ablation--lessons learned and techniques modified: Hansen in the real world. *J Cardiovasc Electrophysiol* 2009;20(11):1193-6 doi: 10.1111/j.1540-8167.2009.01539.x.
  21. Di Biase L, Tung R, Szili-Torok T, et al. MAGNETIC VTs study: a prospective, multicenter, post-market randomized controlled trial comparing VTs ablation outcomes using remote magnetic navigation-guided substrate mapping and ablation versus manual approach in a low LVEF population. *J Interv Card Electrophysiol* 2017;48(3):237-45 doi: 10.1007/s10840-016-0217-3.
  22. Zeppenfeld K. Ventricular Tachycardia Ablation in Nonischemic Cardiomyopathy. *JACC Clin Electrophysiol* 2018;4(9):1123-40 doi: 10.1016/j.jacep.2018.06.014.
  23. Sosa E SM, d'Avila A, Pilleggi F. A new technique to perform epicardial mapping in the electrophysiology laboratory. *J Cardiovasc Electrophysiol*. 1996;7(6):531-536. doi:10.1111/j.1540-8167.1996.tb00559.x.
  24. Tung RMY, Yu R, et al. Epicardial ablation of ventricular tachycardia: an institutional experience of safety and efficacy. *Heart Rhythm*. 2013;10(4):490-498. doi:10.1016/j.hrthm.2012.12.013.
  25. Cardoso R, Aryana A, Singh SM, Tandri H, d'Avila A. Epicardial Ablation of Ventricular Tachycardia: a Review. *Korean Circ J* 2018;48(9):778-91 doi: 10.4070/kcj.2018.0210.
  26. Cronin EM, Bogun FM, Maury P, et al. 2019 HRS/EHRA/APHRS/LAHR expert consensus statement on catheter ablation of ventricular arrhythmias. *Heart Rhythm* 2020;17(1):e2-e154 doi: 10.1016/j.hrthm.2019.03.002.
  27. Basso C TG, Corrado D, Angelini A, Nava A, Valente M. Arrhythmogenic right ventricular cardiomyopathy. Dysplasia, dystrophy, or myocarditis?. *Circulation*. 1996;94(5):983-991. doi:10.1161/01.cir.94.5.983.
  28. Wichter T PT, Eckardt L, et al. Arrhythmogenic right ventricular cardiomyopathy. Antiarrhythmic drugs, catheter ablation, or ICD?. *Herz*. 2005;30(2):91-101. doi:10.1007/s00059-005-2677-6.
  29. Garcia FC BV, Zado ES, Ren JF, Marchlinski FE. Epicardial substrate and outcome with epicardial ablation of ventricular tachycardia in arrhythmogenic right ventricular cardiomyopathy/dysplasia [published correction appears in *Circulation*. 2010 Jun 1;121(21):e424]. *Circulation*. 2009;120(5):366-375. doi:10.1161/CIRCULATIONAHA.108.834903.
  30. Dello Russo A CM, Pieroni M, et al. Drug-refractory ventricular tachycardias after myocarditis: endocardial and epicardial radiofrequency catheter ablation. *Circ Arrhythm Electrophysiol*. 2012;5(3):492-498. doi:10.1161/CIRCEP.111.965012.
  31. Koplan BA SK, Baughman K, Epstein LM, Stevenson WG. Refractory ventricular tachycardia secondary to cardiac sarcoid: electrophysiologic characteristics, mapping, and ablation. *Heart Rhythm*. 2006;3(8):924-929. doi:10.1016/j.hrthm.2006.03.031.
  32. Papageorgiou N PR, Bronis K, et al. Catheter ablation for ventricular tachycardia in patients with cardiac sarcoidosis: a systematic review. *Europace*. 2018;20(4):682-691. doi:10.1093/europace/eux077.
  33. Aryana A, d'Avila A, Heist EK, et al. Remote magnetic navigation to guide endocardial and epicardial catheter mapping of scar-related ventricular tachycardia. *Circulation* 2007;115(10):1191-200 doi: 10.1161/circulationaha.106.672162.
  34. Guckel D, Niemann S, Ditzhaus M, et al. Long-Term Efficacy and Impact on Mortality of Remote Magnetic Navigation Guided Catheter Ablation of Ventricular Arrhythmias. *J Clin Med* 2021;10(20) doi: 10.3390/jcm10204695.
  35. Dinov B, Fiedler L, Schönbauer R, et al. Outcomes in catheter ablation of ventricular tachycardia in dilated nonischemic cardiomyopathy compared with ischemic cardiomyopathy: results from the Prospective Heart Centre of Leipzig VTs (HELP-VTs) Study. *Circulation* 2014;129(7):728-36 doi: 10.1161/circulationaha.113.003063.
  36. Bennett RG, Campbell T, Sood A, et al. Remote magnetic navigation compared to contemporary manual techniques for the catheter ablation of ventricular arrhythmias in structural heart disease. *Heliyon* 2021;7(12):e08538 doi: 10.1016/j.heliyon.2021.e08538.
  37. Nademanee K, Raju H, de Noronha SV, et al. Fibrosis, Connexin-43, and Conduction Abnormalities in the Brugada Syndrome. *J Am Coll Cardiol* 2015;66(18):1976-86 doi: 10.1016/j.jacc.2015.08.862.
  38. Nademanee K, Haissaguerre M. Endocardial Ablation Approach for Brugada Syndrome: An Important First Step or a Quixotic Quest. *Circ Arrhythm Electrophysiol* 2018;11(8):e006675 doi: 10.1161/CIRCEP.118.006675.
  39. Lim PCY, Nademanee K, Lee ECY, Teo WS. Epicardial ablation utilizing remote magnetic navigation in a patient with Brugada syndrome and inferior early repolarization. *Pacing Clin Electrophysiol* 2018;41(2):214-17 doi: 10.1111/pace.13175.
  40. Bassil G, Liu CF, Markowitz SM, et al. Comparison of robotic magnetic navigation-guided and manual catheter ablation of ventricular arrhythmias arising from the papillary muscles. *Europace* 2018;20(suppl\_2):ii5-ii10 doi: 10.1093/europace/eux374.
  41. Li X, Shang W, Zhang N, et al. Remote magnetic-guided ablation for three origins of idiopathic ventricular arrhythmias with right bundle branch block and superior axis. *Clin Cardiol* 2021;44(3):379-85 doi: 10.1002/clc.23546.
  42. Lüthje L, Vollmann D, Seegers J, Sohns C, Hasenfuss G, Zabel M. Interference of remote magnetic catheter navigation and ablation with implanted devices for pacing and defibrillation. *Europace* 2010;12(11):1574-80 doi: 10.1093/europace/euq300.





## **Coronary Ostia Mapping with Remote Magnetic Navigation can Facilitate Safe Mapping and Ablation of Outflow Tract Ventricular Arrhythmias**

*William Reichert<sup>1</sup>, Emrie Tomaiko-Clark<sup>1</sup>, Wilber Su<sup>1</sup>, Michael S. Zawaneh<sup>1</sup>, Roderick Tung<sup>1</sup>, J.Peter Weiss<sup>2</sup>*

<sup>1</sup>Banner University Medical Center, Phoenix, AZ, USA

<sup>2</sup>Director of Ventricular Arrhythmia Management and Robotics Banner University of Arizona Medical Center, Phoenix, AZ, USA

### **Abstract**

Remote Magnetic Navigation (RMN) is a well-described technology with which a flexible catheter is guided through vascular and cardiac structures by a directional magnetic field. When utilized with EAM, the technology allows for atraumatic and precise creation of real-time anatomical representation as well as stable positioning of the ablation catheter tip at the time of energy delivery. The present report describes an alternative method utilizing RMN during 3D Electroanatomic mapping to safely provide real-time visualization of SOV anatomy, including the coronary ostia, in patients undergoing mapping and ablation for idiopathic VAs.

### **Introduction**

The occurrence of both sustained and non-sustained ventricular arrhythmias (VAs) in patients without structurally normal hearts as well as nonischemic cardiomyopathy has been described since the mid-20th century and is thought to account for approximately 10% of VAs overall.<sup>1,2</sup> Such patients are commonly referred for catheter ablation. The majority demonstrate an inferior QRS-axis morphology and originate from the outflow tracts (OT) and adjacent regions of the ventricles, commonly described as right ventricular (RVOT), left ventricular (LVOT), left ventricular summit, and aortic sinuses of Valsalva (SOV).<sup>3</sup> Approximately 17% of these VAs are thought to originate from sites responsive to ablation from the SOV.<sup>4</sup> The involved structures reside in a relatively compact region with complex three-dimensional anatomical relationships that must be clearly understood in order to facilitate safe and effective mapping and ablation.<sup>5,6,7</sup>

Remote Magnetic Navigation (RMN) is a well-described technology with which a flexible catheter is guided through vascular and cardiac structures by a directional magnetic field allowing for atraumatic and precise creation of real-time anatomical representation as well as stable

positioning of the ablation catheter tip at the time of energy delivery. The present report describes a novel method utilizing RMN during 3D electroanatomic mapping to safely provide real-time visualization of SOV anatomy, including the coronary ostia, in patients undergoing mapping and ablation for ventricular arrhythmias of outflow tract origin.

### **Methods**

We performed a retrospective chart review on all patients who underwent catheter ablation for ventricular arrhythmias using RMN (GENESIS, Stereotaxis, Inc. St. Louis, MO) at a single center (Banner University of Arizona Medical Center, Phoenix, AZ, USA) between September 2020 and May 2021. Of these, 14 were identified who underwent ablation of idiopathic VA requiring mapping of the SOV utilizing RMN. The primary endpoints were successful mapping of the intended anatomy and rate of complications related to said mapping including ST/T-wave changes or any signs/symptoms of coronary injury. Success of the ablation in eliminating the clinical arrhythmia was evaluated as a secondary endpoint. Acute procedural success of ablation was defined as lack of inducible clinical arrhythmia following a minimum 30-minute waiting period including testing with isoproterenol infusion. Post discharge procedural success and complications were evaluated at follow-up within two weeks of the procedure as well as longer term follow-up as available. Baseline characteristics, medical history, procedural parameters, and follow-up were reviewed. Values are presented as mean +/- SD. All patients signed consent for electrophysiology study and ablation. The retrospective review did not require IRB approval.

### **Key Words**

Ventricular Arrhythmias; Mapping; Remote Magnetic Navigation; Ablation

### **Corresponding Author**

J Peter Weiss, MD, FACC, FHRS  
Director of Cardiac Interventions Center,  
Banner University Medical Center, Phoenix.

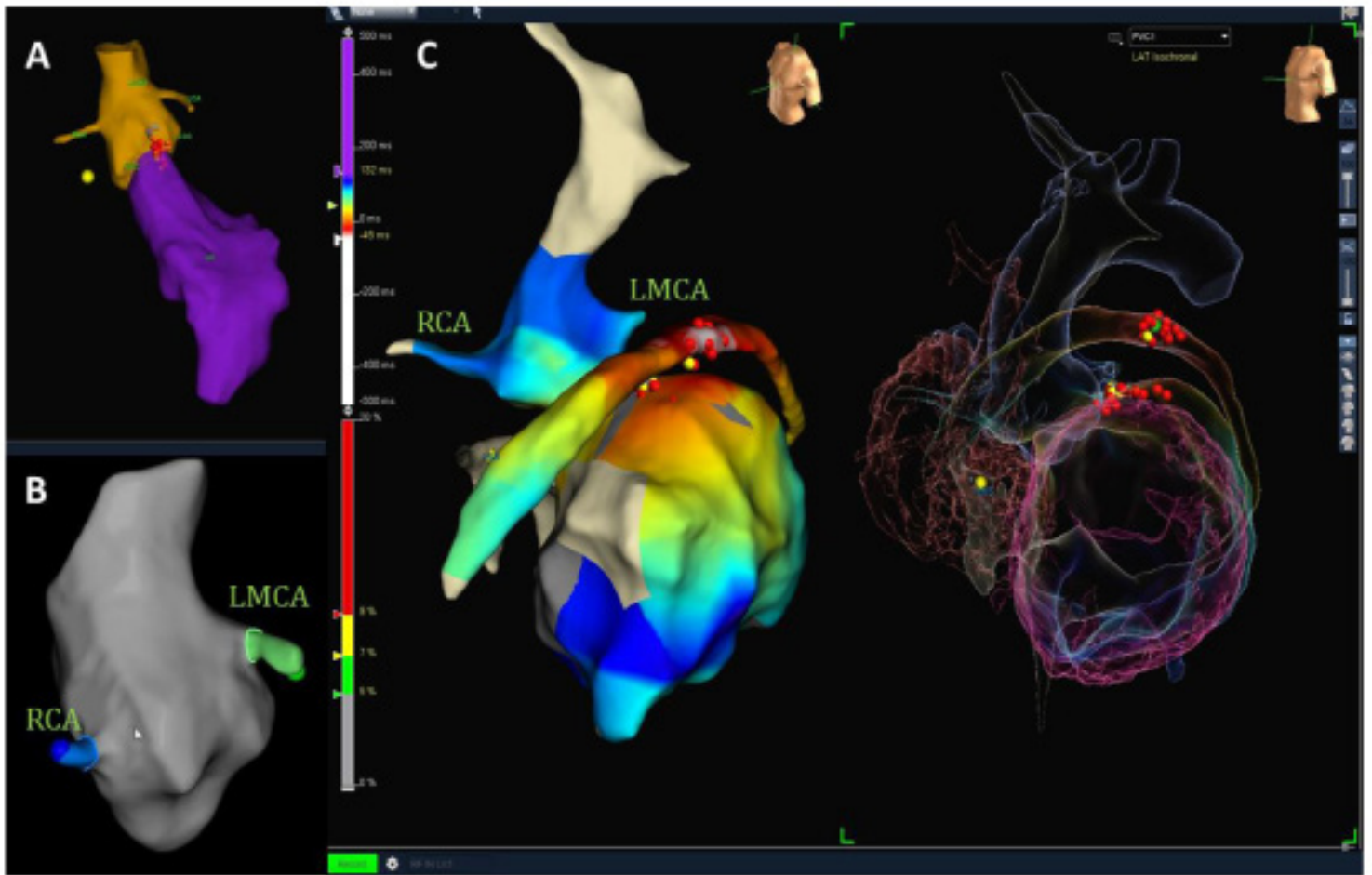


Figure 1:

Representative electroanatomic maps displaying integrated mapping of the coronary ostia and proximal coronary arteries as created with the remote magnetic navigation catheter. Panels A and B created with the CARTO mapping system. Panel C created with the EnSite Precision mapping system with CT image integration displayed alongside.

### Mapping of the Aortic Root and Coronary Ostia

Femoral arterial access was obtained under direct ultrasound guidance with Seldinger technique. Heparin was administered immediately following femoral access with activated clotting time target of 300-350 seconds while sheaths and catheters remained in the arterial circulation. After femoral angiography through the initial short access sheath, an 8.5F, 81cm, 135-degree LAMP sheath (Abbott Laboratories, Abbott Park, IL) was advanced to the ascending aorta. The RMN mapping and ablation catheter (Navistar Thermocool RMT, Biosense Webster, Diamond Bar, CA) was then advanced into the aortic root manually and connected to the Catheter Advancement System (CAS, Stereotaxis, Inc. St. Louis, MO) and brought under control of the magnetic navigation system. Per usual protocol, heparinized saline was continuously infused through the catheter at 2ml/min during mapping. Three-dimensional electroanatomic mapping was performed with either CARTO (CARTO3 v6 RMT, Biosense Webster, Diamond Bar, CA) or EnSite Precision (Abbott Laboratories, Abbott Park, IL) systems.

Mapping was initiated with navigation inferiorly towards the aortic valve and then omni-directionally in order to create 3D anatomy

of the entire aortic root. Particular attention was paid to obtaining complete anatomical detail of each SOV. Catheter tip contact was confirmed by restriction of movement with further advancement, a vector-based contact indicator, and often with visualization on intracardiac echocardiography. Cannulation of the coronary ostia was at times achieved spontaneously during mapping of the aortic root. When this did not occur, the coronary ostia were cannulated beginning with the catheter tip in the corresponding aortic cusp. The magnetic vector was then directed somewhat superior and towards the presumed location of the corresponding coronary ostium. The catheter was then withdrawn with 2mm movements. If the coronary ostium was not engaged, the movements were repeated with slightly altered vector orientation. Once the coronary ostium was engaged, the catheter would commonly advance into the proximal vessel of its own accord. Catheter advancement within the vessel was made with 2mm increments as permitted by anatomy. The catheter was then withdrawn as anatomical points were added to the map. This was performed efficiently with a goal of having the catheter within the coronary vessel for no longer than 30 seconds. The map was then edited to remove interpolated space and clearly define the coronary ostium and proximal vessel.

### Ablation

Ablation was performed using the same RMN catheter as used for

mapping with energy ranging from 20-50 watts for 30-120 seconds depending on location, local impedance, and response to initial ablation. Ablation within the SOV was typically performed at 35-45 watts no closer than 5mm to the coronary ostia as visualized on the 3D map.

## Results

Fourteen patients (average age 57.71 years, 71% male) who underwent mapping and ablation of inferior axis VAs were included in the case series. The majority were referred for management of PVCs compared with VT (86% vs. 14%). Seven (50%) had normal left ventricular function, and seven (50%) had nonischemic cardiomyopathy (ejection fraction 34.8% +/- 8%). One patient had repaired congenital tetralogy of Fallot. One patient was post TAVR. Procedure and fluoroscopy times were 194 +/- 66 min and 3.5 +/- 2.5 minutes respectively.

With regard to the primary outcome, the right and left coronary ostia and proximal coronary arteries were successfully mapped using RMN in all patients and used to guide placement of ablation lesions (Figure 1). Angiography was not performed to guide placement of any ablation lesions within the SOV. One patient did require angiography as the mapping catheter was unable to move distal enough within the left coronary circulation to confirm a safe location for ablation within the great cardiac vein/anterior intraventricular vein bifurcation. No patient suffered an acute complication during the procedure related to mapping, including no occurrences of ST/T-wave changes. At two-week follow up there were no additional complications, although one patient had presented for minor groin bleeding managed conservatively.

With regard to clinical outcomes, acute procedural ablation success defined as elimination of the clinical arrhythmia was achieved in 13/14 (93%) of patients. Duration of longer-term follow up was highly variable, averaging 68 days (range 2 weeks to 6 months) based on patient and medical record availability. Based on available records 11/14 (79%) remained free of the targeted clinical arrhythmia at last evaluation. None had developed subacute or chronic complications attributable to the mapping strategy.

## Discussion

Remote magnetic navigation was introduced into clinical practice in 2003 with demonstration of successful navigation and catheter contact.<sup>8,9</sup> Offering the characteristics of unique maneuverability and stability of catheter tip position in challenging anatomy, the system has demonstrated safety and effectiveness in the treatment of ventricular arrhythmias.<sup>10</sup> This has included several reports specific to OTVT including those arising from the left coronary cusp.<sup>11-14</sup> RMN has also shown improved effectiveness in comparison with manual techniques in the treatment of idiopathic ventricular arrhythmias with a failed prior attempt.<sup>15</sup> At centers with access to this technology, it is often the preferred technique for treatment of patients with these arrhythmias. The current report presents a novel use of this technology to facilitate safe and efficient mapping and ablation in this region.

The unique characteristics of RMN are well suited to this task. In addition to maneuverability and consistent tissue contact, the soft and flexible distal end of the catheter renders it relatively atraumatic in comparison with traditional pull-wire directed manual mapping and ablation catheters<sup>16</sup>. The catheter has also proven to be particularly

adept at accessing vascular anatomy such as the distal coronary sinus and anterior intraventricular vein during EP mapping and ablation procedures. It had been noted anecdotally that the RMN catheter would occasionally unintentionally cannulate the coronary ostia during mapping of the aortic root without any apparent adverse consequences.

Based upon these observations, intentional cannulation of the coronary ostia and proximal arteries in patients without coronary disease undergoing mapping of the aortic root for OTVT became part of clinical workflow. Using this technique, detailed anatomy of the aortic root and surrounding structures can be safely visualized in real time and fully integrated into the electroanatomic mapping system with a high level of precision. Distances between structures and catheter position can be easily measured. As the same mapped anatomy is used to guide and visualize catheter tip position during ablation, the operator benefits from a high level of understanding of the precise location of the catheter tip in relation to these structures therefore facilitating safe application of ablation energy.

Publications dating to the mid-1990s have demonstrated the initial approaches to, and efficacy of, catheter ablation in the treatment of these arrhythmias, beginning with those originating from the RVOT (approximately 60-70% of OTVA).<sup>17</sup> More recent publications have highlighted the challenges associated with mapping and ablation of these arrhythmias from non-RVOT sites. The ability to perform complete mapping of all relevant anatomical structures in this region, including relevant arterial and venous anatomy, can be essential to safe and successful ablation in more challenging cases, where the site of origin is likely to be intramyocardial between adjacent accessible structures.<sup>18</sup> In particular, delivery of RF energy in the SOV requires reliable real-time understanding of the relation between the catheter tip and the location of the coronary ostia.<sup>19,20</sup>

Several strategies have been developed to mitigate risk of injury to the coronary arteries during mapping and ablation of these VAs. The long-term standard practice utilizes angiography to visualize ablation catheter position relative to the coronary artery ostia and course to ensure safe distance for RF ablation. This method often requires additional arterial access for angiography and visual evaluation of the relative position of the ablation catheter tip. The use of intra-procedural angiography can be enhanced using image registration and integration software that allows for visualization of the coronary anatomy in direct relation to electroanatomic mapping.<sup>21</sup> This method allows for angiographic images to be obtained separately from when the ablation catheter is in position, thus reducing the need for separate arterial access and allowing continued mapping with continued reference to vessel position. However, angiography requires contrast exposure, additional fluoroscopy, the presence of expertise in coronary angiography, and carries the rare risks of coronary dissection and air embolism.<sup>22</sup>

To avoid the need for angiography, alternative imaging strategies have been described. Several investigators have published case series describing the use of intracardiac echocardiography (ICE), without angiography, in patients undergoing mapping and ablation of SOV arrhythmias.<sup>23,24</sup> Each report is a single-center case series performed at centers with notable experience in ICE utilization. While successful, the authors appropriately emphasize the importance of significant



operator experience necessary to confidently obtain and interpret the images. Even then, several patients underwent angiography in cases where the coronary ostia, particularly on the right, could not be sufficiently visualized.

Another alternative is the import and integration of advanced imaging (CT/MRI) obtained prior to the procedure with the electroanatomic map created during the procedure.<sup>25</sup> This method has several important limitations including the difficulty of precise image registration and differences in surface representation using different imaging modalities. The acquisition of imaging pre-procedure also raises potential for changes in chamber volumes and therefore position of anatomical structures at the time of the procedure.

In comparison to other described techniques, the described method has several additional advantages. This technique avoids reliance on angiography and the associated additional procedural steps and potential risks involved. While ICE was also used during these procedures as adjunctive imaging, the presented technique avoids the challenges of occasional poor ultrasound visualization of these structures and reduces reliance on highly specialized expertise in ICE image acquisition and interpretation. It should also be noted that ICE may not be available or commonly used during EP procedures in some centers, especially outside the US. Import and registration of CT/MRI segmented images is prone to registration errors and cannot be updated in real time. With safety and effectiveness of ablation of OTVT requiring precision to the level of millimeters, the application of secondary imaging modalities that are not native to the primary mapping system being used introduces significant variables that may reduce the ability of the operator to confidently understand the real-time position of the catheter tip in relation to the anatomy and therefore impact the safety of the procedure.

### Limitations

There are several limitations to the interpretation of this study and potential generalizability of this method. The present study is retrospective, non-randomized, and single center in design with operators who have extensive experience with RMN. As such, it should be considered a demonstration of “proof of concept” and not definitive demonstration of the safety and effectiveness of this method. Further study is warranted to further demonstrate validity. Moreover, the described technique will be limited to providers at the minority of centers with access to remote magnetic navigation technology, thereby limiting more widespread utilization.

### Conclusion

The safety and effectiveness of ablation for idiopathic OTVT relies on detailed understanding and precise real-time localization of relevant anatomical structures and the position of the tip of the ablation catheter where energy is to be delivered. As opposed to traditional methods including angiography, ICE imaging, and CT/MRI integration, the use of RMN to directly map these structures into the electroanatomic map offers a highly precise, efficient, safe, and reproducible technique that can potentially optimize operator confidence and patient safety during these procedures.

### References

1. Armbrust C, Levine S. Paroxysmal Ventricular Tachycardia: A Study of One Hundred and Seven Cases. *Circulation*. 1950;1(1):28-40. doi:10.1161/01.cir.1.1.28
2. Brooks R, Burgess JH. Idiopathic ventricular tachycardia. A review. *Medicine (Baltimore)*. 1988;67:271-294.
3. Klein LS, Shih HT, Hackett FK, Zipes DP, Miles WM. Radiofrequency catheter ablation of ventricular tachycardia in patients without structural heart disease. *Circulation*. 1992 May;85(5):1666-74. doi: 10.1161/01.cir.85.5.1666. PMID: 1572025.
4. Yamada T, McElderry HT, Doppalapudi H, Murakami Y, Yoshida Y, Yoshida N, Okada T, Tsuboi N, Inden Y, Murohara T, Epstein AE, Plumb VJ, Singh SP, Kay GN. Idiopathic ventricular arrhythmias originating from the aortic root prevalence, electrocardiographic and electrophysiologic characteristics, and results of radiofrequency catheter ablation. *J Am Coll Cardiol*. 2008 Jul 8;52(2):139-47. doi: 10.1016/j.jacc.2008.03.040. PMID: 18598894.
5. Yamada T, Litovsky SH, Kay GN. The left ventricular ostium: an anatomic concept relevant to idiopathic ventricular arrhythmias. *Circ Arrhythm Electrophysiol*. 2008 Dec;1(5):396-404. doi: 10.1161/CIRCEP.108.795948. PMID: 19808434.
6. Ouyang F, Fotuhi P, Ho SY, Hebe J, Volkmer M, Goya M, Burns M, Antz M, Ernst S, Cappato R, Kuck KH. Repetitive monomorphic ventricular tachycardia originating from the aortic sinus cusp: electrocardiographic characterization for guiding catheter ablation. *J Am Coll Cardiol*. 2002 Feb 6;39(3):500-8. doi: 10.1016/s0735-1097(01)01767-3. PMID: 11823089.
7. Yamada T, McElderry HT, Doppalapudi H, Okada T, Murakami Y, Yoshida Y, Yoshida N, Inden Y, Murohara T, Plumb VJ, Kay GN. Idiopathic ventricular arrhythmias originating from the left ventricular summit: anatomic concepts relevant to ablation. *Circ Arrhythm Electrophysiol*. 2010 Dec;3(6):616-23. doi: 10.1161/CIRCEP.110.939744. Epub 2010 Sep 20. PMID: 20855374.
8. Faddis M, Chen J, Osborn J, Talcott M, Cain ME, Lindsay BD. Magnetic guidance system for cardiac electrophysiology: a prospective trial of safety and efficacy in humans. *Journal of the American College of Cardiology*, Volume 42, Issue 11, 2003
9. Ernst S, Ouyang F, Linder C, et al. Initial experience with remote catheter ablation using a novel magnetic navigation system. *magnetic remote catheter ablation. Circulation* 2004; 109:1472-1475
10. Turagam MK, Atkins D, Tung R et al. A meta-analysis of manual versus remote magnetic navigation for ventricular tachycardia ablation. *J Interv Card Electrophysiol* 49, 227-235 (2017).
11. Thornton AS, Jordaens LJ. Remote magnetic navigation for mapping and ablating right ventricular outflow tract tachycardia. *Heart Rhythm*. 2006 Jun; 3(6): 691-6. doi: 10.1016/j.hrthm.2006.01.028. Epub 2006 Feb 28. PMID: 16731472.
12. Shauer A, De Vries LJ, Akca F, Palazzolo J, Shurrab M, Lashevsky I, Tiong I, Singh SM, Newman D, Szili-Torok T, Crystal E. Clinical research: remote magnetic navigation vs. manually controlled catheter ablation of right ventricular outflow tract arrhythmias: a retrospective study, *EP Europace*, Volume 20, Issue suppl\_2, May 2018, Pages ii28-ii32, <https://doi.org/10.1093/europace/eux382>
13. Burkhardt JD, Saliba WI, Schweikert RA, Cummings J, Natale A. Remote magnetic navigation to map and ablate left coronary cusp ventricular tachycardia. *J Cardiovasc Electrophysiol*. 2006 Oct;17(10):1142-4. doi: 10.1111/j.1540-8167.2006.00559.x. Epub 2006 Jul 18. PMID: 16879625.
14. Schwagten BK, Szili-Torok T, Rivero-Ayerza M, Jessurun E, Valk S, Jordaens LJ. Usefulness of remote magnetic navigation for ablation of ventricular arrhythmias originating from outflow regions. *Neth Heart J*. 2009;17(6):245-249. doi:10.1007/BF03086255
15. Kawamura M, Scheinman MM, Tseng ZH et al. Comparison of remote magnetic navigation ablation and manual ablation of idiopathic ventricular arrhythmia after failed manual ablation. *J Interv Card Electrophysiol* 48, 35-42 (2017).
16. Schmidt B, Ryul K, Chun J, Tilz RR, Koektuerk B, Ouyang F, Kuck KH. Remote



- navigation systems in electrophysiology, EP Europace, Volume 10, Issue suppl\_3, November 2008, Pages iii57–iii61, <https://doi.org/10.1093/europace/eun234>
17. Morady F, Kadish AH, DiCarlo L, Kou WH, Winston S, deBuitier M, Calkins H, Rosenheck S, Sousa J. Long-term results of catheter ablation of idiopathic right ventricular tachycardia. *Circulation*. 1990 Dec;82(6):2093-9. doi: 10.1161/01.cir.82.6.2093. PMID: 2242533.
  18. Yamada T, Yoshida N, Doppalapudi H, Litovsky SH, McElderry HT, Kay GN. Efficacy of an Anatomical Approach in Radiofrequency Catheter Ablation of Idiopathic Ventricular Arrhythmias Originating From the Left Ventricular Outflow Tract. *Circ Arrhythm Electrophysiol*. 2017 May;10(5):e004959. doi: 10.1161/CIRCEP.116.004959. PMID: 28500177.
  19. D'Avila A, Gutierrez P, Scanavacca M, Reddy V, Lustgarten DL, Sosa E, Ramirez JA. Effects of radiofrequency pulses delivered in the vicinity of the coronary arteries: implications for nonsurgical transthoracic epicardial catheter ablation to treat ventricular tachycardia. *Pacing Clin Electrophysiol*. 2002 Oct;25(10):1488-95. doi: 10.1046/j.1460-9592.2002.01488.x. PMID: 12418747.
  20. Pons M, Beck L, Leclercq F, Ferriere M, Albat B, Davy JM. Chronic left main coronary artery occlusion: a complication of radiofrequency ablation of idiopathic left ventricular tachycardia. *Pacing Clin Electrophysiol*. 1997 Jul;20(7):1874-6. doi: 10.1111/j.1540-8159.1997.tb03580.x. PMID: 9249845.
  21. Jularic M, Akbulak RO, Schäffer B, Moser J, Nuehrich J, Meyer C, Eickholt C, Willems S, Hoffmann BA. Image integration into 3-dimensional-electro-anatomical mapping system facilitates safe ablation of ventricular arrhythmias originating from the aortic root and its vicinity, EP Europace, Volume 20, Issue 3, March 2018, Pages 520–527, <https://doi.org/10.1093/europace/euw399>
  22. Tavakol M, Ashraf S, Brener SJ. Risks and complications of coronary angiography: a comprehensive review. *Glob J Health Sci*. 2012 Jan 1;4(1):65-93. doi: 10.5539/gjhs.v4n1p65. PMID: 22980117; PMCID: PMC4777042.
  23. Hoffmayer KS, Dewland TA, Hsia HH, Badhwar N, Hsu JC, Tseng ZH, Marcus GM, Scheinman MM, Gerstenfeld EP. Safety of radiofrequency catheter ablation without coronary angiography in aortic cusp ventricular arrhythmias. *Heart Rhythm*. 2014 Jul;11(7):1117-21. doi: 10.1016/j.hrthm.2014.04.019. Epub 2014 Apr 13. PMID: 24732373.
  24. Al Asmar M, Houssari M, Carlos El-Tallawi K, Feghali T, Refaat M, Khoury M, Abi-Saleh B. Safety of mapping in the sinus of valsalva region under intracardiac echocardiography guidance without angiography. *Indian Pacing Electrophysiol J*. 2021 May-Jun;21(3):141-144. doi: 10.1016/j.ipej.2021.02.003. Epub 2021 Feb 8. PMID: 33571656; PMCID: PMC8116810.
  25. Piers SR, Zeppenfeld K. Imaging-guided Ventricular Tachycardia Ablation. *Arrhythm Electrophysiol Rev*. 2013 Nov;2(2):128-34. doi: 10.15420/aer.2013.2.2.128. Epub 2013 Nov 29. PMID: 26835054; PMCID: PMC4711544.

## Acute and Long-Term Results of Catheter Ablation of Outflow Tract Arrhythmias using Remote Magnetic Navigation with Catheter–Tissue Contact Feedback Technology: Comparison with Manual Ablation

Leonor Parreira<sup>1,2</sup>, Pedro Carmo<sup>1</sup>, Rita Marinheiro<sup>2</sup>, Jose Venancio<sup>2</sup>, Duarte Chambel<sup>2</sup>, Silvia Nunes<sup>1</sup>, Joana Pinho<sup>1</sup>, Rui Coelho<sup>2</sup>, Diogo Cavaco<sup>1</sup>, Francisco Costa<sup>1</sup>, Pedro Adragao<sup>1</sup>

<sup>1</sup>Luz Hospital Lisbon. Av. Lusitana 100, 1500-650 Lisboa Portugal

<sup>2</sup>Setubal Hospital Centre. R. Camilo Castelo Branco 175, 2910-549 Setubal Portugal

### Abstract

**Background and aim:** Studies evaluating the results of remote magnetic navigation (RMN) using catheter–tissue contact feedback technology are scarce. The aim of this study was to compare the results of ablation of ventricular outflow tract arrhythmias with RMN using the catheter–tissue contact feedback technology with manual ablation with and without contact-force (CF) technology.

**Methods:** Retrospective study of patients that underwent ablation of ventricular outflow tract arrhythmias between May 2017 and December 2021 by the same operator in two hospitals. Patients were excluded in the presence of structural heart disease or previous ablation. Procedural data, success and complication rates and recurrence were compared.

**Results:** Total of 81 patients, 45 underwent ablation with RMN (RMN group), 18 with manual catheters without CF technology (Manual group) and 18 with CF catheters (CF group). The three groups did not differ in relation to baseline characteristics. Patients in the CF group had a higher frequency of arrhythmias originating from the LVOT. The procedure and radiofrequency times were not significantly different, the fluoroscopy time was significantly lower in the RMN group when comparing with Manual and CF groups, 3 (2-5.5) min vs 12 (5.7-17) vs 9.5 (4.9-14.4) min,  $p < 0.0001$ . There was a direct correlation between fluoroscopy time and procedure time for manual ablation ( $R = 0.480$ ,  $p = 0.003$ ), but not for RMN ( $R = 0.200$ ,  $p = 0.188$ ),  $p < 0.0001$ . Global success rate was 88% and complication rate was 1% which were not significantly different between groups. Median follow-up was 910 (485-1440) days, recurrence rate was not significantly different (Log-Rank = 0.455)

**Conclusions:** RMN ablation of ventricular outflow tract arrhythmias using the catheter–tissue contact feedback technology demonstrated high success and low recurrence rates, with a significantly lower fluoroscopy time than manual or CF guided ablation. When ablation was performed with RMN there was no correlation between the length of the procedure and the fluoroscopy time.

### Introduction

Ablation of premature ventricular contractions (PVCs) is an effective procedure and a class I indication in symptomatic patients with a high PVC burden<sup>1</sup>. The ventricular outflow tracts are the most frequent

sites of origin of idiopathic arrhythmias. Not only the right ventricular outflow tract (RVOT) but as shown in a recent contemporary study, also the left ventricular outflow tract (LVOT) and especially the aortic cusps<sup>2</sup>.

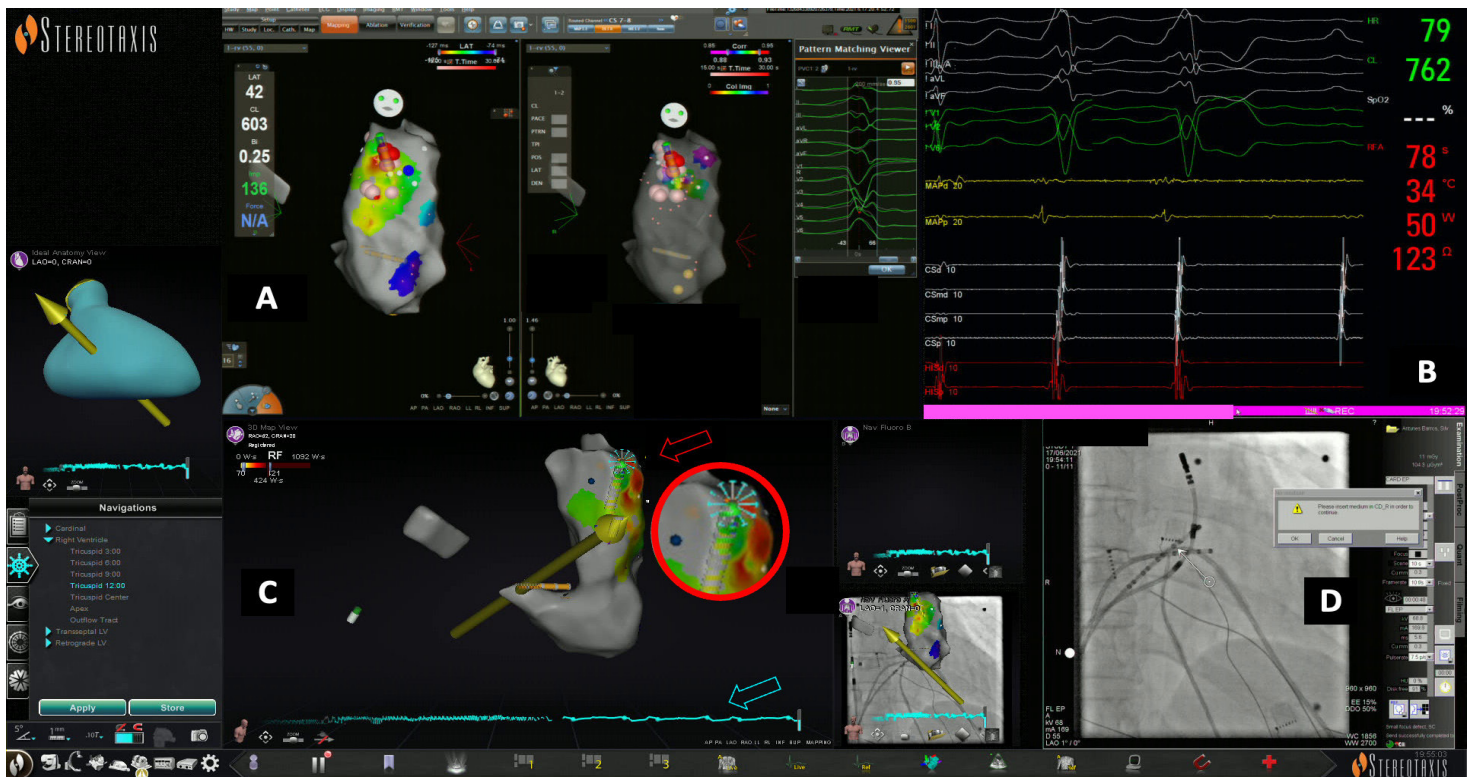
### Key Words

Remote Magnetic Navigation; Premature Ventricular Contractions; Ventricular Outflow Tracts; Catheter Ablation; Catheter-Tissue Contact Feedback

### Corresponding Author

Leonor Parreira,  
Av Dr António Rodrigues Manito, 114 2900-064  
Setubal Portugal.

Remote magnetic navigation (RMN) presents as an excellent option when catheter manipulation should be smooth to prevent PVCs induced by the catheter, an event frequent at the level of the outflow tracts<sup>3,4</sup>. It is known for a long time that the tissue–catheter contact is important for lesion formation<sup>5</sup>. In recent years, the development of contact force (CF)–sensing catheters has promised an improvement in outcomes of manual catheter ablation of ventricular arrhythmias. One of the concerns regarding RMN is the unavailability of contact force



**Figure 1:** RMN workstation screen displaying simultaneously the different screens during the procedure.

Panel A: EAM showing RF applications at the earliest activation site (red and pink dots), His tagged (yellow dots); Panel B: intracardiac electrograms during ablation displaying the RF application parameters; Panel C: RMN screen showing the yellow arrow that remotely commands the direction of the ablation catheter. Good contact of the catheter tip showing an optimal starburst (red arrow) and a contact tracing displaying a solid line (blue arrow); Panel D: Fluoroscopy screen with overlaid EAM. EAM: Electroanatomical map; RF: radiofrequency; RMN: remote magnetic navigation.

catheters, but this would go against the concept of RMN. This system is characterized by the high stability of the catheter tip, leading to a similar lesion size when compared to conventional ablation, although with less force applied to the tissue<sup>6</sup>. Contact feedback technology became available for RMN with the development of the e-Contact Module (ECM), which allows a semi-quantitative assessment of the catheter tip-to-tissue contact<sup>7</sup>. Studies comparing manual vs. RMN guided ablation after the advent of this technology are lacking. The aim of this study was to compare the results of RMN ablation of outflow tract arrhythmias using the catheter-tissue contact feedback technology against manual with and without CF catheters.

## 2. Material and methods

### 2.1. Patient population

This was a retrospective series of consecutive patients who underwent catheter ablation of idiopathic PVCs or ventricular tachycardia (VT) from the outflow tracts by the same operator, from May 2017 to December 2021. This study was performed in two hospitals, the procedures using RMN took place at the Luz Hospital Lisbon and the manual procedures at Setubal Hospital Center.

All patients underwent 12-lead ECG, transthoracic echocardiography and cardiac magnetic resonance with late gadolinium enhancement to exclude the presence of structural heart disease. Arrhythmogenic right ventricular cardiomyopathy (ARVC) was ruled out according to the Task Force Criteria<sup>8</sup>. Patients with evidence of structural heart disease

and those that had undergone a previous ablation were excluded. A 24-hour Holter recording was performed before ablation and the number of PVCs per 24 hours and the presence of episodes of non-sustained ventricular tachycardia (NSVT), defined as >3 PVCs in a run were assessed.

### 2.2. Study design

Patients were divided in three groups whether ablation was performed with RMN (RMN group), manually with catheter without CF sensor (Manual group) or manually with a CF catheter (CF group). Baseline characteristics and procedural data were evaluated and compared between groups. Correlation between the procedure time and fluoroscopy time was assessed. Patients were followed and recurrence was registered, the recurrence-free survival curves were obtained and compared in the three groups. The influence of predictive variables related to the procedure on recurrence during follow-up was evaluated.

### 2.3. Electroanatomic Mapping and Ablation

Patients were studied in a fasting non sedate state. All beta-blockers and antiarrhythmic drugs were discontinued at least five half-lives before the electrophysiological study. In patients with VT, programmed ventricular stimulation was performed to induce VT and isoprenaline was administered when needed. During endocardial mapping of the LVOT heparin was administered to achieve an ACT of 250–300 sec. In the RMN group the procedures were performed with the Niobe ES Magnetic Navigation System (Stereotaxis, Inc., Saint Louis, MO,



USA) and the CARTO 3 RMT (Biosense-Webster, Inc., Diamond Bar, CA, USA) system. An irrigated tip Navistar RMT Thermocool catheter (Biosense-Webster Inc., Diamond Bar, CA, USA) was used with a 3.5-mm distal tip electrode and a 2–5–2 interelectrode distance (Figure 1).

Manual procedures were all performed with the EnSite Precision (Abbott, St Paul, MN, USA) system, using an irrigated tip FlexAbility (Abbott, St Paul, MN, USA) catheter with a 4-mm distal tip electrode and 1-4-1 interelectrode spacing in the first 18 patients (Figure 2) and a TactiCath catheter (Abbott, St Paul, MN, USA) with a 3.5-mm distal tip electrode and a 2–2–2 interelectrode distance in the last 18 patients (Figure 3). Mapping of the LVOT endocardium and the aortic coronary cusps was performed using a transaortic approach in all patients. When ablation was unsuccessful at the coronary cusps or the LVOT, the coronary sinus, the great cardiac vein and anterior interventricular vein were mapped. With the CARTO 3 RMT (Biosense-Webster, Inc.) system, local activation time (LAT) was defined as the time of the maximum downslope of the unipolar distal electrogram displayed on the corresponding bipolar signal. With the EnSite Precision system LAT was defined as the time of the first peak of the bipolar electrogram<sup>9</sup>. The ablation site was selected based on the earliest endocardial activation time in relation to the onset of the surface QRS, with a QS pattern at the unipolar electrogram and confirmed by the pace mapping that provided at least 11 out of 12 pace matches between paced and spontaneous PVCs. LAT at the ablation site was measured in relation to the beginning of the QRS on the surface ECG. In patients in whom the site of the origin of the PVCs was the LVOT or aortic coronary cusps, a coronary angiography was performed before ablation. Energy was delivered from an RF generator between the distal electrode of the ablation catheter and a cutaneous patch, for up to 120 sec, to a maximum temperature of 43° C and titrated according to the location of the PVCs, to a power output limit of 50 W. When the application was ineffective, additional applications were delivered to sites adjacent to the earliest activation site. In the CF group a contact force above 30 g was avoided for all ablations. During ablation, light sedation with midazolam (bolus) or remifentanyl (continuous perfusion) was administered when needed. There were no differences between ablation strategies in the Manual, CF, or RMN ablation groups. Success was defined as non-induction of VT or abolition of PVCs until 30 min after ablation. The evaluated parameters were procedure time assessed as the interval between patient's entrance and exit of the room, fluoroscopy time, total radiofrequency time, site of origin of the arrhythmia, LAT at ablation site, acute success rate, and complications related to catheter manipulation or ablation, like steam pops, thrombus formation and stroke, perforation, tamponade, pericarditis, or lesions to adjacent structures. All intracardiac electrograms were reviewed by two senior electrophysiologists.

#### 2.4. e-Contact Module

All RMN procedures were done with the ECM that provides a semi-quantitative evaluation of the catheter tip-to-tissue contact, and optimal contact was the goal throughout the procedure (Figure 1). This technology has already been well described by Notén et al<sup>7</sup> but basically, the ECM software algorithm analyses 3 categories of data to determine whether the catheter is in contact with cardiac tissue. These categories are electrical impedance measurements, cardiac-induced

motion of the catheter tip, and the torque being applied by the magnetic field. The contact assessment is visualized to the user on the RMN screen as a starburst at the catheter tip (Figure 1 red arrow) and as a blue line on the contact tracing (Figure 1 blue arrow). When there is no contact the starburst is absent, with minimal contact the starburst is faint and has only few lines, and with optimal contact the starburst is bold and has multiple lines. Regarding the contact tracing, it shows a dotted line when the contact is suboptimal and a solid line when the contact is optimal.

#### 2.5. Follow-up

The follow-up was performed at the office on the first month, at six months, at one year and yearly after that. Clinical assessment was carried out and at least one 24-hour Holter recording was performed between one month and six months after ablation and once a year

**Table 1: Baseline characteristics and comparison between groups**

	Overall sample (n=81)	RMN group (n=45)	Manual group (n=18)	Manual CF group (n=18)	P value
<b>Demographic data</b>					
Age in years, median (Q <sub>1</sub> -Q <sub>3</sub> )	50 (40-63)	50 (40-60)	48 (39-65)	60 (43-66)	0.199
Male Gender, n (%)	36 (44)	16 (36)	11 (61)	9 (50)	0.158
<b>Risk factors, history, and medications</b>					
Hypertension, n (%)	17 (21)	6 (13)	7 (39)	4 (22)	0.079
Diabetes, n (%)	5 (6)	1 (2)	1 (6)	3 (17)	0.098
Syncope or pre-syncope, n (%)	8 (10)	4 (9)	2 (11)	2 (11)	0.946
Duration of symptoms in months, median (Q <sub>1</sub> -Q <sub>3</sub> )	24 (12-30)	24 (12-25)	24 (12-36)	24 (12-42)	0.636
Family history of sudden death, n (%)	3 (4)	1 (2)	1 (6)	1 (6)	0.732
Betablockers, n (%)	56 (69)	31 (69)	15 (83)	10 (56)	0.196
Class I or III AA*	13 (16)	5 (11)	3 (17)	5 (28)	0.265
<b>Standard 12 lead ECG</b>					
PVC/VT	77/4	45/2	18/0	16/2	0.298
T wave inversion beyond V1, n (%)	5 (6)	3 (7)	1 (6)	1 (6)	0.979
<b>PVC precordial transition</b>					
V1 or V2, n (%)	11 (14)	5 (11)	1 (6)	5 (27)	0.116
V3, (n%)	18 (22)	11 (24)	4 (22)	3 (17)	0.799
Beyond V3, n (%)	52 (64)	29 (64)	13 (72)	10 (56)	0.580
<b>24-Hour Holter Monitoring</b>					
Number of PVCs, in nx100, median (Q <sub>1</sub> -Q <sub>3</sub> )	200 (140-272)	200 (140-247)	214 (156-305)	228 (133-334)	0.667
NSVT, n (%)	26 (32)	13 (29)	7 (39)	6 (33)	0.857
<b>Echocardiogram</b>					
LVEF in %, median (Q <sub>1</sub> -Q <sub>3</sub> )	58 (55-60)	58 (57-60)	57 (54-60)	57 (55-60)	0.497
LAD in mm, median (Q <sub>1</sub> -Q <sub>3</sub> )	35 (33-40)	35 (33-37)	37 (33-42)	36 (35-40)	0.222

\*Except amiodarone; LAD: left atrium diameter; LVEF: left ventricular ejection fraction; NSVT: non-sustained ventricular tachycardia; PVC: premature ventricular contractions; VT: ventricular tachycardia



**Table 2: Procedural data and follow-up data**

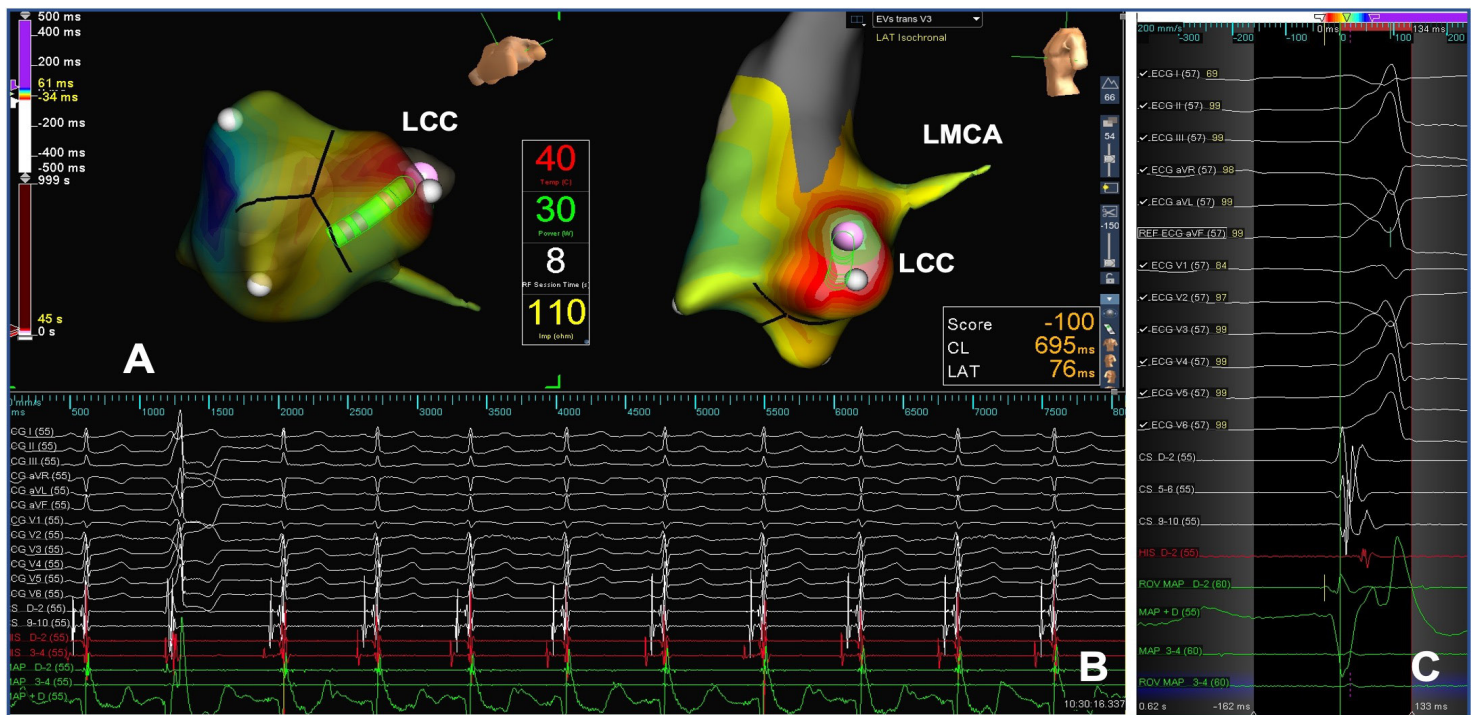
	Overall sample (n=81)	RMN Group (n=45)	Manual group (n=18)	Manual CF group (n=18)	P value
Procedure time in min, median (Q1-Q3)	138 (120-180)	140 (118-180)	159 (114-205)	120 (118-165)	0.680
Fluoroscopy time in min, median (Q1-Q3)	5 (2.5-10)	3 (2-5.5)	12 (5.7-17)	9.5 (4.9-14.4)	<0.0001
RF duration in sec, median (Q1-Q3)	300 (120-540)	300 (120-530)	400 (120-625)	330 (120-650)	0.796
<b>Site of origin</b>					
RVOT, n (%)	61 (75)	36 (80)	15 (83)	10 (56)	0.085
LVOT, n (%)	15 (19)	6 (13)	2 (11)	7 (39)	0.041
LV summit, n (%)	5 (6)	3 (7)	1 (6)	1 (6)	0.979
LAT at ablation site, median (Q1-Q3)	37 (30-45)	34 (24-43)	40 (35-45)	37 (27-47)	0.148
Overall acute success rate, n (%)	71 (88)	40 (89)	15 (83)	16 (89)	0.819
Acute success in the RVOT, n (%)	53 (87)	32 (89)	12 (80)	9 (90)	0.658
Acute success in the LVOT, n (%)	15 (100)	6 (100)	2 (100)	7 (100)	-
Acute success in the LV summit, n (%)	3 (60)	2 (67)	1 (100)	0 (0)	0.329
Complications, n (%)	1 (1)	0 (0)	0 (0)	1 (6)	0.170
Follow-up time in days, median (Q1-Q3)	910 (485-1440)	1095 (571-1569)	1229 (896-1669)	330 (82-650)	<0.0001
Recurrence*, n (%)	11 (16)	5 (13)	4 (27)	2 (13)	0.404

\* After a successful procedure. CF: contact-force; LAT: local activation time; LVOT: left ventricular outflow tract; LV: left ventricle; RF: radiofrequency; RMN: remote magnetic navigation; RVOT: right ventricular outflow tract.

thereafter. For patients that were followed at another institution data were retrieved from the national patient registry and from medical records or discharge letters and were validated by reviewing patients' files. Patients who failed to have recent clinical records were contacted by phone. Recurrence was defined as reappearance of symptoms or a 24-hour Holter with a PVC number higher than 1000 PVCs per 24 hours.

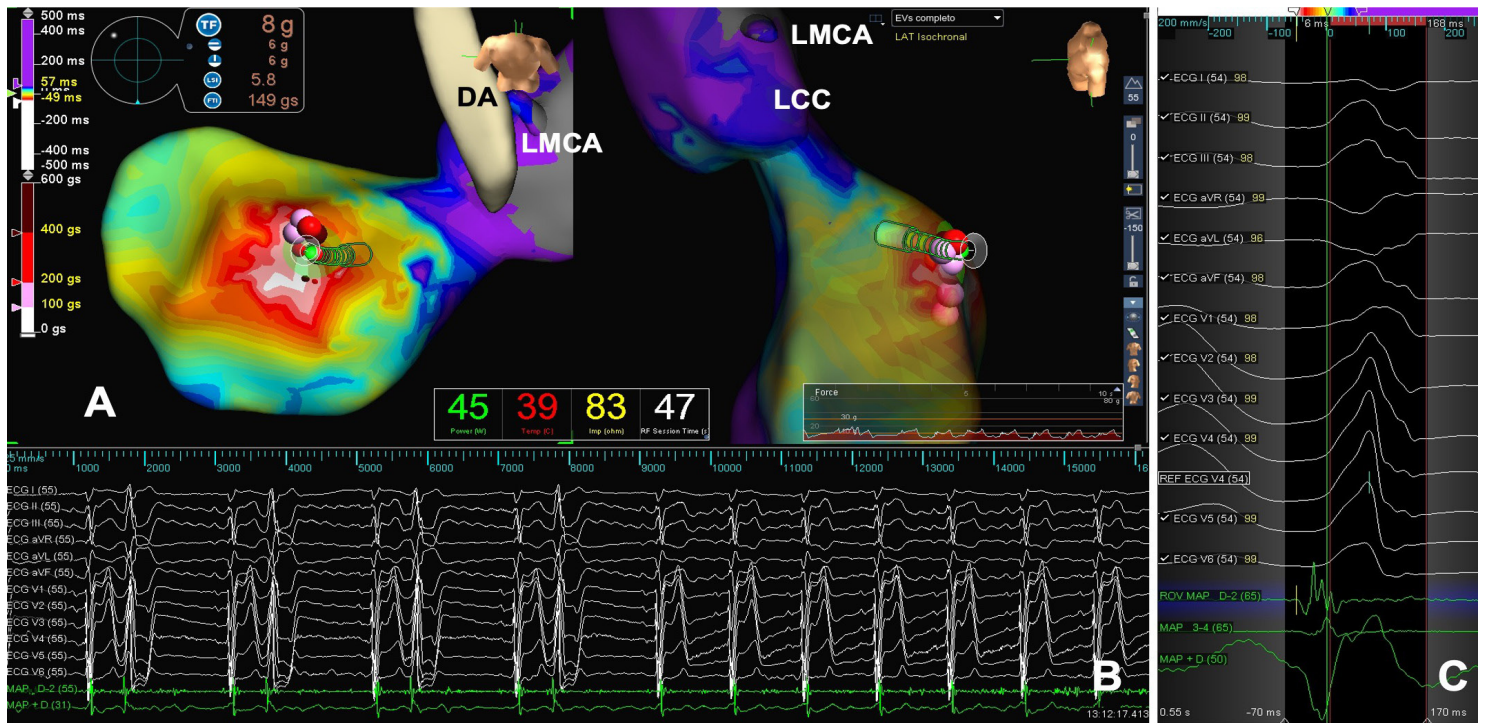**2.6. Statistical analysis**

All analyses were performed using SPSS statistical software, version 25.0 (SPSS, Inc, Chicago, Illinois). Data is presented as median and lower and upper quartile (Q1-Q3) for continuous variables and as absolute numbers and percentages for categorical variables. Continuous variables were compared with the use of Kruskal Wallis test for multiple samples. Categorical variables were compared with the use of the chi-squared test for independent samples. The correlation between the procedure time and the fluoroscopy time was performed with a Pearson correlation coefficient, R. Kaplan-Meier survival function was used to compare the recurrence-free survival in the three groups and the Log-rank test for comparison between groups. The influence of predictive variables on recurrence during follow-up was evaluated by Cox regression analysis. Univariate analysis was performed to select the variables to be included in the multivariate analysis. We included in the multivariate analysis those variables with a p-value ≤ 0.05 in the univariate analysis. Hazard ratios and their 95% confidence intervals were calculated. For all tests a p value <0.05 was considered as statistically significant.



**Figure 2: Example of a case of PVCs from the LCC performed manually with a catheter without CF technology.**

Panel A: EAM showing the tip of the ablation catheter at the S00; Panel B: PVCs disappear in the first seconds of RF application; Panel C: PVC morphology and intracardiac signals at ablation site. CF: contact force; EAM: electroanatomical map; LCC: left coronary cusp; LMCA: left main coronary artery; PVC: premature ventricular contractions; RF: radiofrequency; S00: site of origin



**Figure 3:** Example of a case of PVCs from the LVOT performed manually with a CF-catheter.

Panel A: EAM showing the tip of the ablation catheter at the SOO; Panel B: PVCs disappear during RF application; Panel C: PVC morphology and intracardiac signals at ablation site. CF: contact force; DA: descending thoracic aorta; EAM: electroanatomical map; LCC: left coronary cusp; LMCA: left main coronary artery; PVC: premature ventricular contractions; RF: radiofrequency; SOO: site of origin

**2.7. Ethics**

All patients signed the informed consent form, and the study was approved by the Ethical Committee of both hospitals. The study is in compliance with the Helsinki Declaration.

**3. Results**

**3.1. Patient population**

We included 81 patients, median age 50 (40-63) years, 44% males. Baseline characteristics of the study patients as well as comparison between the groups are displayed in Table 1. All patients were symptomatic mostly with palpitations, the median duration of symptoms was 24 (12-30) months and 10% had a history of syncope or pre-syncope. Only four patients presented with sustained VT, the other seventy-seven had frequent PVCs with a median of 20,000 (14,000-27,200) of PVCs/24 hours prior to ablation. Five patients had T wave inversion beyond V1 but none with diagnostic criteria for ARVC, the transition of the PVC was at V3 or after V3 in 86% of patients. The median LVEF was 58% (55-60) and only four patients had LVEF below 45% that recovered after successful ablation. Patients in the three groups did not differ in relation to the analyzed parameters (Table 1).

**3.2. Electroanatomical Mapping and ablation**

**3.2.1. Procedure Data**

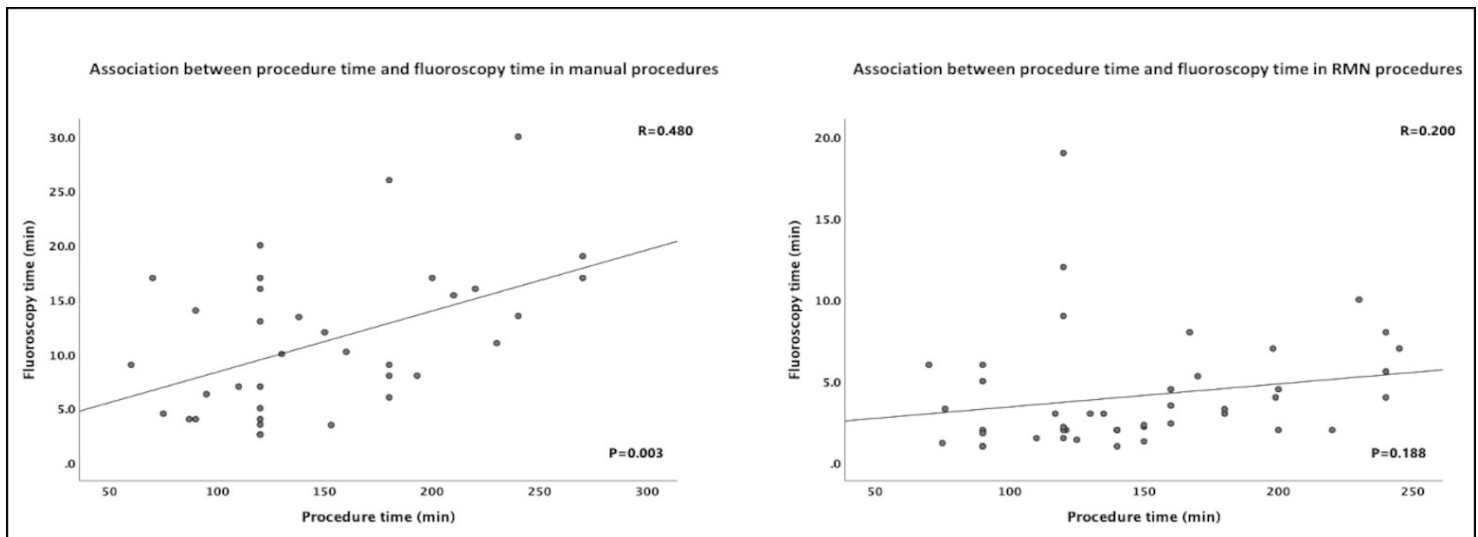
Procedure data is displayed in Table 2. The procedure time, RF duration, or precocity of the electrogram at the ablation site were not significantly different between groups. Regarding the site of origin of the PVCs, the LVOT was more frequently the site of origin of the arrhythmia in the CF group (39% vs 13% vs 11%, p=0.041), than in the RMN and Manual groups respectively, the RVOT and the LV

summit were equally represented in the three groups. All patients with sustained VT had the origin of the arrhythmia in the RVOT. Fluoroscopy time was significantly lower in the RMN vs Manual and CF groups, respectively 3 (2-5.5) min, 12 (5.7-17) min and 9.5 (4.9-14.4) min, p<0.0001. The overall acute success rate of 88% was not significantly different among groups. The site of origin of the PVCs was not associated with differences in the success of the procedure. One patient in the CF group developed a pericardial effusion that prolonged the hospital stay for another 48 hours and responded to pharmacological management.

**Table 3:** Cox regression analysis with crude and adjusted hazard ratios (HR) of recurrence for the evaluated procedure variables

Variables	Unadjusted		Adjusted†	
	HR (95% CI)	P value	HR (95% CI)	P value
Procedure with RMN	0.552 (0.168-1.804)	0.327	-	-
Procedure with CF	0.972 (0.208-4.54)	0.971	-	-
Procedure time	1.015 (1.004-1.026)	0.007	1.013 (1.00-1.025)	0.049
Radiofrequency time	1.001 (0.999-1.003)	0.251	-	-
Fluoroscopy time	1.057 (0.985-1.135)	0.122	-	-
LAT at SOO	1.019 (0.971-1.068)	0.452	-	-
RVOT site	0.768 (0.203-2.902)	0.697	-	-
LVOT site	0.414 (0.053-3.236)	0.401	-	-
LV summit site	7.604 (1.599-36.17)	0.011	2.283 (0.356-14.64)	0.384

† HR adjusted to procedure time and summit site. CF: contact-force; LAT: local activation time; LVOT: left ventricular outflow tract; LV: left ventricle; RMN: remote magnetic navigation; SOO: site of origin.



**Figure 4:** Correlation between procedure time and fluoroscopy time during manual and RMN procedures

### 3.2.2. Correlation between procedure time and fluoroscopy time

The fluoroscopy time was positively correlated with the procedure time in the overall sample increasing with the latter ( $R=0.318$ ;  $p=0.004$ ). However, although this was also true for the manual group in whom the correlation was stronger ( $R=0.480$ ;  $p=0.003$ ) in the RMN group there was no correlation (Figure 4).

### 3.3. Follow-up

The median follow-up time in the overall study population was 910 (485-1440) days, minimal 31 days, and maximal 1775 days. No patients were lost to follow-up. The follow-up was significantly shorter for the CF group. During this time eleven patients (16%) had recurrence of the PVCs, four within the first 24 hours, two in the RMN group and one patient in the other two groups. The survival free from recurrence Kaplan-Meier curves for the three groups are displayed in Figure 5. The recurrence rate was not significantly different ( $\log\text{-rank}=0.455$ ). The first Holter performed after ablation in patients that underwent a successful procedure and did not present recurrence of symptoms, showed a median of 10 (0-100) PVCs /24 hours.

### 3.4. Predictors of recurrence

The influence of the analyzed variables on recurrence during follow-up were tested with Cox regression analysis. The HR (95% CI) are displayed in Table 3. The use of RMN or the use of CF was not associated with recurrence when compared to manual non-contact catheters. Both the length of the procedure and the location at the LV summit were associated with a higher recurrence rate, but only the former was independently associated, with an adjusted HR (95% CI) of 1.013 (1.000-1.025),  $p=0.049$ .

## 4. Discussion

The stability of the magnetic catheters used in RMN enables lesion formation with less dependency on CF than with conventional

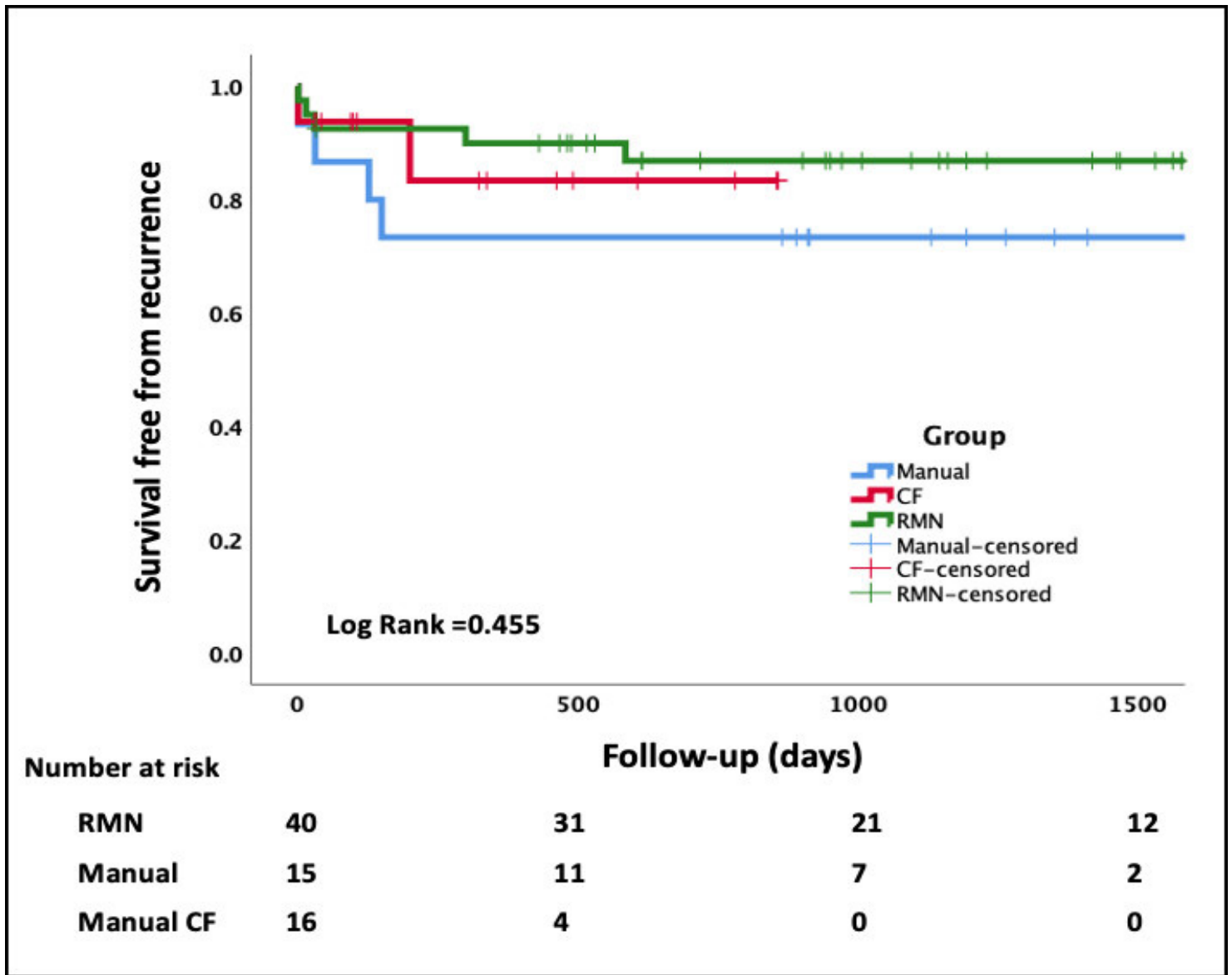
catheters<sup>6</sup>. However, there were some concerns regarding the lack of a contact indicator for RMN, especially after the development of CF technology for manual ablation.

Theoretically CF technology by continuously monitoring the contact force between the catheter tip and the tissues, aims at improving efficacy by an increase of the lesion size which is proportional to the force applied<sup>10,11</sup>, and at the same time decreasing complications resultant from excessive force applied to the heart. Nonetheless, studies comparing manual ablation with and without CF have shown contradictory results<sup>12-14</sup>.

Many previous studies have demonstrated the efficacy of RMN in the ablation of all types of arrhythmias with a better safety profile than conventional ablation<sup>15-19</sup>. Since ECM is now available for RMN it is important to assess its efficacy. This new feature has proved to increase the performance of RMN for ablation of atrial fibrillation leading to a significant reduction in the duration of the RF application that resulted in a shorter duration of the procedure<sup>20</sup>. Also, in the ablation of ischemic ventricular tachycardia has demonstrated higher long-term efficacy and lower fluoroscopy use<sup>18</sup>. However, to the best of our knowledge this is the first study comparing the acute and long-term results of manual versus RMN ablation of PVCs from the outflow tracts, using the novel catheter-tissue contact feedback technology.

Previous studies comparing RMN with manual ablation with and without CF catheters, have already reported no differences in the success rate or the procedure time<sup>21,22</sup>. Our results are similar although with longer procedure times than the ones reported by Shauer et al<sup>22</sup> respectively, 140 (118-180) min for RMN group, 159 (114-205) min for Manual group and 120 (118-165) min for CF group versus 113+ 53 min for RMN and 115 + 69 min for manual ablation which is probably due to the different definitions of procedure duration in that study. As previously reported our study also showed a significant shorter fluoroscopy duration in the RMN group. What is remarkable is the magnitude of the difference in our study in comparison with the studies





**Figure 5:** Kaplan-Meier survival estimate of recurrence after a successful ablation in the three groups

CF: contact-force; RMN: remote magnetic navigation

by Vries et al<sup>21</sup>, Shauer et al<sup>22</sup>, and with our own previous data<sup>4</sup>, which is probably due to the use of ECM technology. A major finding not reported previously, is the absence of correlation between the duration of the procedure and the fluoroscopy time in the RMN group as opposed to the manual procedures where we found a direct correlation. The fact that the dose of radiation remains low independently of the length of the procedure, is particularly important for very long procedures where the use of RMN may lead to an even lower amount of radiation exposure to the patient.

The success rate was not significantly different between groups as previously reported<sup>21,22</sup>. Nevertheless, the success rate with RMN reported in this study was higher than previously reported by our group (89% versus 81%)<sup>4</sup>, or the 80% success rate reported by Shauer et al<sup>22</sup>, using a previous version of the system without ECM. RMN

is associated with a better safety profile than conventional ablation<sup>23</sup> and the development of CF technology has not been able to revert this trend<sup>19</sup>.

The recurrence rate with RMN using ECM technology is low, half the recurrence rate of manual ablation although not reaching statistical significance and lower than previously reported with a similar follow-up time<sup>21</sup>, which may be due to more durable lesions obtained with this technology. The only independent predictor of recurrence was the procedure time. Long procedures usually mean difficult cases, mostly related to one of the following, difficulty on finding the site of origin of the arrhythmia due to infrequent PVCs, inaccessible sites, inability to achieve durable lesions due to intramural focus or a combination of all. So, it is not surprising that the longer the procedure the higher the possibility of recurrence.

## 5. Limitations

There are some potential limitations of the present study. Firstly, there was no randomization, resulting in unbalanced numbers of PVCs from the LVOT in the different groups, however the success of the procedure for PVCs from this location was not different between groups, nor was it associated to recurrence. The follow-up time was significantly shorter for the CF group, but looking at survival curves, had the follow-up time been the same the results would have been at most similar but never better. Secondly, it was a retrospective study with a relatively small number of patients making it insufficient to interpret similar results as non-significant. However, taking into consideration that the success rates for RMN and CF were the same, it is difficult to accept that a bigger sample would show different results. As for the recurrence rate, we may speculate that with a bigger sample and a longer follow-up the recurrence rate might have been lower for the RMN group.

## 6. Conclusions

In this group of patients RMN ablation of outflow tract ventricular arrhythmias using the ECM technology demonstrated a high success and low recurrence rate with significantly lower fluoroscopy times than manual or CF guided ablation. The fluoroscopy time was not correlated with the length of the procedure when performed with RMN, which is particularly important for prolonged procedures.


## References

- Cronin E, Bogun F, Maury P, Peichl P, Chen M, Namboodiri N, Aguinaga L, Leite L, Al-Khatib S, Anter E, Berruezo A, Callans D, Chung M, Cuculich P, d'Avila A, Deal B, Della Bella P, Deneke T, Dickfeld T-M, Hadid C, Haqqani H, Kay G, Latchamsetty R, Marchlinski F, Miller J, Nogami A, Patel A, Pathak R, Morales L, Santangeli P, Sapp J, Sarkozy A, Soejima K, Stevenson W, Tedrow U, Tzou W, Varma N and Zeppenfeld K. 2019 HRS/EHRA/APHRS/LAHS expert consensus statement on catheter ablation of ventricular arrhythmias. *Europace* 2019 Aug; 21(8): 1143–1144
- Hayashi T, Liang J, Shirai Y, Kuo L, Muser D, Kubala MK, Kumareswaran R, Arkles J, Garcia F, Supple G, Schaller R, Frankel D, Riley M, Lin D, Santangeli P, Zado E, Callans D, Marchlinski F and Dixit S. Trends in Successful Ablation Sites and Outcomes of Ablation for Idiopathic Outflow Tract Ventricular Arrhythmias. *J Am Coll Cardiol EP* 2020;6:221–30.
- Konstantinidou M, Koektuerk B, Wissner E, Schmidt B, Zerm T, Ouyang F, Kuck K-H and Chun J. Catheter ablation of right ventricular outflow tract tachycardia: a simplified remote-controlled approach. *Europace* 2011;13:696–700.
- Parreira L, Cavaco D, Reis-Santos K, Carmo P, Cabrita D, Scanavacca M and Adragao P. Remote magnetic navigation for mapping and ablation of right and left ventricular outflow tract arrhythmias. *Rev Port Cardiol* 2013; 32:489–95.
- Haines D. Determinants of Lesion Size During Radiofrequency Catheter Ablation: The Role of Electrode-Tissue Contact Pressure and Duration of Energy Delivery. *J Cardiovasc Electrophysiol* 2008;2:509 - 515
- Thornton A, Brito De Castro C, van Deel E, van Beusekom H and Jordaens L. An in vivo comparison of radiofrequency cardiac lesions formed by standard and magnetically steered 4 mm tip catheters. *Neth Heart J*.2010;18:66-71.
- Noten Z, MD, Geczy T, Yap S-C, Kis Z and Szili-Torok T. Introducing a novel catheter-tissue contact feedback feature in robotic navigated catheter ablation: Utility, feasibility, and safety. *Heart Rhythm* O2 2020; 1:103–110
- Marcus F, McKenna W, Sherrill D, Basso C, Baucé B, Bluemke D, Calkins H, Corrado D, Cox M, Daubert J, Fontaine G, Gear K, Hauer R, Nava A, Picard M, Saffitz J, Sanborn D, Steinberg J, Tandri H, Thiene G, Towbin J, Tsatsopoulou A, Wichter T and Zareba W. Diagnosis of arrhythmogenic right ventricular cardiomyopathy/dysplasia: proposed modification of the Task Force Criteria. *Eur Heart J*. 2010;31: 806–814
- Kim Y-H, Chen S-, Sabine E, Guzman C, Han S, Kalarus Z, Labadet C, Lin Y-J, Lo L-W, Nogami A, Saad E, Sapp J, Sticherling C, Tilz R, Tung Kim Y and Stiles M. 2019 APHRS expert consensus statement on three-dimensional mapping systems for tachycardia developed in collaboration with HRS, EHRA, and LAHRS. *Journal of Arrhythmia* 2019; 36: 215–270.
- Okumura Y, Johnson S, Bunch J, Henz B, O'Brien C, and Packer D. A Systematic Analysis of In Vivo Contact Forces on Virtual Catheter Tip/Tissue Surface Contact during Cardiac Mapping and Intervention. *J Cardiovasc Electrophysiol* 2008;19: 632-640
- Di Biase L, Natale A, Barrett C, Tan C, Elayi C, Ching C, Wang P, Al-Ahmad A, Arruda M, Burkhardt D, Wisnosky B, Chowdhury P, De Marco S, Armaganijan L, Litwak K, Schweikert R and Cummings J. Relationship Between Catheter Forces, Lesion Characteristics, “Popping,” and Char Formation: Experience with Robotic Navigation System. *J Cardiovasc Electrophysiol* 2009;20:436-440
- Zhao Z, Liu X, Gao L, Xi Y, Chen Q, Chang D, Xiao X, Cheng J, Yang Y, Xia Y and Yin X. Benefit of Contact Force-Guided Catheter Ablation for Treating Premature Ventricular Contractions. *Texas Heart Institute Journal* 2020; 47:3-9
- Ábrahám P, Ambrus M, Herczeg S, Szegedi N, Nagy K, Sallo Z, Osztheimer I, Szeplaki G, Tahin T, Merkely B, and Geller L. Similar outcomes with manual contact force ablation catheters and traditional catheters in the treatment of outflow tract premature ventricular complexes. *Europace* 2021;23: 596–602
- Reichlin T, Baldinger S, Pruvot E, Bisch L, Ammann P, Altmann D, Berte B, Kobza R, Haegeli L, Schlatter C, Mueller A, Namdar M, Shah D, Burri H, Conte G, Auricchio A, Knecht S, Osswald S, Asatryan B, Seiler J, Roten L, Kuhne M, and Sticherling C. Impact of contact force sensing technology on outcome of catheter ablation of idiopathic pre-mature ventricular contractions originating from the outflow tracts. *Europace* 2021; 23: 603–609
- Parreira L, Marinheiro R, Carmo P, Cavaco D, Reis-Santos K, Amador P, Teixeira T, Soares A, Costa F and Adragao P. Atrioventricular node reentrant tachycardia: Remote magnetic navigation versus manual ablation impact on operator fluoroscopy time. *Rev Port Cardiol* 2019;38:187-192
- Parreira L, Cavaco D, Carmo P, Reis-Santos K, Quaresma R, Teixeira T, Marques M and Adragao P. Remote magnetic navigation for ablation of typical atrial flutter: Long-term results. *Rev Port Cardiol*. 2014 Dec;33(12):773-9.
- Adragao P, Cavaco D, Ferreira A, Costa F, Parreira L, Carmo P, Morgado F, Reis-Santos K, Santos P, Carvalho M, Durazzo A, Marques H, Goncalves P, Raposo L and Mendes M. Safety and Long-Term Outcomes of Catheter Ablation of Atrial Fibrillation Using Magnetic Navigation versus Manual Conventional Ablation: A Propensity-Score Analysis. *J Cardiovasc Electrophysiol* 2016;27 (Suppl 1):S11-6
- Noten A, Hendriks A, Yap S-C, Mol D, Bhagwandiena R, Wijchers S, Kardys I, Khan M and Szili-Torok T. Contact feedback improves 1-year outcomes of remote magnetic navigation-guided ischemic ventricular tachycardia ablation. *International Journal of Cardiology* 2020;315:36–44
- Blandino A, Bianchi F, Mais A, Mazzanti A, D'Ascenzo F, Grossi S and Musumeci G. Outcomes of manual versus remote magnetic navigation for catheter ablation of ventricular tachycardia: a systematic review and updated meta-analysis. *Pacing Clin Electrophysiol* 2021;44:1102-1114.
- Parreira L, Carmo P, Cavaco D, Pinho J, Costa F, Carmo J, Jeronimo R, Soares A, Marques M and Adragao P. Atrial fibrillation ablation with remote magnetic navigation. The new indicator of catheter tip to tissue contact: a tool or a toy? *Heart Rhythm* 2019; 16, (Suppl): S456
- Vries L, Hendriks A, Yap S, Theuns D, van Domburg R, and Szili-Torok T. Procedural and long-term outcome after catheter ablation of idiopathic outflow tract ventricular arrhythmias: comparing manual, contact force, and magnetic navigated ablation.

Europace 2018; 20: ii22–ii27

22. Shauer A, Vries L, Akca F, Palazzolo J, Shurrah M, Lashevsky I, Tiong I, Singh S, Newman D, Szili-Torok T, and Crystal E. Clinical research: remote magnetic navigation vs manually controlled catheter ablation of right ventricular outflow tract arrhythmias: a retrospective study. *Europace* 2018; 20: ii28–ii32
23. Bauernfeind T, Akca F, Schwagten B, Groot N, VanBelle Y, Valk S, Ujvari B, Jordaens L and Szili-Torok T. The magnetic navigation system allows safety and high efficacy for ablation of arrhythmias. *Europace* 2011; 13:1015–1021





## Robotic Magnetic Navigation in Premature Ventricular Complex Ablation

Fengwei Zou<sup>1</sup>, John D. Burkhardt<sup>2</sup>, Xiaodong Zhang<sup>1</sup>, Aung Naing Lin<sup>1</sup>, Domenico Giovanni Della Rocca<sup>2</sup>, Sanghamitra Mohanty<sup>2</sup>, Amin Al-Abma<sup>2</sup>, Dhanunjaya Lakkireddy<sup>3</sup>, Andrea Natale<sup>2</sup>, Luigi Di Biase<sup>1,2</sup>

<sup>1</sup>Montefiore-Einstein Center for Heart & Vascular Care, Montefiore Medical Center, Bronx, NY, USA

<sup>2</sup>Texas Cardiac Arrhythmia Institute, St. David's Medical Center, Austin, Texas, USA

<sup>3</sup>Kansas City Heart Rhythm Institute at HCA Midwest in Overland Park, Kansas

### Abstract

Premature ventricular complexes (PVCs) are widely common in the general population. In patients with recurrent symptoms and structural heart diseases, catheter ablation is highly effective in treating PVCs. Robotic magnetic navigation (RMN) was developed and applied in PVC ablation in the past two decades. RMN has exhibited inherent advantages over manual ablation since its creation, namely drastically decreased fluoroscopy time, improved catheter maneuverability and stability, and better safety profile. Despite earlier reports of lower efficacy and longer procedure times, technological advances and accumulated user experience have significantly decreased procedure time and improved ablation efficacy while retaining its merits. This review provides a summary of the current evidence in the applications, procedural characteristics, efficacy and safety of RMN in PVC ablations.

### Introduction

Premature ventricular complexes (PVCs) are some of the most common cardiac arrhythmias in the general population. Based on the duration of monitoring, the prevalence of PVC can range from 1% in 12-lead electrocardiogram (ECG) to 70% on 24-hour telemetry<sup>1-3</sup>. Despite its wide prevalence, most patients with PVCs only require reassurance and clinical monitoring especially when PVCs were discovered incidentally without symptoms. In cases of underlying structural heart disease, high PVC burdens, or recurrent symptoms (palpitations, shortness of breath, syncope and etc.), further interventions are needed. For years, manual percutaneous catheter ablation is has been shown to be an effective and safe approach to eliminate or reduce the burden of PVCs with ablation success rates ranging from 80-95% and low complication rates<sup>4</sup>. However, manual catheter ablation of PVCs originating from anatomical locations difficult to reach such as the left ventricular (LV) summit region still remains a challenge. Ablation success of these PVC origins is limited by restricted catheter maneuverability, close proximity to core vasculature

including the left anterior descending (LAD) coronary artery, the need for epicardial access, long procedure times and operator fatigue<sup>5</sup>. To overcome these obstacles, better control of catheter movement, more accurate mapping, and an improved safety profile are needed.

### Robotic Magnetic Navigation (RMN)

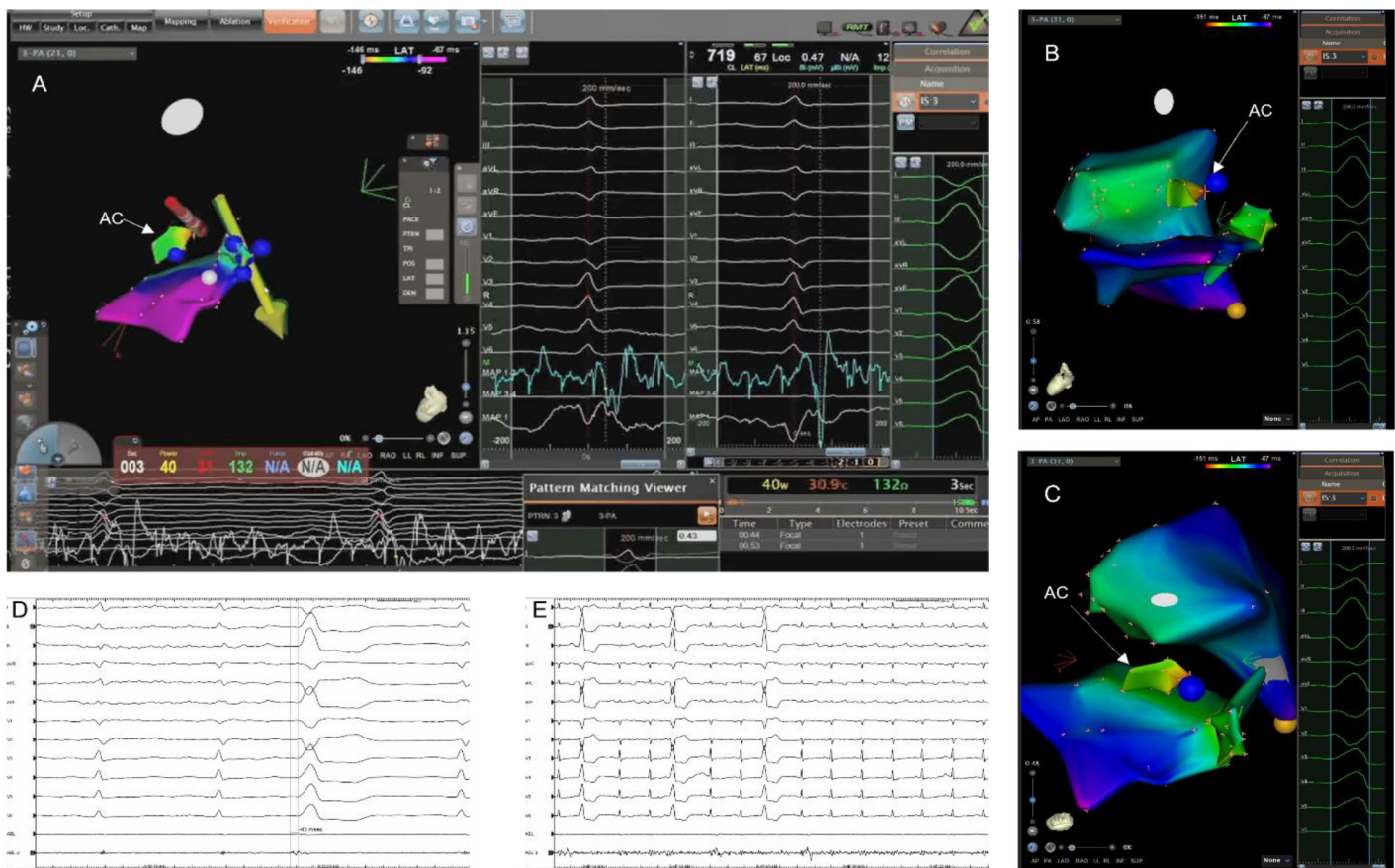
The past two decades have witnessed the development of RMN. Among the several RMN systems developed over time, the Stereotaxis Niobe (Stereotaxis, St. Louis, MO) is the most widely used and reported in clinical studies. The RMN system is composed of two large magnets that generate a magnetic field within the patient's chest. Specially designed magnetically compatible catheters are navigated by tilting, rotating, and moving the magnets to allow for directional movement in three dimensions (3D). Cardiac computed tomography, fluoroscopic images and 3D mapping are fully integrated into the system and operators can control the mapping and ablation process remotely. The delicate magnetic vector steering of ablation and mapping catheters is better suited for the ventricle compared to manual catheters. Manual catheters are often limited by fixed curvatures and pivot points from surrounding cardiac structures, resulting in inconsistent contact. Stable catheter movements during RMN mapping tend to reduce catheter-induced ectopy. Stable tissue-tip contact also creates more durable lesions. These factors can influence the quality of both mapping and ablation of PVCs<sup>6,7</sup>. Continued development of RMN compatible catheters also brought open-irrigated ablation catheters and contact sensing to RMN, expanding its armada to become more popular in

### Key Words

Premature Ventricular Complex; Catheter Ablation; Robotic Magnetic Navigation, Manual Ablation

### Corresponding Author

Luigi Di Biase MD, PhD  
Section Head of Electrophysiology and Director of Arrhythmias Services  
Montefiore-Einstein Center for Heart & Vascular Care  
111 East 210th Street, Bronx, NY 10467.



**Figure 1:** RMN ablation of PVC originating from the anterior cusp (AC) of the pulmonary valve.

The anterior cusp of the pulmonary valve is an anatomical structure difficult to reach by conventional manual ablation catheters but is readily accessible by RMN. This is a case of successful ablation of PVC originating from the AC of pulmonary valve using RMN (A). Activation mapping in the RV and RVOT identified the earliest activation site of PVC is being located in the AC of the pulmonary valve (B), and this site is also confirmed by pattern matching in intracardiac electrogram showing 43ms early activation. Panel B and C show the anatomical location of the AC in Carto reconstruction. Radiofrequency energy is delivered using the magnetic ablation catheter (red catheter in panel A) at 40W resulting in the successful termination of PVC (E).

everyday use. Last but not least, operators experience significantly less fatigue and radiation exposure in more ergonomic seated positions during long cases of PVC ablation especially when intramural origins are suspected or when multi-site ablation is required<sup>8</sup>. This review will explore the pros and cons of using RMN in PVC ablation. Table 1 lists the studies that have reported the use of RMN in PVC ablation.

### PVC Origin and Catheter Access

Catheter ablation of various origins of PVCs using RMN has been reported. The initial studies utilizing RMN in PVC ablation included PVCs originating from both ventricular outflow tracts (RVOT and LVOT)<sup>9-12</sup>. For ablations in the RVOT, the ability to move floppy RMN catheters in small increments within the ventricular space overcomes the inherent difficulty of moving manual catheters limited by curvatures at the right atrium (RA)/ right ventricle (RV) and RV/RVOT junctions. Anatomical structures such as the anterior cusp of the pulmonary valve which can be difficult to reach by manual catheters are easily accessible with the 3D directional movements enabled by RMN (Figure 1). The soft tip of RMN catheters generally produces less contact force (10-20 grams) compared to conventional hard-tipped manual catheters (as much as 100 grams), reducing the likelihood of steam pops and perforations in thin-walled structures like the RV.

Many studies have demonstrated the ability to ablate PVCs in the RV and RVOT with RMN<sup>13-16</sup>. Di Biase et al also demonstrated RMN's maneuverability and capability to perform epicardial mapping/ablation in PVCs and other ventricular arrhythmias (VA) originating from the left ventricle (LV)<sup>10</sup>. In this study, VA ablation (74% PVC) were performed at the left coronary cusp (LCC), aortomitral continuity (AMC), LV septum, LV anterior wall, LV inferior wall, LV apex, coronary sinus, and mitral valve annulus with both antegrade and retrograde approaches<sup>10</sup>. In cases where epicardial access is required, RMN holds a few advantages compared to conventional manual catheters. Unlike manual endocardial catheters requiring torque points for manipulation, magnetic catheters are controlled by the tip and can move more freely within the pericardial space where no torque points are readily available<sup>17</sup>. This evidence demonstrate that RMN might be more suitable for PVC ablations compared to the conventional manual approach.

### Fluoroscopy, Ablation and Procedure Time

One of the most important advantages of RMN over manual ablation is the reduction in fluoroscopy time in ablation of all types of arrhythmias. Specifically for PVC ablations, most studies reported

Table 1:

## Studies of RMN in PVC ablation

Study	Number of PVC patients	PVC origins	Procedure time (min)	Ablation time (min)	Fluoroscopy time (min)	RMN Ablation Catheter	Complications/Safety	Outcomes
Guckel 2021	176 (PVC+VT, 132 PVC)	LVOT, RVOT, LV, RV, multiple origins	206±88	19±24	5±6	3.5mm open-irrigated	9% combined (2%VF, <1% shock, 3% pericardial effusion, 2% tamponade, <1% steampop, <1%RBBB/3AVB, no death)	RMN: 82% combined acute success, 33% PVC recurrence at 5.48y
Li 2020	290 (PVC+VT)	n/a	103.5±64.4	9.4±7.7	3.7±4	3.5mm open-irrigated	0.3% (1 minor unspecified complication)	RMN: 90.3% combined acute success
Li 2021	30 (PVC+VT)	LV, RV	89±38.6	8.8±6.4	4.2±2.4	3.5mm open-irrigated	None	RMN: 93% combined acute success, 4% recurrence at 22.1mo
Xie 2020	65 (PVC+VT)	RVOT	n/a	n/a	n/a	3.5mm open-irrigated	None	RMN: 93.8% combined acute success, 3.3% recurrence at 14.4mo
Xie 2019	15	Parahisian PVCs	n/a	n/a	n/a	3.5mm open-irrigated	None	RMN: 80% acute success, 8% recurrence at 12mo
Dang 2018	43	RVOT, LVOT, RV, LV	96±28	6.7±5.2	3.9±1.9	3.5mm open-irrigated	2% (1 groin hematoma)	RMN:91% acute success 91%, 7% recurrence at 16.2mo
Qiu 2018	64	Outflow tracts, valve annuli	RMN: 129±55 Manual: 130±52	RMN: 12.7±9.4 Manual: 14.2±9.2	RMN: 3.7±3.1 Manual: 12±12.8	3.5mm open-irrigated	None	RMN: 87.5% acute success, 4% recurrence at 16.9mo Manual: 84% acute success, 4% recurrence at 15.8mo
Shauer 2018	42 (PVC+VT)	RVOT	RMN: 113±53 Manual: 116±69	RMN: 7±4.7 Manual: 11.9±16	RMN: 10.9±5.8 Manual: 20.5±13.8	n/a	5% (1 RBBB, 1 hematoma)	RMN: 80% combined acute success, 45% recurrence at 16.9mo Manual: 74% combined acute success, 47% recurrence at 25mo
Kawamura 2017	22 (PVC+VT, 14 PVC)	RVOT, LVOT, RV, LV	RMN: 152±71 Manual: 158±71	n/a	RMN: 19±14 Manual: 34±22	3.5mm open-irrigated (68% in RMN vs 69% in manual ), 4mm non-irrigated	5% (1 hematoma)	RMN: 91% combined acute success, 9% recurrence at 24mo Manual: 69% combined acute success, 10% recurrence at 26mo
Zhang 2013	15 (PVC+VT)	RVOT	RMN: 131.8±19.4 Manual: 115.1±27.4	RMN: 1.1±0.5 Manual: 1.2±0.6	RMN: 5.2±2.6 Manual: 10.5±5.0	4mm non-irrigated	7% (1 RBBB)	RMN: 67% combined acute success, 13% recurrence at 22.1mo Manual: 93% combined acute success
Di Biase 2010	110 (PVC+VT, 84 PVC)	LV only	RMN: 198±66 Manual: 174±72	RMN: 33±18 Manual: 24±12	RMN: 26±14 Manual: 35±33	3.5mm open-irrigated	6% combined (4% VF, 1% CHB, 1% catheter charring, 1% death due to HF)	RMN: 100% combined acute success, 15% recurrence at 11.8mo Manual: 100% combined acute success, 14% recurrence at 18.7mo
Di Biase 2009	65 (PVC+VT)	n/a	276+/-120	n/a	56.8+/-32	4mm, 8mm non-irrigated	3% (2 groin hematoma)	RMN: 52% combined acute success, 85-87% acute success normal heart with RVOT VA 8mm higher success in structural heart disease 59% vs 22% (4mm), 40% recurrence at 12mo
Thornton 2006	3	RVOT only	95-148	2.9-7.3	8.4-13.8	4mm non-irrigated	None	RMN: 100% acute success for PVC, 100% asymptomatic at 1 year follow up

significantly shorter fluoroscopy time<sup>10,12,16,18,19</sup>. The reduction in mean fluoroscopy time was reported from 25% in early studies to close to 70% in later ones<sup>10,19</sup>. This drastic reduction might be related to increased operator confidence that the soft-tip catheters in RMN are less likely to cause myocardial trauma compared to manual catheters. Better catheter stability from robotic arms also reduces the need to reconfirm catheter location with fluoroscopy<sup>20</sup>. Moreover, the RMN platform stores previously utilized vectors and enables catheter navigation along the same vectors without repeat fluoroscopy<sup>21</sup>. Reduced fluoroscopy time not only benefits patients but also operators who are constantly exposed to hazardous radiation.

Early data from Di Biase et al reported longer total procedure time in VA ablation using RMN compared to manual approaches<sup>10</sup>. This study, performed in 2010, included 84 patients (out of 110

patients) in the RMN group undergoing PVC ablation. However, with advancement of the RMN platforms, procedure time in PVC/VT ablations also declined. The introduction of the Vdrive system and the V-SONO module (Stereotaxis, St. Louis, MO) integrated intracardiac echocardiogram (ICE) catheters into the remote process, reducing the need to re-scrub for ICE positioning. More recent studies comparing RMN vs manual ablation in PVC/VT reported comparable total procedure time<sup>16,18,19</sup>. There is also an overall trend of decreasing total procedure time with more experience with the RMN platform. Li et al performed a learning curve analysis of procedure time in patients undergoing atrial fibrillation ablation with RMN. The procedure time decreased along the learning curve and flattened after 300 procedures<sup>22</sup>. The authors can only expect a similar trend in PVC ablations using RMN. This should serve as a confidence booster for operators planning to incorporate RMN in their practice. Only



selected studies reported ablation time in PVC ablation using RMN vs manual approach. Similar to total procedure time, a trend of decreased and more comparable ablation time compared to manual ablations were observed with the introduction of an open irrigated catheter to the RMN platform<sup>10,12,16,19</sup>.

### Efficacy of RMN in PVC Ablation

Most studies to date reported combined efficacy of PVC and VT ablations and has showed promising results. RMN in PVC ablations overall showed comparable if not better acute success and long-term arrhythmia-free rate compared to manual ablations. The first case series by Thornton et al reported successful ablation of all 3 patients with RVOT PVCs using the 4mm RMN ablation catheter. All three patients remained asymptomatic with a mean clinical follow up time of 1 year<sup>9</sup>. However, success rate varied with catheter size and in patients with or without structure heart disease. Di Biase et al reported 85-87% success rate in RMN ablation of RVOT PVC/VT in patients with structurally normal hearts. Acute success decreased significantly in patients with structural heart disease and the 8mm catheters yielded higher efficacy compared to 4mm ones (59% vs 22%)<sup>11</sup>. However, this early study was performed before open irrigated RMN catheters were introduced, which improved lesion formation. Lower maximum contact forces produced by RMN catheter tips can negate the stable catheter-tissue contact and potentially limit lesion formation. The lack of irrigation decreases efficiency of energy delivery due to char formation<sup>20</sup>. This was supported by 10-30% charring observed in this cohort<sup>11</sup>. With the introduction of open-irrigated-tip catheters (OIC) in VA ablation using RMN, the success rate has drastically improved. OIC delivers energy more effectively and produces larger lesions often needed in VA ablation. The same group reported an improved success rate when 3.5mm OIC were introduced the following year<sup>10</sup>. In the 2010 study comparing 110 patients undergoing left sided VA ablation using RMN with 92 patients using manual approach, eighty-four patients presented with PVCs in the RMN group. Overall acute success for RMN was 100% with 15% of patients in the RMN group crossing over to manual ablation. Long term follow-up at 11.8 months in the RMN group showed 85% VA-free rate, comparable to 86% in the manual group at 18.7-month follow up. Unfortunately, the only small randomized controlled trial comparing RMN and manual ablation in VA were performed using traditional 4mm non-irrigated catheters<sup>12</sup>. Combined acute success of PVC/VT ablation was achieved in 67% in the RMN group compared to 93% in the manual group<sup>12</sup>.

Since then, almost all studies using RMN in PVC/VT ablation utilized OICs and acute success rates have improved to 80-94%<sup>14,15,18,19,22-24</sup>. Qiu et al reported a prospective comparison of RMN vs manual ablation in patients only with PVCs<sup>19</sup>. Acute success was achieved in 87.5% in the RMN group compared to 84% in the manual group. At follow up, recurrence rate was similar across the two groups (4% vs 4%). RMN not only achieved a comparable success rate compared to the manual approach at index procedures, it was also shown to be effective in patients with previously failed PVC ablations. The retrospective comparison of RMN vs manual in redo idiopathic VA ablations included 14 patients with PVC (out of 22 PVC and VT patients) in the RMN group<sup>18</sup>. Redo success rate was significantly higher in the RMN group (91%) compared to the manual group

(69%). The stark difference was likely driven by the higher success rate in ablating PVC/VT arising from the posterior RVOT and posterior-basal RV/tricuspid annulus (92% vs 50% success rate). This finding again emphasizes the superior maneuverability and stability in mapping and ablation of difficult anatomical locations as sharp catheter curves are often needed to reach these landmarks<sup>18</sup> (Figure 1). Not unexpectedly, in the prospective cohort by Qiu et al, a trend of higher index ablation success rate of RMN vs manual in PVCs originating from the valve annuli were also observed (91% vs 70%,  $p = 0.162$ )<sup>19</sup>.

### Safety of RMN in PVC Ablation

Very few safety events have been reported with PVC ablations using RMN since its initial utilization. Most studies reported either no complications in patients undergoing PVC ablations using RMN or minor complications such as groin hematoma, transient conduction blocks at low rates from 0.3% to 9%<sup>10,12,13,15,16,18,19,22</sup>. Major complications including ventricular fibrillation, cardiac tamponade, pericardial effusion, shock and patient death were rarely reported in studies when PVC and VT ablation outcomes were combinedly presented in combination<sup>10,13</sup>. In a direct comparison of RMN vs manual ablation in patients with PVC only, no complications were reported in the RMN group while 3 patients suffered from cardiac tamponade in the manual group<sup>19</sup>. Although no meta-analyses of the safety profile of PVC ablations using RMN has been reported, extrapolation of its superior safety compared to manual ablation can be derived from significantly lower rates of complications in VT ablation using RMN (OR 0.35,  $p = 0.0006$ )<sup>21</sup>. The safety of performing PVC ablations with RMN is likely driven by several factors. The soft tip design of RMN ablation catheters delivers lower maximal contact forces, reducing the risk of perforation, steam pops and catheter induced arrhythmias. Better maneuverability and stability also improve mapping accuracy and decrease unexpected catheter movement. In patients with cardiac implanted electronic devices (CIED), a theoretical risk of asynchronous pacing and device dysfunction exists because catheters are maneuvered by 2 large magnets. However, no clinical adverse events resulting from this theoretical risk has been reported<sup>25</sup>.


### Summary

Despite its existence for the past 2 decades, the application of RMN is still limited by cost, perceived steep learning curve and initial technology lag. However, RMN underwent tremendous improvement in technology since its initial use. Through years of application, evidence is pointing towards comparable high success rates at index procedures and superior efficacy at select redo cases involving complex anatomies. Its inherent advantage over conventional manual approaches in treating PVCs such as safer ablation profile and significantly lower fluoroscopy time also cannot be ignored. More centers should consider incorporating RMN in their routine practice of PVC ablation.

### References

1. Nguyen KT, Vittinghoff E, Dewland TA, et al. Ectopy on a Single 12-Lead ECG, Incident Cardiac Myopathy, and Death in the Community. *J Am Heart Assoc.* 2017;6(8).
2. Agarwal SK, Simpson RJ, Jr, Rautaharju P, et al. Relation of ventricular premature complexes to heart failure (from the Atherosclerosis Risk In Communities [ARIC] Study). *Am J Cardiol.* 2012;109(1):105-109.

3. von Rotz M, Aeschbacher S, Bossard M, et al. Risk factors for premature ventricular contractions in young and healthy adults. *Heart*. 2017;103(9):702-707.
4. Cronin EM, Bogun FM, Maury P, et al. 2019 HRS/EHRA/APHRS/LAHRS expert consensus statement on catheter ablation of ventricular arrhythmias. *Heart Rhythm*. 2020;17(1):e2-e154.
5. Romero J, Shivkumar K, Valderrabano M, et al. Modern mapping and ablation techniques to treat ventricular arrhythmias from the left ventricular summit and interventricular septum. *Heart Rhythm*. 2020;17(9):1609-1620.
6. Burkhardt JD. Remote magnetic navigation for ventricular ablation: did the machine win this round? *J Interv Card Electrophysiol*. 2017;48(1):5-7.
7. Tahir SM, Chaudhry GM, Syed MA, et al. Remote magnetic navigation system provides a superior catheter stability in acquisition of His bundle electrogram. *J Interv Card Electrophysiol*. 2008;21(3):209-213.
8. Aagaard P, Di Biase L. . Robotic navigation for catheter ablation: benefits and challenges. . *Expert Rev Med Devices* 2015;12(4):457-469. .
9. Thornton AS, Jordaens LJ. Remote magnetic navigation for mapping and ablating right ventricular outflow tract tachycardia. *Heart Rhythm*. 2006;3(6):691-696.
10. Di Biase L, Santangeli P, Astudillo V, et al. Endo-epicardial ablation of ventricular arrhythmias in the left ventricle with the Remote Magnetic Navigation System and the 3.5-mm open irrigated magnetic catheter: results from a large single-center case-control series. *Heart Rhythm*. 2010;7(8):1029-1035.
11. Di Biase L, Burkhardt JD, Lakkireddy D, et al. Mapping and ablation of ventricular arrhythmias with magnetic navigation: comparison between 4- and 8-mm catheter tips. *J Interv Card Electrophysiol*. 2009;26(2):133-137.
12. Zhang F, Yang B, Chen H, et al. Magnetic versus manual catheter navigation for mapping and ablation of right ventricular outflow tract ventricular arrhythmias: a randomized controlled study. *Heart Rhythm*. 2013;10(8):1178-1183.
13. Guckel D, Niemann S, Ditzhaus M, et al. Long-Term Efficacy and Impact on Mortality of Remote Magnetic Navigation Guided Catheter Ablation of Ventricular Arrhythmias. *J Clin Med*. 2021;10(20).
14. Xie Y, Liu A, Jin Q, et al. Novel strategy of remote magnetic navigation-guided ablation for ventricular arrhythmias from right ventricle outflow tract. *Sci Rep*. 2020;10(1):17839.
15. Dang S, Jons C, Jacobsen PK, Pehrson S, Chen X. Feasibility of a novel mapping system combined with remote magnetic navigation for catheter ablation of premature ventricular contractions. *J Arrhythm*. 2019;35(2):244-251.
16. Shauer A, De Vries LJ, Akca F, et al. Clinical research: remote magnetic navigation vs. manually controlled catheter ablation of right ventricular outflow tract arrhythmias: a retrospective study. *Europace*. 2018;20(suppl\_2):ii28-ii32.
17. Burkhardt JD, Di Biase L, Horton R, Schweikert RA, Natale A. Remote Navigation and Electroanatomic Mapping in the Pericardial Space. *Card Electrophysiol Clin*. 2010;2(1):121-125.
18. Kawamura M, Scheinman MM, Tseng ZH, Lee BK, Marcus GM, Badhwar N. Comparison of remote magnetic navigation ablation and manual ablation of idiopathic ventricular arrhythmia after failed manual ablation. *J Interv Card Electrophysiol*. 2017;48(1):35-42.
19. Qiu X, Zhang N, Luo Q, et al. Remote magnetic navigation facilitates the ablations of frequent ventricular premature complexes originating from the outflow tract and the valve annulus as compared to manual control navigation. *Int J Cardiol*. 2018;267:94-99.
20. Aagaard P, Natale A, Briceno D, et al. Remote Magnetic Navigation: A Focus on Catheter Ablation of Ventricular Arrhythmias. *J Cardiovasc Electrophysiol*. 2016;27 Suppl 1:S38-44.
21. Turagam MK, Atkins D, Tung R, et al. A meta-analysis of manual versus remote magnetic navigation for ventricular tachycardia ablation. *J Interv Card Electrophysiol*. 2017;49(3):227-235.
22. Li X, Jin Q, Zhang N, et al. Procedural outcomes and learning curve of cardiac arrhythmias catheter ablation using remote magnetic navigation: Experience from a large-scale single-center study. *Clin Cardiol*. 2020;43(9):968-975.
23. Li X, Shang W, Zhang N, et al. Remote magnetic-guided ablation for three origins of idiopathic ventricular arrhythmias with right bundle branch block and superior axis. *Clin Cardiol*. 2021;44(3):379-385.
24. Xie Y, Jin Q, Zhang N, et al. Strategy of catheter ablation for para-Hisian premature ventricular contractions with the assistance of remote magnetic navigation. *J Cardiovasc Electrophysiol*. 2019;30(12):2929-2935.
25. Luthje L, Vollmann D, Seegers J, Sohns C, Hasenfuss G, Zabel M. Interference of remote magnetic catheter navigation and ablation with implanted devices for pacing and defibrillation. *Europace*. 2010;12(11):1574-1580.



## Remote Magnetic versus Manual Catheter Navigation in the Ablation of Accessory Pathways in Adults

Gregory P. Siroky<sup>1,2,\*</sup>, Ameesh Isath<sup>3,4,\*</sup>, Hieu Huynh<sup>2</sup>, Mena Yacoub<sup>2</sup>, Asad Mohammad<sup>2</sup>, Seth Keller<sup>2</sup>, Ranjit Suri<sup>2</sup>, Patrick Lam<sup>2</sup>, Davendra Mehta<sup>2</sup>

<sup>1</sup>St. Francis Hospital and Heart Center, Arrhythmia Center, Roslyn, NY

<sup>2</sup>Department of Cardiology, Division of Electrophysiology, Mount Sinai Morningside, Icahn School of Medicine at Mount Sinai, New York, NY

<sup>3</sup>Department of Medicine, Mount Sinai Morningside and West, Icahn School of Medicine at Mount Sinai, New York, NY

<sup>4</sup>Department of Cardiology, Westchester Medical Center, New York Medical College, Valhalla, NY

\*Dr. Siroky and Dr. Isath contributed equally to this manuscript

### Abstract

**Introduction:** There is a paucity of data comparing remote magnetic navigation (RMN) to manual catheter navigation (MCN) in the ablation of accessory pathways (AP) in adult patients.

**Methods:** A retrospective analysis of AP ablations performed in adults (>18 years old) at our institution was conducted from January 2015 to June 2020.

**Results:** Over the five-and-a-half-year study period, there were 114 patients with a total of 132 APs ablated. Of the 114 patients, 14 required a second ablation and 2 required a third ablation. Of the 132 AP ablations, 114 were performed using MCN and 18 were performed using RMN. The mean age among all patients was  $38.1 \pm 14.5$  years ( $p = 0.984$ ) with 53.8% being male ( $p = 0.172$ ). Mean follow up was  $459.9 \pm 435.4$  days with no statistical difference between groups. The acute success of all ablations was 84.1% (111/132) with a significant difference in favor of the RMN group (100% vs 81.6%;  $p = 0.047$ ). Number of lesions (RMN 12, IQR 5-17 vs MCN 7.5, IQR 3-13;  $p = 0.016$ ), ablation time (RMN 368 sec, IQR 215-572 vs MCN 259 sec, IQR 133.5-461.25;  $p = 0.031$ ), and procedure time (RMN 230.89  $\pm$  79.42 vs MCN 183.26  $\pm$  64.88;  $p = 0.006$ ) as well as the cost per procedure (RMN \$8,915  $\pm$  \$2,552.11 vs MCN \$6,675.35  $\pm$  \$1,737.31;  $p = 0.001$ ) were all significantly higher in the RMN group compared to the MCN group. Of the redo ablations, 100% (6/6) were successful using RMN while only 83.3% (10/12) were successful using MCN.

**Conclusion:** Compared to manual navigation, remote magnetic navigation was more successful in first time and redo accessory pathway ablations.

### Introduction

Ablation of cardiac arrhythmias requires precise manipulation and stability of the ablation catheter at the area of interest for success. A particular challenge which may arise with manually navigated/

### Key Words

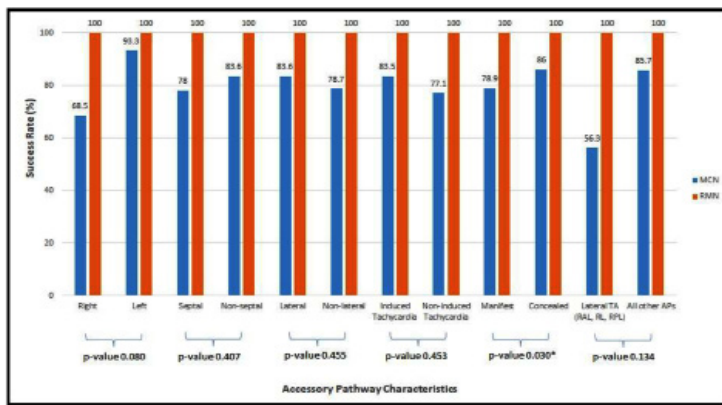
Accessory Pathway, Wolf-Parkinson-White Syndrome, Atrioventricular Reciprocating Tachycardia, Manual Navigation

### Corresponding Author

Gregory P. Siroky,  
St. Francis Hospital and Heart Center  
Arrhythmia Center 100 Port Washington Boulevard Roslyn, NY 11576

manipulated catheters includes lack of stability in certain areas of the heart. In addition, complications as a result of manipulating a relatively stiff, deflectable catheter can occur which include hematoma, thrombotic events, atrioventricular block/conduction system damage, and cardiac perforation<sup>1</sup>. The introduction of the Niobe system (Stereotaxis, Inc., St. Louis, MO), a remote magnetic navigation (RMN) system, using a soft tipped catheter ameliorated many of these potential risks and complications. It uses a motor drive advancement system (Cardiodrive) to manipulate/navigate the ablation catheter in a remotely controlled directional magnetic field. The safety and feasibility of using this system has been demonstrated very thoroughly.<sup>2,3,4</sup> RMN has been shown to be safe and effective in the ablation of all cardiac





**Figure 1:** Success rates between remote and manual catheter navigation based on specific AP characteristics.

MCN = manual catheter navigation; RMN = remote magnetic navigation; TA = tricuspid annulus; AP = accessory pathway.

arrhythmias, including atrial fibrillation<sup>5,6,7</sup>, ventricular tachycardia<sup>8,9</sup>, and supraventricular tachycardias (SVT)<sup>1,4,7</sup>.

Atrioventricular (AV) accessory pathways (AP) can be challenging to ablate as there tends to be less stability of the catheter tip at the level of the tricuspid and mitral valve annuli. RMN has been shown to be safe and effective in the ablation of APs in adults<sup>1,10,11</sup> and children<sup>12</sup>, but there is a paucity of data comparing the success of this modality of navigation to conventional manual catheter navigation (MCN) in adults. We therefore aim to elucidate the success of RMN compared to MCN in the ablation of APs in adults by performing a retrospective analysis of data at our institution.

## 2. Methods

### 2.1 Data Collection

A retrospective collection of data from our electronic medical records on all AP ablations was performed at our institution. Patient records were reviewed with the approval of the Institutional Review Board at Mount Sinai Morningside Hospital. Patients over the age of 18 who underwent ablation of an AP between January 2015 and June 2020 were included in the data analysis. All first time and redo ablations were included as well. Manifest APs were identified from the surface ECG and concealed APs during electrophysiology study. Demographic and procedural data including patient age, gender, co-morbidities, AP location, AP characteristics, procedure time, ablation time, fluoroscopy time, acute procedural success, acute complications, and the navigation modality was collected.

### 2.2 Procedure Description

Patients underwent electrophysiology study and ablation via femoral access under conscious sedation. Quadripolar catheters (Abbott, St Paul, MN) were placed in the high right atrium, His, and right ventricular apical positions. A deflectable decapolar catheter was placed in the coronary sinus (Bard Electrophysiology, Lowell, MA or Biosense Webster, Diamond Bar, CA). Ablation catheters were driven either remotely via a magnetically tipped catheter or manually. RMN was performed using the Niobe system (Stereotaxis, St. Louis, MO). This system consists of two laterally placed magnets that apply a 0.08-0.10 Tesla magnetic field across the patient and a separate drive system

which advances and retracts the catheter (Cardiodrive, Stereotaxis, St. Louis, MO). Magnetic elements in the catheter tip cause the catheter to align and be steered by the magnetic field<sup>4</sup>. MCN ablation was performed with conventional hand-held, deflectable, open irrigated, uni- or bidirectional, ablation catheters. Both RMN and MCN ablation were performed with the use of an electroanatomic mapping (EAM) system (CARTO 3, Biosense Webster, Diamond Bar, CA or EnSite NavX (Abbott, St. Paul, MN). The choice of navigation modality (magnetic or manual) was left to the discretion of the operator.

### 2.3 Ablation and Catheters

Ablation was performed at 30-40 W maximum for up to 60-120 seconds per lesion using a 3.5mm tip open-irrigated catheter (Navistar Thermocool RMT) for RMN and Smart Touch Thermocool (Biosense Webster, Diamond Bar, CA) or TactiCath (EnSite NavX, Abbott, St. Paul, MN) for MCN.

### 2.4 Procedural Endpoint

Procedural success was defined as the absence of antegrade and/or retrograde AP conduction on repeat electrophysiology testing after a 30-minute waiting period at the conclusion of ablation as well as freedom from repeat ablation.

### 2.5 Statistics

Cases were stratified by navigation type and analyzed for potential differences in total procedure time, ablation time, fluoroscopy time, and acute procedural success. Statistical analysis was performed using SPSS ver. 23 (SPSS Inc.). Continuous data is presented as mean with standard deviations or median with interquartile range. Categorical data is presented as frequency of occurrence "N" with percentage. Comparison of continuous data was performed using the unpaired two-tailed Student's t-test or the Mann-Whitney test for normally and non-normally distributed data, respectively. Chi-Square or Fisher's exact test analysis was performed to determine the relationship between categorical variables as appropriate. A 'p value' ≤ 0.05 was deemed as statistically significant.

**Table 1:** Patient demographic and medical characteristics.

Variable	All Patients	RMN	MCN	p-value
Age (Median, IQR)	34 (26-50)	32 (26.5-52)	36.5 (26-50.3)	0.984
Gender, Male (N, %)	71 (53.8%)	7 (38.9%)	64 (56.1%)	0.172
HTN (N, %)	32 (24.2%)	1 (5.6%)	31 (27.2%)	0.045*
HLD (N, %)	23 (17.4%)	1 (5.6%)	22 (19.3%)	0.153
CAD (N, %)	4 (3%)	0 (0%)	4 (3.5%)	0.420
EF % (Median, IQR)	60 (56-60)	57.5 (48.75-60)	60 (60-60)	0.080
Prior Arrhythmias (N, %)	17 (12.9%)	5 (27.8%)	12 (10.5%)	0.048*
Prior Ablation (N, %)	35 (26.5%)	12 (66.7%)	23 (20.2%)	0.0001*
DM (N, %)	12 (9.1%)	0 (0%)	12 (10.5%)	0.149
CKD (GFR<60) (N, %)	3 (2.3%)	0 (0%)	3 (2.6%)	0.489
COPD/Asthma (N, %)	8 (6.1%)	1 (5.6%)	7 (6.1%)	0.923

RMN = remote magnetic navigation; MCN = manual catheter navigation; HTN = hypertension; HLD = hyperlipidemia; CAD = coronary artery disease; EF = ejection fraction; DM = diabetes mellitus; CKD = chronic kidney disease; COPD = chronic obstructive pulmonary disease.

**Table 2: Distribution of patient symptoms.**

Symptom	All Patients	RMN	MCN	p-value
Palpitations (N, %)	126 (95.5%)	17 (94.4%)	109 (95.6%)	0.825
Chest pain/discomfort (N, %)	32 (24.2%)	5 (27.8%)	27 (23.7%)	0.706
Dyspnea (N, %)	19 (14.4%)	2 (11.1%)	17 (14.9%)	0.669
Syncope (N, %)	10 (7.6%)	2 (11.1%)	8 (7.0%)	0.542
Dizziness (N, %)	30 (22.7%)	5 (27.8%)	25 (21.9%)	0.582
Other * (N, %)	6 (4.5%)	1 (5.6%)	5 (4.4%)	0.212

RMN = remote magnetic navigation; MCN = manual catheter navigation.  
 \* Other symptoms - nausea, vomiting, weakness, diaphoresis.

**3. Results**

**3.1 Patients**

Over the five-and-a-half-year study period, 114 patients underwent ablation of their APs with a total of 132 APs ablated (includes redo ablations). Of the 114 patients, 14 required a second ablation and 2 required a third ablation. Of the 132 AP ablations, 114 were performed using MCN and 18 were performed using RMN. The mean age among all patients was 38.1 ± 14.5 years with 53.8% male and without a significant difference between the 2 groups (p = 0.984 and 0.172, respectively) (Table 1). Mean follow up was 459.9 ± 435.4 days with no statistical difference between groups. Regarding co-morbidities (HLD, CAD, DM, COPD/asthma, CKD), there were no significant differences between the two groups except for hypertension in which the MCN was significantly higher (27.2% vs 5.6%; p = 0.045). In addition, there was no significant difference between the groups with respect to ejection fraction (p = 0.080). As a majority of the RMN group underwent redo ablations, there was a significant difference between prior arrhythmias (27.8% vs 10.52%; p = 0.048) and prior ablations (66.7% vs 20.2%; p = 0.0001) when compared to the MCN group.

**3.2 Symptoms**

Symptoms reported by patients included palpitations, chest pain/discomfort, dyspnea, pre-syncope/syncope, dizziness, nausea/vomiting, diaphoresis, and weakness. There was no significant difference between groups for any symptom (table 2).

**3.3 Accessory Pathway Characteristics**

Of the 132 APs, 67 (50.76%) were left sided and there was no significant difference between the RMN and MCN group (38.9% vs 52.63%; p = 0.278). In addition, there was no difference in manifest pre-excitation (66.7% vs 62.3%; p = 0.720). Most of the ablations were performed using the CARTO electroanatomic mapping system (97.7%)(table 3). Figure 1 displays success rates between navigation types based on certain AP characteristics. There was a trend towards higher success of ablating APs using RMN around the tricuspid annulus (100% vs 68.5%) as well as for lateral tricuspid annulus APs compared to all other APs (100% vs 56.3%). There was a statistically significant difference found in favor of RMN when comparing ablation of manifest and concealed APs (p = 0.030).

**3.4 Procedural Characteristics**

Accessory pathway success rates by location and navigation type are displayed in figure 2. The acute success of all ablations was 84.1% (111/132) with a significant difference in favor of the RMN group

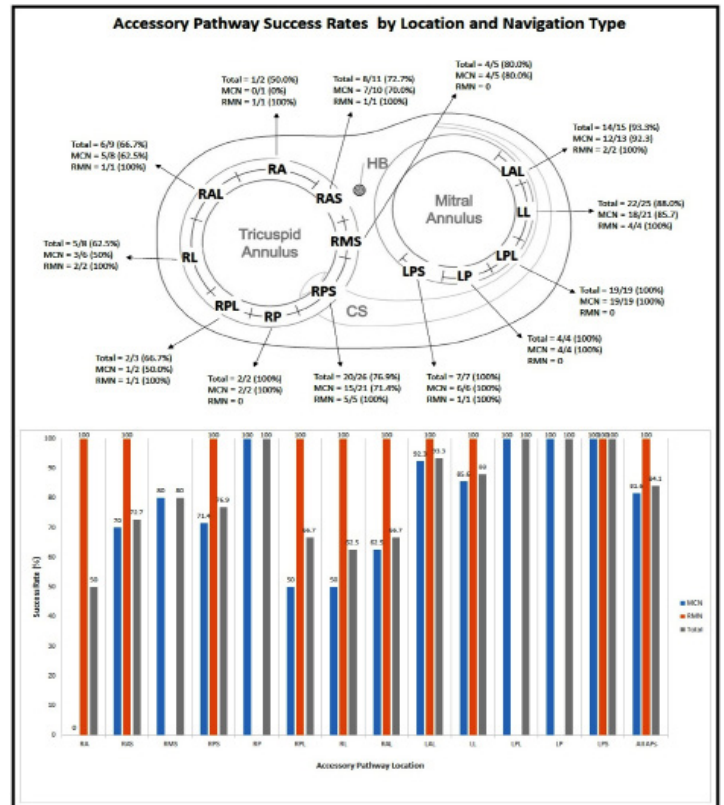
(100% vs 81.6%; p = 0.047). The number of lesions given (RMN 12, IQR 5-17 vs MCN 7.5, IQR 3-13; p = 0.016), ablation time (RMN 368 sec, IQR 215-572 vs MCN 259 sec, IQR 133.5-461.25; p = 0.031), and procedure time RMN (230.89 ± 79.42 vs MCN 183.26 ± 64.88; p = 0.006) were all significantly higher in the RMN group compared to the MCN group. In addition, the cost per procedure (RMN \$8,915 ± \$2,552.11 vs MCN \$6,675.35 ± \$1,737.31; p = 0.001) was significantly more expensive for the RMN compared to the MCN group (table 4). Lastly, there were no complications in either group.

**3.5 Redo Ablations**

There was a total of 18 redo ablations. 100% (6/6) were successful using RMN while only 83.3% (10/12) were successful using MCN. In addition, the redo RMN cases were shorter in duration (195.3 min ± 61.4 min) as compared to the de novo RMN cases (248.7 min ± 83.7 min).

**Discussion**

This study specifically compares acute success rates of accessory pathway ablations in adults between RMN and MCN. The main finding is that the acute success rate of AP ablations in adults is higher when utilizing RMN compared to MCN, however, RMN was associated with a larger number of lesions given, higher ablation times, and higher cost.



**Figure 2: Accessory pathway success rates by location and navigation type.**

HB = His bundle; CS = coronary sinus; RAL = right anterolateral; RA = right anterior; RAS = right anteroseptal; RMS = right mid septal; RPS = right posteroseptal; RP = right posterior; RPL = right posterolateral; RL = right lateral; LAL = left anterolateral; LL = left lateral; LPL = left posterolateral; LP = left posterior; LPS = left posteroseptal.

One of the major advantages of a magnetically driven ablation catheter system, aside from a reduction in major complications due to its flexible, nontraumatic design, is its increased stability, specifically on highly mobile and precise locations within the heart. Davis et al. suggested increased stability of RMN in comparison to MCN based on lower mean temperature, earlier time to junctional tachycardia, and less variability of temperature when ablating the slow pathway in atrioventricular reentrant tachycardia (AVNRT)<sup>13</sup>. Similarly, in a case report by the same authors, they demonstrated better precision and stability of RMN in ablation of a concealed parahisian AP which was previously unsuccessful using MCN<sup>14</sup>. Ernst et al. also reported their success in the mapping and ablation of two parahisian APs when utilizing RMN<sup>10</sup>.

Two prior studies have compared RMN to MCN in the ablation of SVTs, including AVNRT, atrioventricular reciprocating tachycardia (AVRT)/Wolf-Parkinson-White syndrome, and atrial tachycardia<sup>15, 16</sup>. Woods et al. analyzed a total of 17 AP ablations, 5 via MCN and 12 via RMN, without a significant difference in acute success<sup>15</sup>. Similarly, Kim et al. presented results of 33 AP ablations (7 via MCN and 26 via RMN) with only a difference (non-statistically significant) in success among right free wall APs<sup>16</sup>, akin to our findings. Additionally, in a recent publication by Noten et al, they observed a higher long term success rate in the ablation of AVNRT and AVRT using RMN compared to MCN in a pediatric population<sup>17</sup>.

Right free wall/lateral APs have been shown to have the worst ablation outcomes via conventional, manual ablation due to anatomic features of the tricuspid annulus<sup>16, 18</sup>. As such, the increased stability of the magnetically driven catheter on the highly mobile tricuspid and mitral annuli could be responsible for improved acute success rates with RMN, in not only right lateral APs but all APs ablation. Related to easy maneuverability RMN catheter is specifically useful when ablation is to be performed on the ventricular side of accessory pathway under the mobile tricuspid leaflets.

We attempted to elucidate any potential AP characteristics that would predict an increased rate of success based on navigation type. We demonstrated that the ablation of APs with manifest pre-excitation was statistically associated with an increased rate of success. One potential explanation is that manual manipulation of the ablation catheter increases the risk of mechanical trauma to the AP, thereby increasing the risk of failure<sup>19</sup>. Additionally, An aforementioned factor which increases the acute success rate when using RMN is location of the AP, specifically on the lateral aspect of the tricuspid annulus, as the flexibility/maneuverability of the magnetic catheter allows the operator to easily position it underneath the tricuspid valve if needed for greater stability.

Previous studies have reported a reduction in fluoroscopy times, ablation times, and lesions delivered when using RMN for ablation<sup>12, 15, 20</sup>. We showed no difference in the amount of fluoroscopy used, but a higher number of lesions delivered and increased ablation time. Increased procedure time in the RMN group compared to the MCN group is likely related to longer ablation times for prior failed procedures requiring more detailed mapping for pathway locations and often attempting to ablate the right sided pathways under the

tricuspid valve. Among the RMN group, procedure times of the de novo ablations were longer than the redo ablations, likely as a result of the more detailed electrophysiology study in the de novo cases.

Finally, using RMN for AP ablations was statistically more expensive in comparison to MCN. The added cost of the procedure comes from the drive system used to manipulate the magnetic catheter as well as the costs inherent of the stereotaxis system. There were a total of 18 repeat ablations, all of which were failed MCN ablations, and ultimately cost the hospital system more than if the initial ablation performed was successful. It can be stipulated that if RMN was the initial navigation modality utilized, then repeat ablations would not have been required given the analyzed success rate thus leading to an overall lower cost.

There are a few limitations in the current analysis. Firstly, the small number of RMN cases that were performed during the study period. Secondly, due to the retrospective design of the study, there are inherent challenges in data collection, relying solely on documentation of the performing physician(s) as well as lack of randomization in each group. Lastly, as discussed by Kim et al (12), experience discrepancies amongst fellows, supervised by attending physicians, based on navigation modalities are not accounted for affecting success rates, despite likely improvement over time with resultant higher success rates.

## Conclusion

To our knowledge, this is the first relatively large study specifically comparing acute success rates between RMN and MCN in the ablation of accessory pathway in adults. We demonstrate that the acute success rate of AP ablations in adults was higher when utilizing RMN compared to MCN.

**Table 3: Accessory pathway characteristics.**

	All Patients	RMN	MCN	p-value
<b>AP Sidedness- left; (N, %)</b>	67 (50.76%)	7 (38.9%)	60 (52.63%)	0.278
<b>Baseline Pre-excitation (manifest AP); (N, %)</b>	83 (62.9%)	12 (66.7%)	71 (62.3%)	0.720
<b>AP Conduction</b>				
<b>Antegrade (N, %)</b>	29 (22.0%)	5 (27.8%)	24 (21.1%)	0.476
<b>Retrograde (N, %)</b>	46 (34.8%)	7 (38.9%)	39 (34.2%)	
<b>Both (N, %)</b>	56 (42.4%)	5 (27.8%)	51 (44.7%)	
<b>EAM System</b>				
<b>CARTO (N, %)</b>	129 (97.7%)	18 (100%)	111 (97.4%)	0.486
<b>NAVX (N, %)</b>	3 (2.3%)	0 (0.0%)	3 (2.6%)	
<b>Inducible tachycardia</b>				
<b>ORT (N, %)</b>	74 (56.1%)	8 (44.4%)	66 (57.9%)	0.213
<b>ART (N, %)</b>	6 (4.5%)	0 (0.0%)	6 (5.3%)	
<b>Both (N, %)</b>	7 (5.3%)	0 (0.0%)	7 (6.1%)	
<b>TCL (ms); (Mean±SD)</b>	332.47 ± 54.851	328.25 ± 54.631	332.96 ± 55.25	0.820

RMN = remote magnetic navigation; MCN = manual catheter navigation; SD = standard deviation; AP = accessory pathway; EAM = Electroanatomical mapping; ORT = orthodromic reciprocating tachycardia; ART = antidromic reciprocating tachycardia; ERP = effective refractory period; FRP = functional refractory period; TCL = tachycardia cycle length

## References

1. Chun J, Ernst S, Matthews S, et al. Remote-controlled catheter ablation of accessory pathways: results from the magnetic laboratory. *Eur Heart J*. 2007; 28(2): 190-195.
2. Faddis M, Blume W, Finney J, et al. Novel, Magnetically guided catheter for endocardial mapping and radiofrequency catheter ablation. *Circulation* 2002; 106(23): 2980-2985.



**Table 4: Procedural characteristics.**

	All Patients	RMN	MCN	p-value
<b>Ablation energy, RF (N, %)</b>	<b>129 (97.7%)</b>	<b>18 (100%)</b>	<b>111(97.4%)</b>	<b>0.785</b>
<b>Number of lesions; Median (IQR)</b>	<b>8 (4-14)</b>	<b>12 (5-17)</b>	<b>7.5 (3-13)</b>	<b>0.016*</b>
<b>Ablation time (sec); Median (IQR)</b>	<b>266 (149-506)</b>	<b>368 (215-572)</b>	<b>259 (133.5-461.25)</b>	<b>0.031*</b>
<b>Fluoroscopy time (min); Median (IQR)</b>	<b>15.3 (10-27.15)</b>	<b>19.3 (9.42-42.8)</b>	<b>15 (10.3-25.5)</b>	<b>0.403</b>
<b>Procedure time (min) (Mean ± SD)</b>	<b>189.76 ± 68.69</b>	<b>230.89 ± 79.42</b>	<b>183.26 ± 64.88</b>	<b>0.006*</b>
<b>Cost (\$) (Mean ± SD)</b>	<b>6,968.22 ± 2,000.73</b>	<b>8,915 ± 2,552.11</b>	<b>6,675.35 ± 1,737.31</b>	<b>0.0001*</b>
<b>Redo Ablations Performed#</b>	<b>18/132 (13.6%)</b>	<b>6/18 (33.3%)</b>	<b>12/18 (66.7%)</b>	<b>0.75</b>
<b>Time to Redo ablation (days)</b>	<b>224.5 ± 312.9</b>	<b>0</b>	<b>224.5 ± 312.9</b>	<b>-</b>
<b>Lost to follow up\$</b>	<b>53/132 (40.2%)</b>	<b>10/53 (18.9%)</b>	<b>43/53 (81.1%)</b>	<b>0.120</b>
<b>Follow-up after initial/last ablation (days)*</b>	<b>459.9 ± 435.4 (10 - 1876)</b>	<b>372.0 ± 398.9 (10 - 1015)</b>	<b>472.0 ± 442.5 (22 - 1876)</b>	<b>0.714</b>
<b>Acute Success of Redo Ablations</b>	<b>16/18 (88.9%)</b>	<b>6/6 (100%)</b>	<b>10/12 (83.3%)</b>	<b>0.289</b>
<b>Complications</b>	<b>0 (0)</b>	<b>0 (0)</b>	<b>0 (0)</b>	<b>1.00</b>
<b>Acute success (N, %)</b>	<b>111/132 (84.1%)</b>	<b>18/18 (100%)</b>	<b>93/114 (81.6%)</b>	<b>0.047*</b>

RMN = remote magnetic navigation; MCN = manual catheter navigation; IQR = interquartile range; SD = standard deviation; RF = radiofrequency.

# Redo ablations performed via the specific navigation type.


\$ Number of patients lost to follow up after initial or redo ablation (only seen the day after ablation).

\*Follow up = ≥ 7 days. Does not include patients lost to follow up and first and/or second ablation of patients who underwent redo ablations. Number in parentheses represents the range.

- Faddis M, Chen J, Osborn J, et al. Magnetic guidance system for cardiac electrophysiology: a prospective trial of safety and efficacy in humans. *J Am Coll Cardiol* 2003; 42: 1952-1958.
- Ernst S, Ouyang F, Linder C, et al. Initial Experience with remote catheter ablation using a novel magnetic navigation system. *Circulation* 2004. 109: 1472-1475.
- Virk S, Kumar S. Remote magnetic versus manual catheter navigation for atrial fibrillation ablation: A meta-analysis. *Circ ArrhythmElectrophysiol* 2019; 12(10):
- Jia K, Jin Q, Liu A, et al. Remote magnetic navigation versus manual control navigation for atrial fibrillation: a systematic review and meta-analysis. *J Electrocardiol* 2019; 55: 78-86.
- Nolker G, Gutleben KJ, Muntean B, et al. Novel robotic catheter manipulation system integrated with remote magnetic navigation for fully remote ablation of atrial arrhythmias: a two-centre evaluation. *Europace* 2012; 14(12): 1715-1718.
- Aryana A, d'Avila A, Heist EK, et al. Remote magnetic navigation to guide endocardial and epicardial catheter mapping of scar-related ventricular tachycardia. *Circulation* 2007. 115; 1191-1200.
- Di Biase L, Burkhardt JD, Lakkireddy D, et al. Mapping and ablation of ventricular arrhythmias with magnetic navigation: comparison between 4- and 8-mm catheter tips. *J Interv Card Electrophysiol* 2009; 26: 133-137.
- Ernst S, Hachiya H, Chun J, et al. Remote catheter ablation of parahisian accessory pathways using a novel magnetic navigation system – a report of two cases. *J Cardiovasc Electrophysiol*. 2005; 16(6): 659-662.
- Zivin A. Ablation of a Mahaim Accessory pathway using remote magnetic navigation after recurrence following conventional ablation and mapping. *EP Lab Digest* 2015; 15(1).
- Kim J, Macicek S, Decker J, et al. Magnetic versus manual catheter navigation for

ablation of free wall accessory pathways in children. *Circ ArrhythmElectrophysiol* 2012; 5(4): 804-808.

- Davis DR, Tang A, Gollob M, et al. Remote Magnetic Navigation-Assisted catheter ablation enhances catheter stability and ablation success with lower catheter temperatures. *PACE* 2008; 31: 893-898.
- Davis DR, Tang A, Birnie D, et al. Successful ablation of a concealed parahisian accessory pathway using a remote magnetic navigation system following failure by conventional methods. *J Interv Card Electrophysiol* 2006; 16: 149-151.
- Wood MA, Orlov M, Ramaswamy K, Haffajee C, Ellenbogen K; Stereotaxis Heart Study Investigators. Remote magnetic versus manual catheter navigation for ablation of supraventricular tachycardias: a randomized, multicenter trial. *Pacing Clin Electrophysiol*. 2008;31: 1313-1321.
- Kim SH, Oh YS, Kim DH, et al. Long-term outcomes of remote magnetic navigation for ablation of supraventricular tachycardias. *J Interv Card Electrophysiol* 2015; 43: 187-192.
- Noten A, Kammeraad J, Misier N, et al. Remote magnetic navigation shows superior long-term outcomes in pediatric atrioventricular (nodal) tachycardia ablation compared to manual radiofrequency and cryoablation. *Int J Cardiol Heart Vasc*. 2021 Oct 1;37:100881. doi: 10.1016/j.ijcha.2021.100881. PMID: 34646933; PMCID: PMC8495098
- Chen, M. L., Yang, B., Ju, W. Z., Chen, H. W., Chen, C., Hou, X. F., et al. (2010). Right-sided free wall accessory pathway refractory to conventional catheter ablation: lessons from 3-dimensional electroanatomic mapping. *Journal of Cardiovascular Electrophysiology*, 21(12), 1317-1324.
- Belhassen B, Viskin S, Fish R, et al. Catheter-induced mechanical trauma to accessory pathways during radiofrequency ablation: incidence, predictors, and clinical implications. *J Am Coll Cardiol* 1999; 33: 767-774.
- Bauernfeind T, Akca F, Schwagten B, de Groot N, Van Belle Y, Valk S, Ujvari B, Jordaens L, Szili-Torok T. The magnetic navigation system allows safety and high efficacy for ablation of arrhythmias. *Europace*. 2011;13:1015-1021



### Outcomes of Remote Magnetic Navigation in SVT Ablation

Krishna Akella<sup>1</sup>, Rahul Doshi<sup>2</sup>, Parker Lavigne<sup>1</sup>, Rohan Trivedi<sup>1</sup>, Sunil Pathak<sup>1</sup>, Lydia Taranto<sup>1</sup>, Juan Siordia<sup>1</sup>, Adnan Ahmed<sup>3</sup>, Mayank Sardana<sup>4</sup>, David Riggio<sup>4</sup>, Kethes Waram<sup>5</sup>, Jamie Howard<sup>6</sup>, Zoya Ahmad<sup>7</sup>, Adam Sabbath<sup>8</sup>, Nikhil Iyengar<sup>9</sup>, David Rizik<sup>10</sup>, Dhanunjaya Lakkireddy<sup>11</sup>, J.Peter Weiss<sup>12</sup>

<sup>1</sup> Cardiovascular Disease Fellow, HonorHealth, Scottsdale, AZ, USA

<sup>2</sup> Pillar Chief of Electrophysiology and Arrhythmia Services, HonorHealth, Scottsdale, AZ, USA

<sup>3</sup> Arrhythmia Research Fellow, Kansas City Heart Rhythm Institute (KCHRI), Overland Park, KS, USA

<sup>4</sup> Attending Physician, Electrophysiology, HonorHealth, Scottsdale, AZ, USA

<sup>5</sup> Attending Physician, Interventional Cardiology, Cardiovascular Consultants Ltd., Scottsdale, AZ, USA

<sup>6</sup> Nurse Practitioner, Electrophysiology, HonorHealth, Scottsdale, AZ, USA

<sup>7</sup> Physician Assistant, Electrophysiology, HonorHealth, Scottsdale, AZ, USA

<sup>8</sup> Medical Director, HonorHealth Heart Institute, Scottsdale, AZ, USA

<sup>9</sup> Cardiovascular Disease Program Director, HonorHealth, Scottsdale, AZ, USA

<sup>10</sup> Chief Scientific Officer and Director of Structural Heart and Coronary Interventions, HonorHealth, Scottsdale, AZ, USA

<sup>11</sup> Executive Medical Director, Kansas City Heart Rhythm Institute (KCHRI), Overland Park, KS, USA

<sup>12</sup> Director of the Cardiac Interventions Center, Banner University Medical Center, Phoenix, AZ, USA

#### Abstract

Remote Magnetic Navigation (RMN) is an evolving technology, allowing operators to reduce radiation exposure in addition to providing precise catheter positioning. While many studies are available to characterize the utility of RMN in different arrhythmia subtypes, there is a paucity of literature evaluating RMN in SVT ablations. In this review, we summarize available literature, caveats and benefits of RMN in SVT ablation.

#### Introduction

Supraventricular tachycardia (SVT) is a broad umbrella term encompassing several different types of arrhythmias including atrioventricular nodal reentrant tachycardia (AVNRT), atrial tachycardia (AT), and atrioventricular reentrant tachycardia (AVRT).

AVNRT is among the most common paroxysmal SVT. This reentrant circuit typically involves a slow antegrade pathway and fast retrograde pathway located in the triangle of Koch, bordered superiorly by the tendon of Todaro, anteriorly by the tricuspid valve septal leaflet, and

posteriorly by the coronary sinus ostium. AVNRT can be categorized into three subtypes based on conduction speed and direction: slow-slow, slow-fast, and fast-slow. The most common circuit type is slow-fast, which has slow antegrade conduction and fast retrograde conduction. Radiofrequency catheter ablation (RFCA) has over 90% success rate and is the standard management strategy.<sup>1-3</sup> Although well established, RFCA has potential limitations including longer fluoroscopy times, catheter instability at the mapping target due to cardiac and respiratory motion, less efficient energy delivery due to catheter tip migration, and lower reproducibility of effective ablation lesion.<sup>1,2</sup>

AVRT is the second most common form of SVT. These macroreentrant tachycardias involve an accessory pathway (AP). The impulse typically travels in antegrade fashion down the AV node and His-Purkinje system and returns to the atrium using the accessory pathway as a conduit for retrograde conduction. Ablation of the AP is successful in excess of 90% of cases.<sup>4</sup>

#### Key Words

Supraventricular Tachycardia; Remote Magnetic Navigation; Ablation

#### Corresponding Author

J Peter Weiss, MD, FACC, FHRS  
Director of Cardiac Interventions Center  
Banner University Medical Center, Phoenix.

Author	Patient Number	AT	AVRT	AVNRT
Wood 2008 (HEART Trial)	15 manual	--	4/5 (acute) 2/3 (chronic)	9/10 (acute); 5/5 (chronic)
	55 magnetic	--	9/12 (acute) 8/8 (chronic)	38/38 (acute); 25/27 (chronic)
Zhang 2012	20 manual	--	--	20/20 (acute and chronic)
	20 magnetic	--	--	20/20 (acute and chronic)
Akca 2013	16 manual	--	--	15/16 (acute); 14/15 (chronic)
	26 magnetic	--	--	26/26 (acute); 25/26 (chronic)
Reents 2017 (MagMa-AVNRT Trial)	113 manual	--	--	113/113 (acute); 111/113 (chronic)
	105 magnetic	--	--	105/105 (acute); 102/105 (chronic)

**Table 1: Prospective RMN Comparison Study Procedural Success.**

Focal AT is defined as AT originating from a discrete focus (<2 cm in diameter), radiating centrifugally.<sup>5</sup> AT accounts for 5–17% of SVT.<sup>6</sup> Focal AT is relatively frequent in young patients but also in elderly patients with significant comorbid conditions. As AT is commonly resistant to medical management, catheter ablation is a popular management strategy.<sup>7</sup> Prior studies on ablation success rates have reported high degree of variability, between 69–100%. Predictors of recurrence include elderly age, other cardiac diseases, and the presence of multiple foci.<sup>8</sup> As life expectancy of complex cardiac patients continues to increase, there is an increasing prevalence of AT in the elderly population.<sup>9</sup>

Remote Magnetic Navigation (RMN) consists of two large magnets creating a uniform magnetic field of 0.08–0.1 T to steer small magnets in the distal tip of the ablation catheter. The first-generation mapping and bipolar ablation catheter used a single magnet (Helios I, Stereotaxis Inc.). The second-generation bipolar catheter used 3 magnets integrated into the tip to result in increased deflection force (Helios II, Stereotaxis Inc.). The third-generation catheter is quadripolar with 3 magnets at the distal tip (Celsius/Navistar RMT, Biosense Webster; Magnoflush, Acutus Medical; Trignum Flux, Biotronik). Changing orientation of the surrounding magnets changes the magnetic vector, with resultant realignment of the catheter. The resulting reorientation can be performed quickly (1.5 seconds). These magnetic field vectors can be stored and reapplied to bring the catheter back to the original position. This allows for precise and remote control using incremental advancing and retracting of the ablation catheter by 1 mm.<sup>10</sup>

Remote Magnetic Navigation (RMN) systems are an increasingly popular modality of performing both simple and complex ablation. While most literature available focuses on atrial fibrillation (AF) and ventricular tachycardia (VT) ablation, a progressively increasing body of literature is available suggesting similar efficacy in SVT ablation. Available literature suggests RMN may reduce fluoroscopic time with better tissue contact, consequently improving catheter stability and improving technical efficiency. The current major meta-analysis demonstrates significant heterogeneity of outcome data, which may be multifactorial in etiology, but integrates retrospective studies, case series and prospective datasets.<sup>11</sup> Our review attempts to address comparative outcomes regarding SVT ablation using RMN with a critical appraisal of current available data. Given heterogeneity of data, when available,

our review attempts to address prospective data specifically. However, given that not all types of SVT have prospective literature available, when data was noted to be sparse, a more comprehensive summary of available literature was provided.

### AVNRT Prospective Literature

The first prospective multicenter randomized trial to evaluate RMN in SVT ablation was the HEART study published in 2008 by Wood et al. In this study, patients were randomized (3:1) to RMN vs. manual ablation. While AVNRT comprised the majority (> 70%) of SVT ablations, cases included also were accessory mediated tachycardia and patients undergoing AV nodal ablation (AVNA) for rate control refractory atrial arrhythmias. Between 5–20 skill building cases were allowed for the RMN group (utilizing Helios II catheter [Stereotaxis Inc., USA] in concert with the Niobe system). Patients were evaluated at 7–14 days and again at 90 days for recurrence with use of event monitor to evaluate recurrence if patients developed symptoms. There was no significant difference observed between the manual and RMN ablation groups with respect to: acute procedural success rates (95% vs. 90%), chronic procedural success (100% vs. 93%), adverse events (6.7% vs. 5.5%), and total procedural time (151 mins vs. 142 mins). The major demonstrable benefit of RMN was with significantly reduced fluoroscopy time (27.1 mins vs. 13.8 mins) and the number of RF lesions delivered (10 vs. 6). This was also among the first studies to shed light on impact of learning curve as skill building cases were independently evaluated. In the discussion, the authors noted that while median procedure time was not different, there was a significant drop in procedure duration with increasing operator experience.<sup>12</sup>

In 2012, Zhang et al. published a randomized, single center prospective trial involving 40 patients (20 for each manual vs. RMN ablation). This study focused specifically on patients with paroxysmal SVT for over 3 years, refractory to more than 2 antiarrhythmic drugs (AAD), with slow-fast type AVNRT diagnosed by transesophageal electrocardiographic study. Electrophysiologists involved in the study were already familiar with the RMN system. An 8Fr quadripolar temperature controlled magnetic ablation catheter (Biosense Webster, Johnson and Johnson, USA) was used in conjunction with the Niobe II system (Stereotaxis Inc., USA). Zhang et al. demonstrated similar outcomes comparing manual ablation with RMN specifically regarding: hospitalization days (3.5 days vs. 3.3 days), 0% recurrence during 9.3 month follow up, 100% procedural success rate, 0% complications, and total procedural time (122.5 mins vs. 126.1 mins,  $p > 0.05$ ). RMN reportedly reduced maximal energy delivered (23.7 W vs. 16.9 W), operator fluoroscopy time (13.6 mins vs. 4.2 mins), and patient fluoroscopy time (14.3 mins vs. 11.5 mins). RMN did, however, have higher associated procedural costs.<sup>1</sup>

In 2013, Akca et al. prospectively evaluated 67 patients comparing RMN, cryoablation, and manual ablation. Patients had a mean age of 48.5 years, with 30.4% male population and were followed for a mean 26-month period. Mean procedure time (83 minutes vs. 117 minutes vs. 117 minutes) and physician radiation time (0 minutes vs. 15.1 minutes vs. 17.5 minutes) was noted to be significantly reduced with no significant difference in procedural success rates (96% vs. 96% vs. 93%) comparing RMN, cryoablation and manual ablation, respectively. No major complications were reported among any of the groups.<sup>13</sup>



The MagMa AVNRT trial was published in 2017 by Reents et al. This 3 center prospective randomized study enrolled 218 patients (113 manual vs. 105 RMN). In the RMN group, a non-irrigated ablation catheter (Celsius RMT, Biosense Webster, Johnson and Johnson, USA) was used in conjunction with the Niobe system (Stereotaxis Inc., USA). Patients were monitored for 24 hours via holter postoperatively and re-evaluated at 6 months via holter or ECG depending on presence of symptoms. The population treated predominantly demonstrated slow-fast AVNRT (95%). Comparing manual ablation to RMN, the study demonstrated similar acute success (100%) and midterm (6 month) success (98% vs. 97%). While patients randomized to RMN were noted to have longer procedural times (79 mins vs. 88 mins,  $p=0.03$ ), there was a significant reduction in overall fluoroscopy time (11 min vs. 6 mins,  $p = 0.001$ ), and overall fluoroscopy dosage (751 cGym<sup>2</sup> vs. 425 cGym<sup>2</sup>,  $p = 0.002$ ).<sup>14</sup> Prospective study outcomes data is summarized in Tables 1 and 2.

### Use of RMN in AVRT

Although the literature on the use of RMN for ablation of AVRT is sparse, the literature available seems to suggest a similar benefit to data observed for AVNRT. In 2007, Chun et al. published a retrospective study evaluating the role of RMN catheters in AVRT ablation. A total of 60 ablations for accessory pathways (AP) were performed in 59 patients (37 male, 22 female), with a mean age of 36, followed for a 3 month period. The study compared 3 groups using the Niobe system (Stereotaxis Inc.): first generation (Helios I, Stereotaxis Inc.), second generation (Helios II, Stereotaxis Inc.), and third generation (Celsius RMT, Biosense Webster) catheters. Clinical outcomes evaluated included procedural success, fluoroscopy time, total radiation dosage, and procedure time. Each successive generation of catheter increased rate of reported procedural success (67% vs. 85% vs. 92%). The study additionally found an incremental significant reduction in fluoroscopy time (21.2 vs. 6.5 vs. 4.9 minutes), total radiation dosage (1110 vs. 290 vs. 129 microGym<sup>2</sup>), and procedure time (217 vs. 182 vs. 172 minutes) for each successive generation of RMN catheter. The total reduction in radiation appeared particularly dramatic as this was an 8.6x reduction in radiation exposure -- highlighting the benefit of continued technological evolution. It should be noted that some of these findings may also be explained by increasing operator experience. Further evaluation of procedural failures (11 cases) suggested a higher failure rate with retrograde access (57%) in comparison to transseptal access (12%) but data was only speculative given the small sample size.<sup>10</sup>

The issue of retrograde access in patients with AP ablation was addressed by Thronton et al. in 2007 in a small study involving 20 patients (14 male, 6 female) with a mean age of 42 years. This study used the Niobe I system (Stereotaxis Inc.), comparing use of Helios II catheter (Stereotaxis Inc.) and the Celsius RMT catheter (Biosense Webster). The authors also sought to compare the first 10 and last 10 cases to address the impact of learning curve. Comparing both Helios II (Stereotaxis Inc.) and Celsius RMT (Biosense Webster), a significant reduction in procedure time was noted (198 minutes vs. 145 minutes). The first 10 procedures were noted to be significantly different than the last 10 procedures in procedural time (180 minutes vs. 137 minutes) and radiofrequency time (458.4 seconds vs. 193.6 seconds). No difference was noted in fluoroscopy time. Although not statistically

significant (small population size), the procedural success rate was noted to increase from 50% to 80%. This data temporally suggests that applied learning improves outcomes.<sup>15</sup>

In 2010, Schwagten et al published the first randomized prospective study enrolling 22 patients to assess the difference between retrograde aortic (RA) and transseptal (TS) approaches of left-sided accessory pathway ablation using the Niobe system in conjunction with Celsius RMT catheter. Although longer fluoroscopy (9.8 minutes vs. 3.9 minutes) and procedural time (23.8 minutes vs. 4.4 minutes) were required for transseptal puncture compared with retrograde aortic valve crossing, no significant difference was noted in total fluoroscopy (15.5 minutes vs. 14.4 minutes), total procedural time (90.9 minutes vs. 87.1 minutes), and procedural success (82% vs. 91%). No major complications were reported in either group.<sup>16</sup>

### Use of RMN in Focal AT

There is a high variability of observed outcomes in AT from broad studies assessing the efficacy of RMN ablations. Consequently, there is a paucity of available literature. In 2018, Liu et al published the first focused retrospective study evaluating outcomes of AT ablation comparing outcomes of patients with structural heart disease (36 patients) to patients without structural heart disease (17 patients). A total of 53 patients were enrolled, ablating a total of 56 foci using the Niobe II system (Stereotaxis Inc.). Acute ablation success was noted in 52 patients [55/56 foci (98%)]. Over a mean follow up of 31 months, success was achieved in 47 patients [50/56 foci (89%)]. There was a mean fluoroscopy time of 5 minutes noted, and a mean procedural time of 109 minutes. Although patients below the age of 60 generally trended towards improved long term success, no significant correlation was found. Multivariate analysis found that age, gender, right sided location, paroxysmal type, presence of multiple foci and LVEF less than 50% were not associated with AT recurrence.<sup>9</sup>

### Long Term Outcomes

In 2011, Bauernfeind et al published registry data comparing RMN to manual ablation in multiple ablation types. A total of 610 consecutive patients (292 RMN vs. 318 manual) were followed for 15 months. A total of 56 patients underwent AT ablation (50 RMN vs. 6 manual), 99 patients underwent AVNRT ablation (29 RMN vs. 70 manual) and 100 patients underwent AVRT ablation (55 RMN vs. 45 manual). There was no observed difference in acute success rates in

Author/Study	Wood 2008/HEART Study		Zhang 2012		Akca 2013		Reents 2017/MagMa-AVNRT Trial	
Ablation Type	Manual	Magnetic	Manual	Magnetic	Manual	Magnetic	Manual	Magnetic
Number of RF Lesions	10	6	--	--	3	8.5	7 ± 10	8 ± 9
Fluoroscopy Time (mins)	27.1	17.8	13.6	4.2	17.5	0	7 ± 9	3 ± 5
Total Procedural Time (mins)	151	151	122.5 ± 5.3	126.1 ± 4.2	117 ± 55	83 ± 25	79 ± 29	89 ± 29
Adverse Events	1 (chest pain)	3 (2 repeat ablation, 1 PE)	0	0	0	0	0	0
Follow Up Duration	100 days		9.3 +/- 2.6 months		26 months		6 months	

**Table 2: Prospective RMN Comparison Study Outcomes.**

any of the arrhythmia types - AT (84% vs. 67%), AVNRT (100% vs. 97%), and AVRT (95% vs. 87%). Procedure time was similar in both groups for AT (188 minutes vs. 208 minutes), AVNRT (114 minutes vs. 136 minutes), and AVRT (134 minutes vs. 146 minutes). The only procedural difference observed was in fluoroscopy time for AVNRT (12 minutes vs. 25 minutes), where no significant difference was found for AT (37 minutes vs. 47 minutes), or AVRT (28 minutes vs. 32 minutes). Longer term assessment found no significant difference in recurrence rates [AT: 14% vs. 25%; AVNRT: 6.9% vs. 7.4%; AVRT: 7.7% vs. 5.2%].<sup>17</sup>

In 2015, Kim et al. published a retrospective study evaluating 121 patients undergoing SVT ablation using RMN. Of these patients, 59 patients had AVNRT. Other arrhythmias evaluated included atrioventricular reentrant tachycardia (AVRT) and focal atrial tachycardia (AT). Patients had a mean follow up of 2.2 years, with the first 50 cases omitted as learning cases utilizing the Niobe system. During this period, 96% of patients undergoing AVNRT ablation were reported recurrence free. Interestingly, the authors reported a lower percentage of patients remaining recurrence free with AVRT (77%) and focal AT (71%).<sup>18</sup>

In 2021 Noten et al published a large retrospective pediatric series on AVRT and AVNRT ablation comparing RMN, manual and cryoablation. A total of 223 patients were enrolled from 2008-2019. Patients had a mean age of 14 years, and were followed for a period of 5.5 years. Among 79 patients undergoing AVNRT ablation, 39 patients used RMN, 12 patients underwent manual ablation and 28 patients underwent cryoablation. In AVNRT ablation, RMN and manual ablation had similar outcomes where cryoablation uniformly had worse outcomes with regard to acute procedural success (100% vs. 100% vs. 85.7%), fluoroscopy dose (30 mGy vs. 27 mGy vs. 45 mGy), and recurrence (7.7% vs. 8.3% vs. 35.7%). RMN did have longer procedure times compared to manual ablation, although fared better than cryoablation (101 minutes vs. 88 minutes vs. 120 minutes). A similar relative pattern of outcome was demonstrated in the 144 patients undergoing AVRT ablation (69 using RMN, 64 undergoing manual ablation and 11 undergoing cryoablation). Outcomes were demonstrated to be better for RMN and manual ablation (with comparable outcomes) as opposed to cryoablation regarding procedural success (98.6% vs. 95.3% vs. 81.8%), and procedural time (105 minutes vs. 100 minutes vs. 150 minutes). All approaches had similar fluoroscopy dose (42 mGy vs. 55 mGy vs. 57 mGy). RMN appeared to have the lowest incidence of recurrence compared to manual and cryoablation (4.3% vs. 15.6% vs. 54.5%).<sup>19</sup>

### Repeat Ablations

Although many publications exist regarding initial ablation procedures involving RMN, less literature is available on patients undergoing repeat ablation. The first prospective registry data was published by Akca et al. in 2013 involving 163 patients, 64% male with a median age of 55 years, undergoing repeat catheter ablation. There were 84 patients undergoing magnetic navigation with the Niobe II (Stereotaxis Inc.) and 79 undergoing manual ablation. Among these patients, 68 were undergoing SVT ablation -- further classified by type: 16 AT, 18 CTI dependent atrial flutter, 15 AVNRT, 18 AVRT, and 1 AV junction ablation. The authors subsequently found in the SVT group,

magnetic navigation had a lower acute success rate (87.9% vs. 100%), longer procedure times (205 minutes vs. 172 minutes). Although not statistically significant, a lower recurrence rate was noted with RMN (17.2% vs. 31.4%,  $p=0.155$ ). There was no difference in fluoroscopy time (42.4 minutes vs. 36.7 minutes). A significant limitation of this data regarding SVT ablation is reported by the authors -- noting a significant difference in distribution among RMN and manual ablation for AT (42.4% vs. 5.7%) and AVNRT (9.1% vs. 31.4%).<sup>20</sup>

### Safety and Cost of RMN

Manual AV nodal slow pathway ablation has a procedural success rate of approximately 97% and recurrence rates of less than 1%. Due to the close proximity of the slow pathway to the AV node, patients are carefully monitored as heartbeat or respiratory motion can dislodge the ablation catheter, potentially resulting in complete heart block. Consequent monitoring via fluoroscopy significantly increases radiation exposure to both operator and patient. Magnet tipped flaccid catheters of RMN systems allow for a remarkable degree of catheter control with movements. There are many benefits to RMN systems with regard to slow pathway ablation including: soft tipped catheters allowing safe cardiac chamber targeting, computer control allowing for good reproducibility as well as reduction of radiation exposure, and absence of push from the magnetic field, allowing close tissue contact. In addition to remote guidance, the high precision of magnetic navigated mapping in addition to soft tip of the catheters allowing better tissue contact enables more efficient ablation, augmenting reduction in fluoroscopy time. Available literature based on cumulative radiation dosage suggests cardiac catheterization laboratory staff are at particular risk for carcinogenesis.<sup>1</sup> In addition to the risk of radiation exposure, the added consequence of lead protection needs to be considered. Electrophysiologists are at high risk for the development of cervical (20.7% vs. 5.5%) and lumbar (25.9% vs. 16.7%) spondylosis in comparison to matched non-interventional cardiologists.<sup>21</sup>

Studies performed have consistently demonstrated high cost for RMN ablation in comparison to manual ablation. There are a few notable reasons for this increase in price: a magnetic navigation laboratory is more expensive than a catheter laboratory, the use of drivers to move magnetic catheters accurately, and variable complexity of magnetic catheters used. As the market for RMN ablation continues to grow and manufacturing improves, the associated cost of ablation will decrease.<sup>1</sup>

### Impact of Learning Curve

In 2020, Li et al. performed a large-scale retrospective analysis further evaluating what other studies such as the HEART study seemed to suggest with regard to fluctuation in procedural time. Based on smaller study data available, the authors theorized that learning curve played a significant role in the previously reported longer procedural time. In this single center retrospective study, 1003 patients undergoing RMN for various ablation procedures were evaluated for safety, and progressive impact of the cumulative number of procedures on procedure and fluoroscopy time. Atrial fibrillation (AF) time changes were reported to demonstrate the impact of learning curve. An incremental reduction in procedure time was from 191.4 minutes to 121.7 minutes with a plateau at approximately 300 procedures. A similar incremental reduction in fluoroscopy time was observed from 9.2 minutes to 4.6

minutes, with a plateau at approximately 350 procedures. While the learning curve impact focused more specifically on AF ablation, SVT comprised 10.8% of the ablations performed, and it seems reasonable to extrapolate that a similar pattern could be observed in other ablation types.<sup>22</sup> In fact, this pattern of reduced procedural time is temporally observed between the HEART study, which reported a total procedural time using RMN of 142 minutes compared to MagMa-AVNRT trial, which reported a total procedural time of 88 minutes.<sup>12,14</sup> It should be noted however, that the meta-analysis data from 2013 coming to this conclusion had a high degree of heterogeneity ( $I^2 = 76\%$ ) and appears to be inconsistent with prospective trial data.<sup>11</sup> The only prospective study to demonstrate a statistically significant increase in procedural time using RMN in AVNRT ablation is the MagMa-AVNRT trial, where a 9 minute difference (79 vs. 88 mins) in procedural time was reported.<sup>14</sup>

### Conclusion

RMN is an increasingly popular modality of ablation, which improves efficiency while reducing operator radiation exposure. Applied learning augments both reduction in procedural and fluoroscopy time. While this may be associated with a greater cost, as this technology continues to grow production development will reduce associated price. Long term outcomes appear to be variable depending on ablation performed. As most of the available literature is retrospective studies or case series, more prospective research is needed to better define which patient populations are likely to benefit.

### References

- Zhang, Y.X., et al., Radiofrequency catheter ablation of atrioventricular nodal reentrant tachycardia guided by magnetic navigation system: a prospective randomized comparison with conventional procedure. *Chin Med J (Engl)*, 2012. 125(1): p. 16-20.
- Jackman, W.M., et al., Treatment of supraventricular tachycardia due to atrioventricular nodal reentry by radiofrequency catheter ablation of slow-pathway conduction. *N Engl J Med*, 1992. 327(5): p. 313-8.
- Perez-Rodon, J., et al., Entrainment from the para-Hisian region for differentiating atrioventricular node reentrant tachycardia from orthodromic atrioventricular reentrant tachycardia. *Europace*, 2008. 10(10): p. 1205-11.
- Rao, A.L., et al., Evaluation and management of Wolff-Parkinson-White in athletes. *Sports Health*, 2014. 6(4): p. 326-32.
- Saoudi, N., et al., Classification of atrial flutter and regular atrial tachycardia according to electrophysiologic mechanism and anatomic bases: a statement from a joint expert group from the Working Group of Arrhythmias of the European Society of Cardiology and the North American Society of Pacing and Electrophysiology. *J Cardiovasc Electrophysiol*, 2001. 12(7): p. 852-66.
- Klersy, C., et al., Factors that predict spontaneous remission of ectopic atrial tachycardia. *Eur Heart J*, 1993. 14(12): p. 1654-6.
- Roberts-Thomson, K.C., P.M. Kistler, and J.M. Kalman, Atrial tachycardia: mechanisms, diagnosis, and management. *Curr Probl Cardiol*, 2005. 30(10): p. 529-73.
- Chen, S.A., et al., Focal atrial tachycardia: reanalysis of the clinical and electrophysiologic characteristics and prediction of successful radiofrequency ablation. *J Cardiovasc Electrophysiol*, 1998. 9(4): p. 355-65.
- Liu, X.Y., et al., Catheter Ablation of Focal Atrial Tachycardia Using Remote Magnetic Navigation. *J Invasive Cardiol*, 2018. 30(4): p. 126-132.
- Chun, J.K., et al., Remote-controlled catheter ablation of accessory pathways: results from the magnetic laboratory. *Eur Heart J*, 2007. 28(2): p. 190-5.
- Shurrab, M., et al., Remote magnetic navigation for catheter ablation of atrioventricular nodal reentrant tachycardia: a systematic review and meta-analysis. *Expert Rev Cardiovasc Ther*, 2013. 11(7): p. 829-36.
- Wood, M.A., et al., Remote magnetic versus manual catheter navigation for ablation of supraventricular tachycardias: a randomized, multicenter trial. *Pacing Clin Electrophysiol*, 2008. 31(10): p. 1313-21.
- Akca, F., et al., Safety and feasibility of single-catheter ablation using remote magnetic navigation for treatment of slow-fast atrioventricular nodal reentrant tachycardia compared to conventional ablation strategies. *Acta Cardiologica*, 2013. 68(6): p. 559-567.
- Reents, T., et al., Multicenter, randomized comparison between magnetically navigated and manually guided radiofrequency ablation of atrioventricular nodal reentrant tachycardia (the MagMa-AVNRT-trial). *Clin Res Cardiol*, 2017. 106(12): p. 947-952.
- Thornton, A.S., et al., Magnetic navigation in left-sided AV reentrant tachycardias: preliminary results of a retrograde approach. *J Cardiovasc Electrophysiol*, 2007. 18(5): p. 467-72.
- Schwagten, B., et al., A randomized comparison of transseptal and transaortic approaches for magnetically guided ablation of left-sided accessory pathways. *Pacing Clin Electrophysiol*, 2010. 33(11): p. 1298-303.
- Bauernfeind, T., et al., The magnetic navigation system allows safety and high efficacy for ablation of arrhythmias. *EP Europace*, 2011. 13(7): p. 1015-1021.
- Kim, S.H., et al., Long-term outcomes of remote magnetic navigation for ablation of supraventricular tachycardias. *J Interv Card Electrophysiol*, 2015. 43(2): p. 187-92.
- Noten, A.M.E., et al., Remote magnetic navigation shows superior long-term outcomes in pediatric atrioventricular (nodal) tachycardia ablation compared to manual radiofrequency and cryoablation. *Int J Cardiol Heart Vasc*, 2021. 37: p. 100881.
- Akca, F., et al., Outcomes of repeat catheter ablation using magnetic navigation or conventional ablation. *Europace*, 2013. 15(10): p. 1426-31.
- Birnie, D., et al., Prevalence and risk factors for cervical and lumbar spondylosis in interventional electrophysiologists. *J Cardiovasc Electrophysiol*, 2011. 22(9): p. 957-60.
- Li, X., et al., Procedural outcomes and learning curve of cardiac arrhythmias catheter ablation using remote magnetic navigation: Experience from a large-scale single-center study. *Clin Cardiol*, 2020. 43(9): p. 968-975.





## Robotic Magnetic Navigation and Ablation of Supraventricular Tachycardia

Gery Tomassoni<sup>1</sup>, Kristie Schneider<sup>1</sup>, Julie Ayers<sup>1</sup>, Katie Nolan<sup>1</sup>, Gwyn Middleton<sup>1</sup>, Peter Gallagher<sup>2</sup>

<sup>1</sup>Baptist Health Lexington; Lexington, Kentucky

<sup>2</sup>Nebraska Heart, CHI, Lincoln, Nebraska

### Abstract

**Background:** Robotic magnetic navigation (RMN) has shown utility in the ablation of supraventricular tachycardia (SVT). We report our efficacy and safety results from a single center performing RMN catheter ablation of atrioventricular nodal reentry tachycardia (AVNRT), atrioventricular reentrant tachycardia (AVRT), WPW (Wolff-Parkinson-White) syndrome, and focal atrial tachycardia (AT).

**Methods:** A single center retrospective study evaluated the use of RMN in the catheter ablation of SVT including AVNRT, accessory pathway (AP) and focal AT. The primary endpoint was documented recurrence of tachyarrhythmia or recurrence of preexcitation on twelve-lead ECG post ablation. Additional endpoints included total procedural time, procedural fluoroscopic time, operator fluoroscopic time, acute procedural success, and complication rates.

**Results:** 144 SVTs were ablated in 131 pts: AVNRT 79/144 (55%), AP 40/144 (28%), and AT 25/144 (17%). The acute ablation success rate with RMN catheters was 142/144 (99%). Twenty-three (16%) SVTs were septal in location (17 AP and 6 AT). All 23 SVTs were successfully ablated without complication including 7 mid septal & anterior septal APs and 3 parahisian ATs. Five patients with 6 SVTs (3 AVNRT, 1 RA anterior tricuspid valvular AT, 1 right anterior lateral AP, and 1 parahisian AT) were successfully ablated with a RMN catheter after failing ablation with a manual catheter. Total fluoroscopy times were  $12 \pm 9$  minutes with operator fluoroscopic exposure of  $1.5 \pm 1$  min. 111/131 (85%) patients with 123 SVTs were seen at  $5 \pm 3$  months (range 3-14M). The success rates at follow-up were AVNRT 69/69 (100%), AP 29/31 (94%), and AT 22/23 (96%).

**Conclusions:** RMN guided ablation of SVT demonstrated excellent acute and chronic success rates with minimal operator fluoroscopic exposure. It was highly successful in procedures with challenging anatomy or at high risk for catheter related AV block.

### Introduction

Radiofrequency catheter ablation (RFCA) has revolutionized the treatment of both atrial and ventricular arrhythmias in the field of electrophysiology (EP). Despite its success, RFCA can be a complex, time-consuming procedure associated with high radiation exposure to both the patient and physician. In addition, it requires excellent operator manual dexterity to guide the ablating catheter to certain cardiac anatomical locations. Poor catheter contact with instability or excessive applied force can result in failure to eliminate the arrhythmia or more importantly, serious potential complications. Robotic magnetic navigation (RMN) has served as a viable alternative to traditional

manual catheter ablation since the introduction of the system (Niobe Stereotaxis, St. Louis, MO, USA) in 2003. RMN potential advantages over manual ablation include precise catheter tip control with consistent cardiac tissue contact, improved catheter maneuverability through tortuous anatomy, reduced operator stress and fatigue, low risk of cardiac perforation, and reduction in radiation exposure.

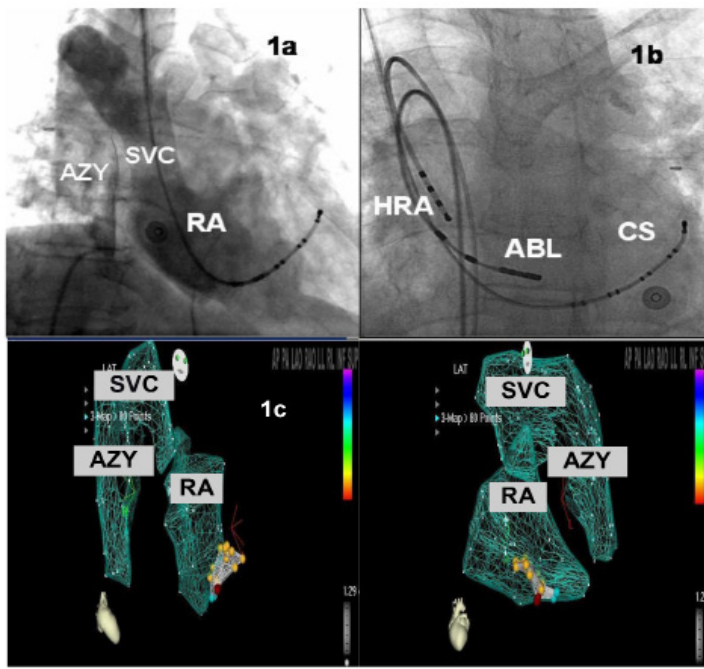
Multiple studies have demonstrated the utility of RMN ablation of supraventricular tachycardia (SVT)<sup>1-10</sup>. In the adult population, studies have included both single site experiences<sup>1-6</sup> as well as two multicenter randomized trials<sup>8,9</sup>, mainly in the treatment of atrioventricular nodal reentrant tachycardia (AVNRT). Although published data regarding RMN ablation of atrioventricular reentrant tachycardia (AVRT)<sup>1,3,5</sup> and atrial tachycardia (AT)<sup>3,6</sup> is present, the data is limited by low patient numbers or in patients only with congenital heart disease<sup>12</sup>. In addition, the number of cases reported for RMN ablation of mid/anterior septal accessory pathways (AP) and septal ATs where a high potential for atrioventricular (AV) block exists is small<sup>6,7,11</sup>. Therefore,

### Key Words

Remote Magnetic Navigation; Supraventricular Tachycardia; Catheter Ablation

### Corresponding Author

Gery Tomassoni, MD, FACC, FHRS  
1720 Nicholasville Road, Suite 400, Lexington, KY 40503



**Figure 1:** Right anterior oblique (RAO) and anterior posterior (AP) fluoroscopic images with dye injection (1a) of a persistent hemi-azygos (AZY) continuation to the superior vena cava (SVC) in a patient with AVNRT. Figure 1b demonstrates the location of the coronary sinus (CS) catheter from the right internal jugular vein and both the high right atrial (HRA) and Navistar RMT ablation (ABL) catheters advanced from the femoral vein into the RA. The ABL catheter tip located at the slow pathway. Right posterolateral and left posterolateral views of a CARTO electro-anatomical map (1c) depicting the AZY, SVC, and RA with the red tag showing the successful site for slow pathway catheter ablation. Yellow tags = His bundle signals, light blue tags = CS ostium location.

the aim of this single-center retrospective study was to assess the safety and efficacy of RMN ablation in a general SVT population including cases of AVNRT, AP, and focal AT in order to add to the existing body of literature, mainly highlighting cases in patients with difficult anatomy or at a higher risk of developing catheter induced AV block.

## Methods

### Patient Enrollment/Study design

All patients met the standard indications for SVT ablation. All patients provided written informed consent. The retrospective chart review was approved by Baptist Health Lexington IRB. The primary endpoint was documented recurrence of tachyarrhythmia or recurrence of preexcitation on twelve-lead ECG post ablation. Additional endpoints included total procedural time, fluoroscopic time, operator fluoroscopic time, acute procedural success, and complication rates.

### Procedural Details

Procedures were performed >5 half-lives after discontinuing AV nodal or antiarrhythmic medications. All procedures were performed under a standard conscious sedation protocol using midazolam and fentanyl. Via right internal jugular vein access, a multipolar catheter (Abbott, St. Paul, MN, USA) was placed in the coronary sinus (CS). Using the right femoral vein approach, roving 6 Fr quadripolar catheters

(Abbott, St. Paul, MN, USA) were positioned in the right atrium/His bundle/RVA locations. A standard EP study was performed. The diagnosis of AVNRT, AVRT, and AT was based on standard criteria previously reported during invasive EP study<sup>13-15</sup>.

The remote magnetic catheter navigation system (Niobe II, Stereotaxis, Inc., St Louis, MO, USA) has been previously described in detail<sup>1,2</sup>. Using either the CARTO RMT integrated 3-D electro-anatomical system (Biosense Webster, Johnson & Johnson, Irvine, CA, USA) or Stereotaxis computer generated interface and a computerized motor drive system (Stereotaxis, Inc., St. Louis, MO, USA), a magnetic ablation catheter was advanced to right atrium (RA) or left atrium (LA) via right femoral vein or right femoral artery. The catheter tip was maneuvered by adjusting the magnetic field created by two large external magnets held by robotic arms next to the patient's table. The catheter shaft was advanced or retracted with the aid of the computerized motor drive system. The following RMN ablation catheters were used in the study: Helios II (Stereotaxis, Inc., St Louis, MO, USA), Celsius RMT, and Navistar RMT (Biosense Webster, Johnson & Johnson, Irvine, CA, USA). If left sided ablation was necessary, the choice of LA access between transseptal or retrograde aortic approach was left to the operator's discretion. If left-sided ablation was necessary, intravenous heparin was initiated to maintain activating clotting times greater than 300 seconds. Intracardiac ultrasound (ICE) was used at the discretion of the operator to facilitate transseptal catheterization.

## Ablation

RFCA was performed either in power or temperature controlled mode. Maximal power output was set to 50 W at 54°C. The duration of the ablation was left to the operator's discretion. Procedural endpoint for AVNRT, AVRT, and focal AT was non-inducibility of the tachycardia and/or absence of AP conduction both on/off isoproterenol and/or adenosine following a 30 minute waiting period post ablation. After slow pathway ablation, non-inducibility of AVNRT despite the presence of a single echo beat was an acceptable endpoint. The ablation was performed by one of three operators.

## Follow-up

All patients were seen in clinic 3M from discharge and every 3-6M as needed thereafter. 12 lead ECGs were routinely performed at clinic follow-up. Holter monitors, event recorders, and 12 lead ECGs were ordered if the patient developed recurrent tachycardia symptoms.

**Table 1: RMN SVT Ablations**

	RMN SVT Ablations		
	AVNRT 55%	AVRT/WPW 28%	AT 17%
<b>Acute Ablation Success N=144</b>	78/79 (99%)	40/40 (100%)	24/25 (96%)
<b>Chronic Ablation Success N=123</b>	69/69 (100%)	29/31 (94%)	22/23 (96%)
<b>Procedural time (min)</b>	141 ± 16	174 ± 82	175 ± 83
<b>Fluoroscopy time (min)</b>	10 ± 7	16 ± 11	14 ± 8
<b>MD Fluoroscopy time (secs)</b>	70 ± 45	117 ± 72	117 ± 63

## Definitions/Statistical Analysis

Total procedure time was defined as the time from first skin puncture until removal of the sheaths and catheters. Acute procedural success was defined as complete elimination of accessory pathway conduction and non-inducibility of the tachycardia for AVNRT and AT. Recurrence was defined as an episode of sustained SVT recorded on a twelve-lead ECG, Holter monitor/event recorder, or device implant or recurrent accessory pathway conduction on twelve-lead ECG. Chronic success was defined as the absence of arrhythmia recurrence over a minimal of 90 days and up to 12M post ablation.

Continuous data are represented as mean  $\pm$  1 standard deviation (SD). The Fischer exact test or a binomial probability distribution was applied to categorical variables, as appropriate. A p-value of  $< 0.05$  was considered statistically significant.

## Results

RMN SVT catheter ablation was performed in 131 pts. The age was  $45 \pm 16$  years (range 16 -79) with 53 men and 78 women. 129/131(98%) pts were first ablations with 3/131 (2%) being re-do ablations. A total of 144 SVTs were ablated. Eleven (8%) patients had multiple SVTs ablated at EPS. The predominant arrhythmia was AVNRT in 79/144 (55%). AP and AT were present in 40/144 (28%) and in 25/144 (17%), respectively (Table 1). 21 RA (84%) and 4 LA (16%) tachycardias were ablated. Six ATs were septal in origin. 4 ATs were located along the anterior MV (2) and TV annulus (2). Of the 40 APs, 24 (60%) were left-sided in location: 8 lateral, 4 posterolateral, 3 posteroseptal, 4 posterior, 2 anterior, 1 antero-septal, 1 mid-septal, and 1 anterolateral. 16 (40%) APs were right-sided in location: 7 posteroseptal, 3 mid-septum, 3 lateral, 1 anterior, 2 antero-septal. 20/24 (83%) of the left-sided APs were ablated using the retrograde aortic approach. Total procedural and fluoroscopy times were  $153 \pm 71$  minutes and  $12 \pm 9$  minutes, respectively. The total fluoroscopic exposure to the physician was  $1.5 \pm 1$  min.

The acute ablation success rate with RMN catheters was 142/144 (99%) (Table 1). An AT requiring higher watts for ablation and an AVNRT requiring a long intravascular sheath for added stability with a standard catheter were the two acute RMN failures.

## Challenging Anatomical Cases

Twenty-three (16%) SVTs were septal in location (17 APs and 6 AT). All 23 SVTs were successfully ablated without complication including 7 mid-septal & antero-septal APs and 3 parahisian ATs. 5 patients with 6 SVTs (3 AVNRT, 1 RA anterior tricuspid valve (TV) annular AT, 1 right antero-septal AP, and 1 parahisian AT) were successfully ablated with a RMN catheter after failing ablation with a manual catheter during the same procedure. The first patient was found to have an incidental finding of a hemi-azygos continuation to the superior vena cava during EPS. Both AVNRT and an anterior TV annular AT were successfully ablated in this patient using RMN and CARTO 3-D mapping system (Figure 1.) The second patient with AVNRT required a Navistar RMT catheter for successful slow pathway ablation after failed manual catheter ablation (Figure 2). The third patient had a very large persistent left subclavian vein with a large ostium emptying into

the RA resulting in an extremely small distance between the lowest HIS bundle signal and CS roof (Figure 3). A right atrial free wall AP in the fourth patient (Figure 4) and a parahisian AT in the 5th (Figure 5) patient required a Navistar RMT catheter to improve and maintain stability during RFA that could not be attained with a standard manual catheter.

## Clinical Outcomes

111/131 (85%) patients with 123 SVTs were seen at  $5 \pm 3$  months (range 3-14M). The success rates at follow-up were AVNRT 69/69 (100%), AP 29/31 (94%), and AT 22/23 (95%) (Table 1). The 2 AP recurrences were located along the right free wall and right posterior septum. The right posterior septal ablation recurrence occurred in a patient with Ebstein's anomaly requiring a second more aggressive ablation within the coronary sinus.

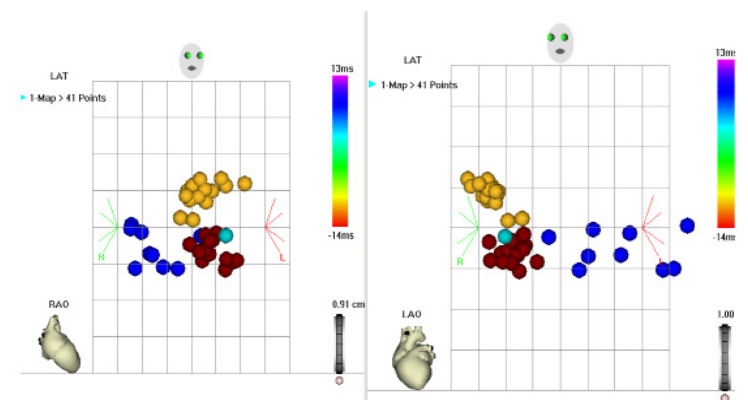
No major complications occurred. No permanent AV block or pericardial effusions were noted. Minor complications included two small groin hematomas that resolved without intervention.

## Discussion

The results of this study demonstrates that RMN can be safely and effectively used for RFCA of AVNRT, AP, and focal AT with minimal operator fluoroscopic exposure. More importantly, RFCA of SVT utilizing RMN was highly successful with no major complications not only in simple cases but also in complex procedures. The complexity of procedures in our series included patients with challenging anatomy, congenital anomalies, and high risk septal SVTs.

## SVT Ablation Outcomes Compared with Previous Published Results

The clinical outcomes reported in this investigation are similar to previously published results of RMN-guided SVT ablation<sup>2-6,8,9</sup>. In regards to AVNRT, both the fluoroscopy times and procedure duration were similar to previous RMN AVNRT ablation studies,  $8.9 \pm 6$  min &  $145 \pm 43$  min<sup>2</sup>. The acute and chronic procedure success reported in



**Figure 2:** Right anterior oblique (left) and left anterior oblique (right) views of a RA His bundle cloud electro-anatomical map in a patient with AVNRT. Despite multiple ablation attempts using a manual catheter along the RA septum (red tags), AVNRT was still inducible. Successful slow pathway ablation was achieved using a Navistar RMT catheter (light blue dot).

Yellow tags = His bundle signals, blue tags = coronary sinus location.



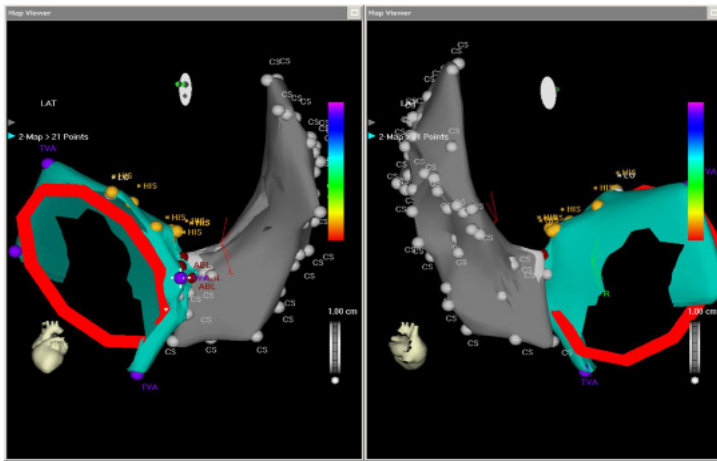


Figure 3:

Left lateral (LL) and right posterior lateral (PL) views of a CARTO electro-anatomical map in a patient with AVNRT and a large persistent left subclavian vein. Note the very small distance available for ablation between the lowest HIS bundle signal and the roof of the giant coronary sinus (CS). The slow pathway was successfully ablated (red tags) using a Navistar RMT catheter

TVA = tricuspid valve annulus

this study is consistent with the results of other RMN-guided AVNRT trials<sup>2,8,9</sup>. In our study, operator fluoroscopy times were slightly less at  $70 \pm 45$  secs compared to  $3 \pm 5$  min<sup>9</sup>. Similarly, reported acute and chronic RFCA success using RMN in the treatment of APs and focal ATs was comparable to the results in this study<sup>3,6,8</sup>. Thus our data further validates the conclusions from previous studies of RMN-guided SVT ablation.

Since RMN directs the catheter tip with no limitation on extension, it can be used in any cardiac chamber and with any approach including retrograde aortic, transeptal, or even epicardial. Similar to previously published data, RMN ablation of left-sided APs using the retrograde aortic approach was not technically difficult and was the preferred approach in the majority (83%) of cases. By using the retrograde aortic approach, the operator was exposed to less radiation with less standing and a reduced need for wearing lead aprons.

### High Risk AV block Cases/Challenging Anatomical/ Congenital Anomalies

Ablation of SVTs associated with a high risk of potential AV block remains a clinical challenge<sup>16,17</sup>. Septal APs and parahisian AT ablation can be complicated by low success rates, high recurrence rates, and the potential of transient or permanent AV block<sup>16,17</sup>. In our patient series, 23 cases of septal APs or ATs were successfully ablated using radiofrequency energy. In particular, 10 SVT cases (mid or antero-septal in location) with the highest potential for AVB underwent successful RFCA without complication. Our results may be explained by improved catheter tip stability allowing for precise ablative energy delivery in RMN. Despite respiratory variation and cardiac motion during tachycardia, minimal catheter tip movement occurred resulting in more consistent tissue contact and theoretically, creation of a more well-defined, discrete lesion<sup>18,19</sup>. As a result of better catheter tip control and more consistent tissue contact, SVT can be safely ablated during tachycardia and without the need of another ablative source (i.e. cryoablation).

6 SVTs including three AVNRTs, RA anterior TV annular AT, right anterior lateral AP and a parahisian AT were successfully ablated with a RMN catheter after unsuccessful ablation with a manual catheter. Possible explanations for the superior results with RMN-guided ablation has been previously described in the literature. Firstly in an in vitro simulation<sup>18</sup>, RMN has shown enhanced catheter stability compared to a manually controlled catheter on wall motion. In the simulation, the RMN catheter tip remains in constant tissue contact (fixed location) as opposed to a manually controlled catheter that can result in sliding laterally when it is pushed against the same wall motion<sup>18</sup>. Secondly, there appears to be a decreased variability in catheter temperature during RMN-guided ablation as demonstrated both in our series and in other investigators<sup>4</sup>. As a result, optimal catheter tip-tissue contact may create a more appropriate ablative lesion in terms of both size and depth compared to ablative lesions created by non-optimal contact.

Congenital heart disease patients with both simple and complex arrhythmias have benefitted greatly from RMN<sup>12,20</sup>. SVT ablation in patients with congenital anomalies are associated with a higher procedural complexity, tortuous anatomy, and limited access routes to various cardiac chambers<sup>12,20</sup>. In this patient population, RMN can provide access to target chambers that would ordinarily be difficult to reach with manual catheters. Successful RMN-guided SVT ablations using the retrograde aortic approach in patients with previous intra-atrial baffle procedures or interrupted IVC access have been reported<sup>12</sup>. In addition, RMN resulted in successful right AT ablation in a patient with a hemi-azygos continuation to the SVC<sup>20</sup>. Three patients with congenital anomalies were identified and successfully ablated in our series: a TV AT and AVNRT in a hemi-azygos continuation to the

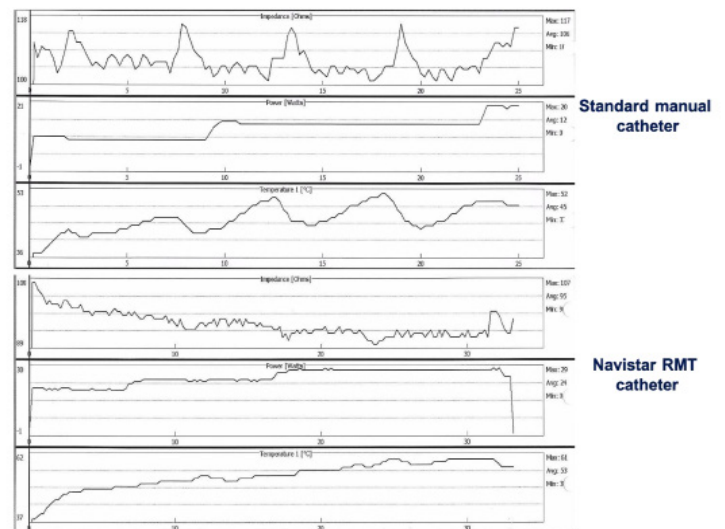


Figure 4:

Impedance, power, and temperature recordings during RFA of a right free wall AP. The top view demonstrated significant variation in impedance and temperature during a 25 second RFA delivery using a manual ablation catheter resulting in low wattage and failure to eliminate AP conduction. The catheter instability was mainly due to significant respiratory variation. The bottom view demonstrates an initial 12 ohm impedance drop and ensuing stable impedances/temperatures (decreased variation) resulting in a higher wattage and immediate elimination of AP conduction using a Navistar RMT catheter.

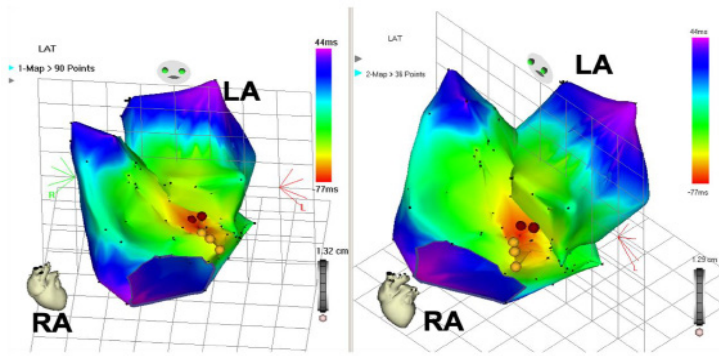


Figure 5:

Right atrial (RA) and left atrial (LA) CARTO electro-anatomical activation maps with a cranial anterior posterior view (left) and a cranial left anterior view oblique (right) demonstrating the successful site (red tags) of a parahisian atrial tachycardia.

SVC, AVNRT in a large persistent left SCV, and a right posteroseptal AP in an Epstein's anomaly. Both the hemi-azygos continuation and the persistent left SCV were incidentally found at time of EPS. Due to the omni-directional steering capability of the magnetic catheter, the desired ablation targets were reached without difficulty and successful ablation was achieved.

### Limitations

The main limitation of this study is the lack of a control group undergoing conventional ablation alone for a true comparison of the long-term effectiveness of RMN-guided SVT ablation. Another limitation is the lack of a randomization protocol comparing RMN SVT ablation with standard manual catheter or contact force catheter. Follow-up in this study was limited to 3-14 M which may affect overall success rates. Radiation dosages were not reported which may be a more sensitive indicator of total radiation exposure. Electro-anatomic mapping systems were not used in all cases. The learning curves of the three different operators might affect the procedure outcomes. Finally, the ablation mode and duration of RF energy was not standardized.

### Conclusions


In our single center retrospective observational study, RMN-guided ablation of AVNRT, AVRT, and AT demonstrated excellent acute and chronic success rates with minimal operator fluoroscopic exposure. It was highly successful in procedures with challenging anatomy, congenital anomalies, and at potential high risk for catheter related AV block.

### References

- Faddis MN, Chen J, Osborn J, Talcott M, et al. Magnetic guidance system for cardiac electrophysiology: a prospective trial of safety and efficacy in humans. *J Am Coll Cardiol*. 2003 Dec 3;42(11):1952-8.
- Ernst S, Ouyang F, Linder C, Hertting K, et al. Initial experience with remote catheter ablation using a novel magnetic navigation system: magnetic remote catheter ablation. *Circulation*. 2004 Mar 30;109(12):1472-5.
- Li X, Zhang N, Ling T, Lin C, et al. Procedural outcomes and learning curve of cardiac arrhythmias catheter ablation using remote magnetic navigation: Experience from a large-scale single-center study. *Clinical Cardiology* 2020 May;43(9):968-975.
- Davis DR, Tang AS, Gollob MH, Lemery R, et al. Remote magnetic navigation-

assisted catheter ablation enhances catheter stability and ablation success with lower catheter temperatures. *Pacing Clin Electrophysiol*. 2008 Jul;31(7):893-8.

- Xu D, Yang B, Shan Q, Zou J, et al. Initial clinical experience of remote magnetic navigation system for catheter mapping and ablation of supraventricular tachycardias. *J Interv Card Electrophysiol*. 2009 Sep;25(3):171-4.
- Liu XY, Jacobsen PK, Pehrson S, Chen X. Catheter Ablation of Focal Atrial Tachycardia Using Remote Magnetic Navigation. *J Invasive Cardiol*. 2018 Apr;30(4):126-132.
- Noten AME, Kammeraad JAE, Ramdat Misier NL, Wijchers S, et al. Remote magnetic navigation shows superior long-term outcomes in pediatric atrioventricular (nodal) tachycardia ablation compared to manual radiofrequency and cryoablation. *Int J Cardiol Heart Vasc*. 2021 Oct 1;37:100881.
- Wood MA, Orlov M, Ramaswamy K, Haffajee C, et al. Stereotaxis Heart Study Investigators. Remote magnetic versus manual catheter navigation for ablation of supraventricular tachycardias: a randomized, multicenter trial. *Pacing Clin Electrophysiol*. 2008 Oct;31(10):1313-21.
- Reents T, Jilek C, Schuster P, Nölker G, et al. Multicenter, randomized comparison between magnetically navigated and manually guided radiofrequency ablation of atrioventricular nodal reentrant tachycardia (the MagMa-AVNRT-trial). *Clin Res Cardiol*. 2017 Dec;106(12):947-952.
- Shurrah M, Danon A, Crystal A, Arouny B, et al. Remote magnetic navigation for catheter ablation of atrioventricular nodal reentrant tachycardia: a systematic review and meta-analysis. *Expert Rev Cardiovasc Ther*. 2013 Jul;11(7):829-36.
- Ernst S, Hachiya H, Chun JK. Remote catheter ablation of parahisian accessory pathways using a novel magnetic navigation system—a report of two cases. *J Cardiovasc Electrophysiol* 2005; 16: 659-662.
- Ueda A, Suman-Horduna I, Mantziari L, Gujic M, et al. Contemporary outcomes of supraventricular tachycardia ablation in congenital heart disease: a single-center experience in 116 patients. *Circ Arrhythm Electrophysiol*. 2013 Jun;6(3):606-13.
- Jackman WM, Beckman KJ, McClelland JH, Wang X, et al. Treatment of supraventricular tachycardia due to atrioventricular nodal reentry by catheter ablation of the slow-pathway conduction. *N Engl J Med* 1992; 327:313-318.
- Jackman WM, Wang X, Friday KJ, Roman CA, et al. Catheter ablation of accessory atrioventricular pathways (Wolff-Parkinson-White syndrome) by radiofrequency current. *N Engl J Med* 1991; 324:1605-1611.
- Knight BP, Zivin A, Souza J, Flemming M, et al. A technique for the rapid diagnosis of atrial tachycardia in the electrophysiology laboratory. *J Am Coll Cardiol* 1999; 33(3):775-781.
- Wong T, Markides V, Peters NS, Davies DW. Characteristics and radiofrequency ablation therapy of intermediate septal accessory pathway. *Am J Cardiol* 1994 Jan 1;73(1): 50-56. doi: 10.1016/0002-9149(94)90726-9
- Bravo L, Atienza F, Eidelman G, Avila P, et al. Safety and efficacy of cryoablation vs. radiofrequency ablation of septal accessory pathways: systematic review of the literature and meta-analyses. *Europace* 2018; Aug 1; 20(8): 1334-1342. doi: 10.1093/europace/eux269.
- Bhaskaran A, Barry MA, Al Raisi SJ, et al. Magnetic guidance versus manual control: Comparison of radiofrequency lesion dimensions and evaluation of the effect of heart wall motion in a myocardial phantom. *J Interv Card Electrophysiol*. 2015; 44:1-8.
- Grossi S, Grassi F, Galleani L, Bianchi F, et al. A comparison of contact force and remote magnetic navigation on lesion formation for the ablation of atrial fibrillation. *Pacing Clin Electrophysiol*. 2018; 41(5). doi.org/10.1111/pace.13297.
- Ernst S, Chun JK, Koektuerc B, Kuck KH. Magnetic navigation and catheter ablation of right atrial ectopic tachycardia in the presence of a hemi-azygos continuation: a magnetic navigation case using 3D electroanatomical mapping. *J Cardiovasc Electrophysiol*. 2009 Jan;20(1):99-102.



## First Human Experience with Catheter Ablation Using Dipole Charge Density Mapping Integrated in Robotics in The Management of Atrial Fibrillation

Rita B. Gagyi<sup>1</sup>, Anna M.E. Noten<sup>1</sup>, Sip Wijchers<sup>1</sup>, Sing-Chien Yap<sup>1</sup>, Robit E. Bhagwandien<sup>1</sup>, Mark G. Hoogendijk<sup>1</sup>, Tamas Szili-Torok<sup>1</sup>

<sup>1</sup>Erasmus Medical Center, Rotterdam, The Netherlands

### Abstract

**Background:** Remote magnetic navigation (RMN) guided catheter ablation (CA) has previously demonstrated high efficiency and efficacy in atrial fibrillation (AF) ablation. Previously, only the CARTO 3D mapping system was integrated in the RMN system. Recently, a novel high-resolution non-contact mapping system (AcQMap) can be used in combination with the RMN robotic system (AcQMap-RMN).

**Objective:** To assess the feasibility by analyzing safety, efficiency, and efficacy of dipole charge density mapping in RMN guided ablation procedures for AF.

**Methods:** All patients undergoing ablation for AF using the AcQMap-RMN system were included. The AcQMap creates echocardiography-based anatomy and identifies potential sources of atrial fibrillation such as focal firing, rotational activity, and localized irregular activation. Demographic, procedural and follow-up data were analyzed.

**Results:** A total of 71 consecutive patients were included in this study (24 female, mean age 60.8±9.9 years, 49 redo and 22 de novo procedures). As primary outcome we report no major complications, while two patients developed groin hematoma, as minor post-procedural complication (2.8%). After completing PVI, 45 patients underwent AcQMap based substrate ablation. The mean procedure time was 170.5±43.3 min, mean ablation time 1749.6±950.7 s, mean radiation dose was 207.0 (IQR 128.5 - 349.5) mGy. Comparing patients undergoing substrate ablation with patients undergoing (redo) PVI-only, we documented higher numbers of application (36.0 vs 23.0, p=0.01), higher radiation doses (255.0 vs 142.0 mGy, p=0.03), and radiation times (26.2±8.2 vs 20.4±5.1 min, p<0.01) in patients requiring substrate ablation. In the persAF group 34 patients (72.3%) were AF-free at the end of the 12-month follow-up period. The overall freedom from any atrial arrhythmias was 68.0% in this patient group

**Conclusion:** AcQMap-RMN integration is a feasible tool and provides high acute and long-term success rates associated with low complication rates in AF ablation.

### Introduction

Atrial fibrillation (AF) is the most common sustained arrhythmia, and it is associated with increased mortality and morbidity rates<sup>1</sup>. Catheter ablation (CA), as treatment option, showed superiority over medical therapy in maintenance of sinus rhythm<sup>2</sup>. However, the expanding indication necessitates additional technical enhancements in order to achieve efficient CA with further improved long-term results, especially in patients with persistent atrial fibrillation and

in patients with failed first CA<sup>3,4</sup>. The remote magnetic navigation (RMN) guided approach previously demonstrated feasibility in CA of AF<sup>5,6</sup>. Furthermore, its atraumatic catheter design has a superior safety profile with exceptional navigation capabilities<sup>7-11</sup>.

Heretofore, only the CARTO 3 (Biosense-Webster Inc, Diamond Bar, CA, USA) mapping system was fully integrated in the RMN system (Niobe ES, Stereotax is, St. Louis, MO, USA) allowing mapping of complex arrhythmias. The newest version of the CARTO system incorporates a panoramic mapping system, which was designed to identify AF drivers, however it is not integrated in the RMN system. Recently, a novel high-resolution non-contact mapping system (AcQMap, Acutus Medical, Carlsbad, CA, USA) is integrated in the RMN robotic system (AcQMap-RMN). The AcQMap imaging and mapping system rapidly creates highly accurate 3D chamber

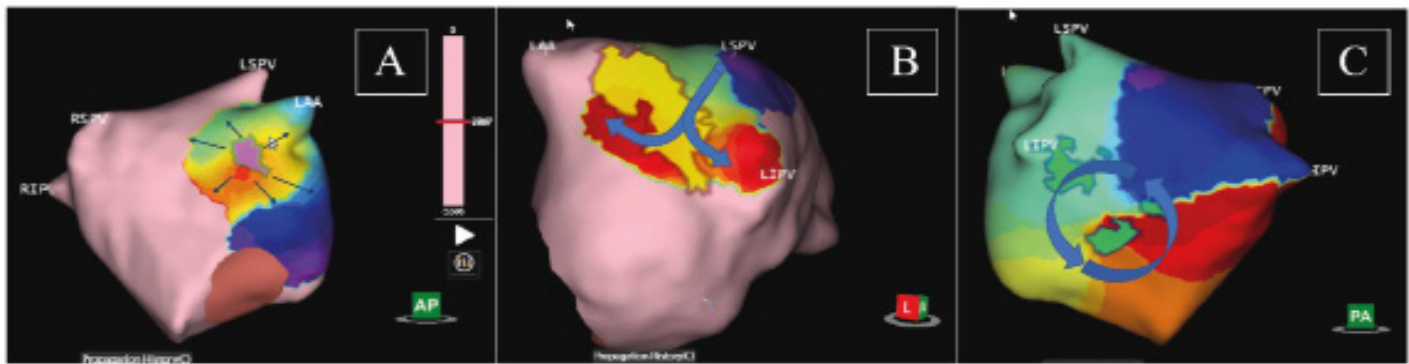
### Key Words

Atrial Fibrillation; Catheter Ablation; Magnetic Navigation; Mapping

### Corresponding Author

Tamas Szili-Torok, MD, PhD  
Thoraxcenter, Department of Clinical Electrophysiology  
Erasmus MC, Postbus 2040, 3000 CA Rotterdam  
Doctor Molewaterplein 40, 3015 GD Rotterdam, The Netherlands





**Figure 1:** Atrial fibrillation source activation patterns

(A) Focal activation (purple) with radial conduction from a single location, which is at least 3ms earlier than its surrounding vertices. (B) Localized irregular activation (LIA) (yellow) is a disorganized pattern of conduction with repetitive, multidirectional, isthmus-like conduction through a small, confined zone that may enter, exit, and pivot within and around the zone. Often LIA zones are involved in complex reentry. Directional change is determined by the angle-difference between entrance and exit vectors (if  $> 90^\circ$ ) and is strongly correlated to slow-conduction zones. (C) Localized partial rotational activation (green) is a regionally organized pattern of conduction that rotates in one direction around a confined zone (clockwise or counter-clockwise) and subtends a path of  $\geq 270^\circ$ ).

reconstructions combined with high-resolution maps of electrical activation using dipole charge density and permits mapping of any stable and unstable cardiac rhythm<sup>12</sup>. Furthermore, due to its versatility, it can quickly create multiple remaps if the source dynamically converts during ablation from irregular to regular rhythm<sup>13</sup>.

The aim of this study was to report first in human experience on safety, feasibility, and efficacy of AcQMap-RMN integration in AF catheter ablation procedures.

## Methods

### Primary hypothesis and study design

The local medical ethics committee (SERCA-2, MEC-2021-0299) approved the data collection for this single center study and concluded that the study did not fall under the Medical Research Involving Human Subjects Act.

The primary hypothesis was that the AcQMap-RMN integration is feasible for AF ablation with good efficiency and efficacy, without having a negative impact on procedural safety. Additionally, we hypothesized that it allows applying an individualized CA approach for patients. The primary endpoint of this study was safety characterized by intra- and post-procedural complications. The secondary endpoints were procedural efficiency and efficacy characterized by procedure time, ablation time, radiation times, radiation doses and atrial fibrillation success rates.

### Study population

We analyzed data of all consecutive patients undergoing pulmonary vein isolation (PVI) or redo-PVI using the AcQMap-RMN system. The inclusion criteria were documented AF on ECG, Holter monitoring, or previous PVI procedure with documented recurrences. Based on the classification of the American College of Cardiology and American Heart Association AF types(2), data were compared between the paroxysmal AF, and persistent AF patient groups.

### Definitions

Total procedure time was defined as the time passed from first

puncture until the removal of sheaths. Acute success was defined as AF source elimination and entry and exit block assessed by pacing after PV (re)isolation. Recurrence was defined as AF  $> 30$  seconds recorded on 12-lead ECG, or 24-hour to 7-day continuous Holter monitoring. Major complications were defined as any adverse event related to the procedure, which were life threatening, required significant surgical intervention; increased hospital admission time or resulted in death. Minor complications were defined as adverse events which resulted in minimal transient impairment of a body function or damage to a body structure, or which did not require any intervention.

**Table 1:** Demographic and clinical data

	All pts. (n=71)	PAF (n=24)	PersAF (n=47)	p
Redo procedure	49 (69.0%)	21 (87.5%)	28 (59.5%)	0.016
Age (y)	60.8±9.9	60.2±11.9	61.1±8.8	0.716
Female	24 (33.8%)	10 (41.6%)	14 (29.7%)	0.324
Height (cm)	179.5±9.7	177.1±8.2	180.7±10.2	0.143
Weight (kg)	89.7±16.0	86.4±12.5	91.5±17.4	0.208
BMI (kg/m <sup>2</sup> )	27.4±3.9	27.4±3.3	27.4±4.2	0.991
AAD	54 (76.0%)	16 (66.6%)	38 (80.8%)	0.190
LVEF (%)	53.7±6.0	54.5±4.3	53.3±6.7	0.463
LA volume (mL)	80.8±22.5	78.5±25.2	81.8±21.8	0.734
LA size (mm)	45.8±7.3	42.3±6.8	47.3±7.1	0.042
LAVI	38.4±10.8	38.2±12.9	38.5±10.2	0.935
Heart failure	5 (7.0%)	1 (4.1%)	4 (8.5%)	0.506
Ischemic heart disease	9 (12.6%)	2 (8.3%)	7 (14.8%)	0.439
Hypertension	35 (49.2%)	9 (37.5%)	26 (55.3%)	0.160
Cardiomyopathy	1 (1.4%)	0 (0.0%)	1 (2.1%)	0.479
Diabetes	10 (14.0%)	6 (25.0%)	4 (8.5%)	0.060
Dyslipidemia	14 (19.7%)	5 (20.8%)	9 (19.1%)	0.868
CVA/TIA	6 (8.4%)	2 (8.3%)	4 (8.5%)	0.980
OSAS	11 (15.4%)	2 (8.3%)	9 (19.1%)	0.240

Data are mean (±SD), n (%). BMI indicates body mass index; AAD, antiarrhythmic drug; LA, left atrium; LVEF, left ventricular ejection fraction; LAVI, left atrial volume index; CVA/TIA, cerebrovascular accident/transient ischemic attack; OSAS, obstructive sleep apnea syndrome; PAF, paroxysmal atrial fibrillation; and PersAF, persistent atrial fibrillation. P-value comparing PAF and PersAF groups.

**Table 2: Procedural data**

	All pts (n=71)	PAF (n=24)	PersAF (n=47)	p
Procedure time (min)	170.5±43.3	158.9±35.0	176.5±46.2	0.111
Radiation time (min)	24.2±7.7	21.0±6.7	25.8±7.8	0.017
Radiation dose (mGy)*	207.0(128.5 - 349.5)	128.5(100.2 - 206.2)	256.0(168.0 - 480.0)	0.002
No of applications*	31.0(18.9-45.0)	21.0(13.2-47.0)	37.0(23.0-47.0)	0.004
Application duration (s)	1749.6±950.7	1417.3±909.4	1919.3±935.2	0.029

Data are mean (±SD), \*median (IQR). PAF indicates paroxysmal atrial fibrillation; PersAF persistent atrial fibrillation. P-value comparing PAF and persAF groups.

### Data collection

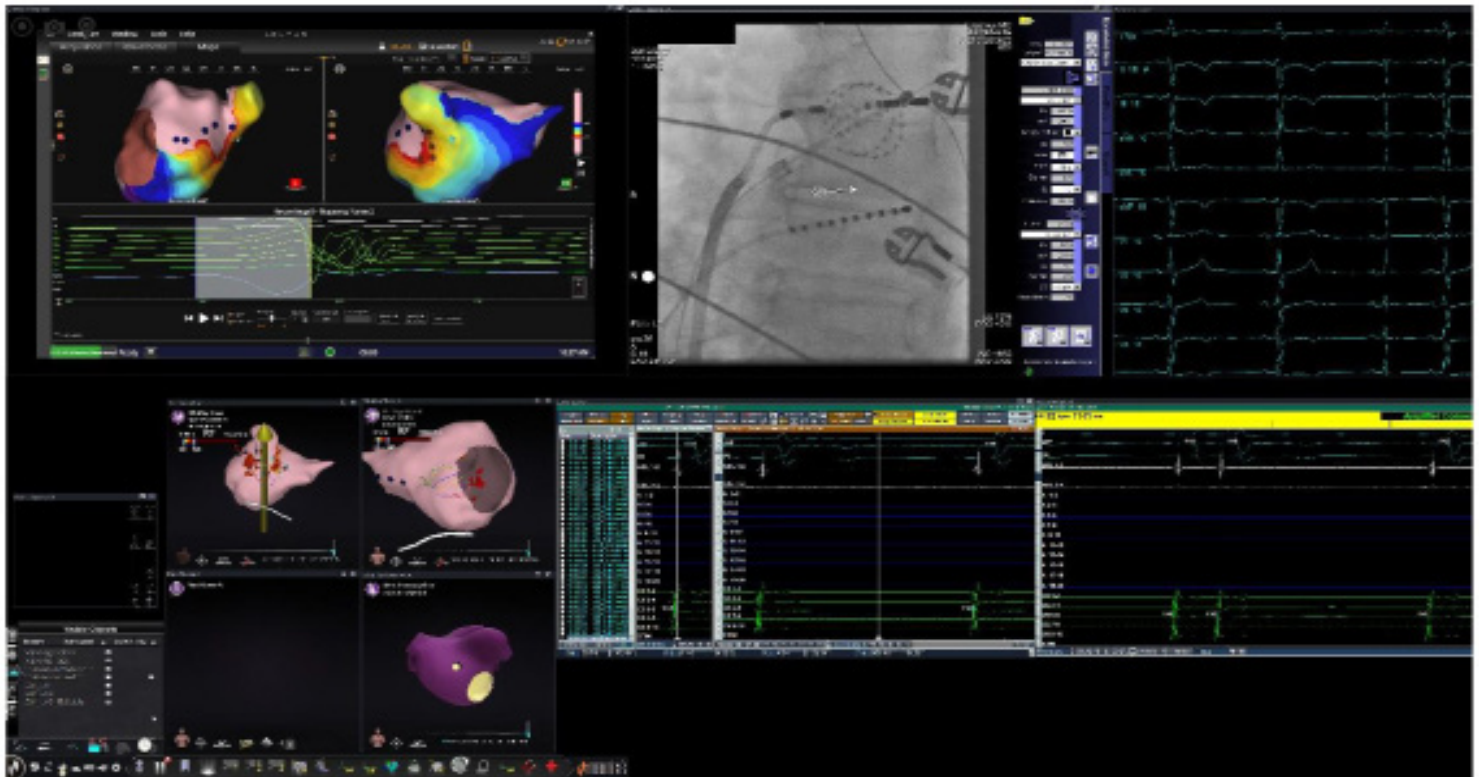Baseline demographic and clinical characteristics from patients were collected from our prospective database using the electronic health records (HiX version 6.2) and analyzed in accordance with the hospital institutional review board policies. Procedural data were derived both from the electronic medical files, as well as from the electronic procedural log files recorded by the AcQMap system. All patients gave informed consent prior to the CA procedure. The following demographic and procedural data were collected from the patients: sex, age, height, weight, BMI, date of procedure, procedure duration time, number of applications, application duration, radiation time and dose, AF termination, rhythm at the end of procedure, acute intra-procedural and post-procedural adverse events. Further, we collected and analyzed clinical data, such as left atrial dimension, left ventricular ejection fraction, comorbidities, and anti antiarrhythmic medication.

### Procedural protocol

All CA procedures were performed using the Niobe ES RMN system under general anesthesia. Vascular access was obtained with femoral venous puncture. After the endocardial anatomical surface of the left atrium was reconstructed with the AcQMap noncontact mapping system, initial PVI was performed for de novo patients and re-isolation of the pulmonary veins was performed when needed for redo patients. CA was performed using the following power settings: 45-50W (posterior wall-anterior wall, respectively), 17mL/min flow rate, maximum 43°C. Patients with persisting arrhythmia and isolated PVs underwent targeted ablation of substrate guided by high-resolution charge density mapping with interpreted propagation history. CA was performed using the MagnoFlush (MedFact, Germany) ablation catheter. In every case, we administered intravenous heparin for anticoagulation, guided by the activated clotting time (> 350 seconds). When patients converted to atrial tachycardia/flutter during the ablation single position maps or SuperMaps (see below) were acquired followed by targeted ablation. Electrical cardioversion (ECV) was performed at the end of the procedures when AF persisted after CA.

### AcQMap-RMN integration

The Niobe ES RMN system (Stereotaxis) is a medical platform technology allowing remote-controlled navigation during interventional procedures. The Stereotaxis system consists of two permanent magnets positioned on either side of the patient. By changing the orientation of the magnets, the orientation of the magnetic field changes, thereby the ablation catheter deflects and can



**Figure 2: AcQMap-RMN integration**

The dipole charge density based high-resolution mapping system (AcQMap) can be fully integrated in the Stereotaxis- Odyssey RMN platform.

be navigated through the vascular and cardiac anatomy. This technique has been previously described elsewhere<sup>10,14</sup>. The e-Contact module is available in Europe but not in the United States, and it provides accurate real-time information on catheter-tissue contact, leading to efficient RMN-guided CA procedures<sup>15</sup>.

The AcQMap system is a noncontact charge density-based mapping technology that allows visualization of global atrial activation. Highly accurate ultrasound-based 3D endocardial anatomy reconstruction is created and combined with high-resolution propagation history maps of electrical activation. The 48-pole noncontact mapping catheter (AcQMap catheter, Acutus Medical, Carlsbad, CA) includes eight biopotential electrodes and eight ultrasound transducers alternately place on each of its six splines. With the use of ultrasound, 3D endocardial chamber surface is reconstructed, which corresponds to the end-diastolic size and shape of the chamber. Global unipolar intracardiac potentials are sensed from the biopotential electrodes of the basket catheter and are processed by an inverse solution to derive the dipolar charge sources at the endocardial surface. The waves of activation are displayed across the 3D anatomy reconstruction through time as high-resolution propagation history maps. The AcQMap system utilizes two different types of mapping: the single position charge density mapping reveals classifiable activation patterns such as focal activation, localized partial rotational activation and localized irregular activation (Figure 1). The SuperMap, allows mapping of both non-sustained and sustained repetitive atrial rhythms. It is a recent addition that allows accumulating of the non-contact measurements by time-aligning different beats acquired at different locations of the chamber during regular rhythms<sup>16</sup>.

### Follow-up

Routine follow-up visits were scheduled at the outpatient clinic of our department for all patients 3 months, 6 months and 12 months after the procedures. 24-h Holter recordings were employed during these visits for documentation of recurrent arrhythmias. For long-term follow-up, patient records were analyzed. We report 6 and 12 months follow-up data in this manuscript.

### Data analysis

Data were analyzed using SPSS 25.0 software. Mean and standard deviation (SD) were calculated for normally distributed continuous variables. Median and interquartile range (IQR) were computed for continuous variables with non-normal distribution. Normality of distribution was assessed with skewness. Descriptive statistics for categorical data were expressed in absolute numbers and percentages. Statistical significance was defined as  $p < 0.05$  (two-tailed). Non-normally distributed variables were analyzed using the Mann-Whitney U-test.

## Results

### Demographic and baseline clinical data

Seventy-one consecutive patients were included in the study (male  $n=47$ , female  $n=24$ ). The mean age of patients was  $60.8 \pm 9.9$  years. Twenty-four patients were included in the paroxysmal (PAF), 47 patients were included in the persistent AF (persAF) patient group. Forty-nine patients had a redo procedure (21 in the PAF group, and

28 in the persAF group), and 22 patients presented with de novo AF. Based on this, 87.5% of the paroxysmal patients underwent redo CA procedures. Therefore, we do not provide efficacy data on de novo PAF patients in this study. The mean pre-procedural left ventricular ejection fraction (LVEF) was  $53.7 \pm 6.0\%$ . Patient demographic and clinical data are summarized in Table 1.

### Primary endpoint: safety data

There were no major intra- or post-procedural complications reported. Two patients were documented with groin hematoma, as minor post-procedural complication (2.8%), not requiring a longer hospitalization time.

### Procedural and radiofrequency ablation data

After completing PVI or redo-PVI, 45 patients underwent AcQMap based substrate ablation. Twenty-four patients converted to atrial tachycardia/flutter (AT/AFL) during the ablation. Performing targeted ablation, 18 out of 24 patients with AT/AFL after RF application(s) converted to sinus rhythm, six underwent ECV. Regarding the localization of AT/AFLs, 6(25.5%) had perimitral localization, 4(16.6%) were localized as cavo-tricuspid isthmus dependent, 3(12.5%) were originating from around the right pulmonary veins, 3(12.5%) had septal origin. The remaining arrhythmias either had a left atrial roof dependent, a perinodal origin, or converted to sinus rhythm before the possibility of mapping. The mean procedure time was  $170.5 \pm 43.3$  min, mean ablation time  $1749.6 \pm 950.7$  s, mean radiation time  $24.2 \pm 7.7$  min, and mean radiation dose was 207.0 (IQR 128.5 - 349.5) mGy. In the PAF group, radiation doses (128.5 vs 256.0 mGy,  $p=0.002$ ) and application numbers (21.1 vs 37.0,  $p=0.004$ ) were lower, ablation times were shorter (1312.5 vs 1919.3 s,  $p=0.029$ ) compared to the pers AF patient group (Table 2). Comparing patients undergoing substrate ablation with patients undergoing (redo) PVI-only, we documented higher numbers of application (36.0 vs 23.0,  $p=0.012$ ), higher radiation doses (255.0 vs 142.0 mGy,  $p=0.025$ ), and radiation times ( $26.2 \pm 8.2$  vs  $20.4 \pm 5.1$  min,  $p=0.006$ ) in patients requiring substrate ablation. Termination of AF occurred in 31 patients. ECV was performed in 35 cases. Acute procedural success was achieved in 68/71 (95.7%) of the cases.

### Follow-up data

Nine patients in the persAF group had documented AF recurrence at the 6-month follow-up visits while 34 patients (72.3%) were AF-free at the end of the 12-month follow-up period. Nine patients had AT/AFL recurrence (12.6%). The overall freedom from atrial arrhythmias was 68.0% in the persAF patient group. Six patients underwent a redo procedure (8.4%), all from the persAF patient group during the study period. Three out of these 6 patients presented with documented recurrence even after the repeated procedures.

## Discussion

The main finding of our report is that the AcQMap-RMN integration offers a safe and personalized treatment option for patients with AF, with high success rates and satisfying acute and 1-year follow up results.



### Major advantages of RMN guided ablation

One of the crucial requirements for a successful CA procedure is accurate substrate location, followed by optimal radiofrequency energy delivery provided by good tissue contact. Regarding catheter movements, manual catheters are often limited by their predefined curve, which requires additional manual skills to maneuver in some cases. Furthermore, some anatomic regions are difficult to reach<sup>14</sup>. The RMN technology was introduced in clinical electrophysiology in 2001, proven to be effective and safe in CA procedures<sup>10,14</sup>. The RMN provides precise and stable catheter manipulation, and practically eliminates acute complications during procedures<sup>6,15</sup>. As previous studies proved, the RMN system shows superiority to conventional manual methods in ventricular tachycardia ablation<sup>11,17-19</sup>. Furthermore, it has been proven feasible and non-inferior to manual methods in AF ablation, although new modules such as the e-Contact module, were clearly necessary to improve outcomes<sup>20,21</sup>. Our data suggests that integrating this novel dipole charge density based mapping technology in the RMN system, offers further opportunities in CA. It has the potential of AF source detection on top of providing real time and highly accurate imaging modality (echocardiography) to create the anatomy.

### AcQMap imaging and mapping system

The suboptimal results of PVI-alone procedures particularly in persistent AF reported in many studies, suggest that the optimal AF treatment will be more individually tailored, and it requires a more personalized approach. This instigated the development of several mapping systems, aiming to investigate the underlying mechanisms of AF. The newest version of the CARTO system incorporates a panoramic mapping system, which was designed to identify AF drivers, however it is not capable of real-time entire chamber arrhythmia analysis and it is not integrated in the RMN system. Dipole charge density mapping provides real-time echo-based anatomical chamber reconstructions superimposed by global chamber non-contact mapping even during unstable rhythms. Thus, it offers the possibility of a unique individualized ablation strategy planning for patients. A recently published study by Pope et al reports that charge density mapping facilitates identification of complex AF patterns<sup>16</sup>. By identifying stable regions of irregular activation, we are able to recognize atrial structural abnormalities, which can represent important sites for CA approaches<sup>22</sup>. Besides, its use has been proven safe for the patients and operators as well, with reduced radiation times and lower risk of major complications<sup>7,23</sup>. The results of the UNCOVER AF trial demonstrate that the AcQMap guided CA for non-PV triggers in addition to PVI offers a targeted treatment for persAF with high long-term success rates<sup>24</sup>. They report a higher complication rate (including major complications such as cardiac tamponade and stroke/TIA) as compared to our current results suggesting that the procedural safety can further improve with the addition of RMN to the AcQMap system. The 1-year success rate in persistent AF patients was almost identical to our results confirming the efficacy of dipole charge density mapping in AF ablation. Compared to the UNCOVER AF trial, where 129 patients were included from 13 centers across Europe and Canada, our single-center study including 71 AF patients is a large-scale report of a unique approach combining robotics with a novel mapping modality.

### AcQMap-RMN integration

With AcQMap-RMN integration we can now combine the benefits of real-time entire chamber anatomical and activation mapping with the safety and accuracy of RMN. There are no previous studies reporting on the AcQMap-RMN integration. Our study confirms that despite integrating a new complex diagnostic device in the Stereotaxis RMN, the safety profile does not necessarily deteriorate. This is despite the fact that we treated a rather complex patient population consisting of dominantly persistent AF patients or presenting with complex arrhythmias after multiple redo procedures. Considering this, our relatively high 1-year success rates are very promising.

### Limitations

The retrospective nature of the present study and the lack of a control group might have introduced bias, although we included a relatively high number of patients with AF undergoing CA using the novel AcQMap combined with RMN. The AcQMap technology requires fluoroscopic confirmation of position in some cases, therefore radiation times and doses are relatively high. The high reported success rates in paroxysmal AF ablation are attributable to the high number of redo patients in the PAF group. Therefore, the number of de novo procedures in the PAF group are low, and we reported on success rates only for persAF patients.


### Conclusions

Catheter ablation procedures guided by the AcQMap-RMN demonstrate promising safety, high acute and long-term success rates, with low recurrence rates in patients with AF. With the combination of these two systems, patients can benefit from a more individualized treatment option with promising long-term results.

### References

1. Westerman S, Wenger N. Gender Differences in Atrial Fibrillation: A Review of Epidemiology, Management, and Outcomes. *Curr Cardiol Rev*. 2019;15(2):136-44.
2. January CT, Wann LS, Calkins H, Chen LY, Cigarroa JE, Cleveland JC, Jr, et al. 2019 AHA/ACC/HRS Focused Update of the 2014 AHA/ACC/HRS Guideline for the Management of Patients With Atrial Fibrillation: A Report of the American College of Cardiology/American Heart Association Task Force on Clinical Practice Guidelines and the Heart Rhythm Society in Collaboration With the Society of Thoracic Surgeons. *Circulation*. 2019;140(2):e125-e51.
3. Scherr D, Khairy P, Miyazaki S, Aurillac-Lavignolle V, Pascale P, Wilton SB, et al. Five-year outcome of catheter ablation of persistent atrial fibrillation using termination of atrial fibrillation as a procedural endpoint. *Circ Arrhythm Electrophysiol*. 2015;8(1):18-24.
4. Tzou WS, Marchlinski FE, Zado ES, Lin D, Dixit S, Callans DJ, et al. Long-term outcome after successful catheter ablation of atrial fibrillation. *Circ Arrhythm Electrophysiol*. 2010;3(3):237-42.
5. Miyazaki S, Shah AJ, Khaet O, Derval N, Matsuo S, Wright M, et al. Remote magnetic navigation with irrigated tip catheter for ablation of paroxysmal atrial fibrillation. *Circ Arrhythm Electrophysiol*. 2010;3(6):585-9.
6. Elisabeth Notén AM, Kis Z, Akka F, Bhagwandien R, Wijchers S, Yap SC, et al. Robotic navigation shows superior improvement in efficiency for atrial fibrillation ablation. *J Atr Fibrillation*. 2019;11(5):2108.
7. Jin QJ, Pehrson S, Jacobsen PK, Chen XU. Efficacy and Safety of Atrial Fibrillation Ablation Using Remote Magnetic Navigation: Experience from 1,006 Procedures. *J Cardiovasc Electrophysiol*. 2016;27 Suppl 1:S23-8.

8. Akca F, Theuns DA, Abkenari LD, de Groot NM, Jordaens L, Szili-Torok T. Outcomes of repeat catheter ablation using magnetic navigation or conventional ablation. *Europace*. 2013;15(10):1426-31.
9. Adragao PP, Cavaco D, Ferreira AM, Costa FM, Parreira L, Carmo P, et al. Safety and Long-Term Outcomes of Catheter Ablation of Atrial Fibrillation Using Magnetic Navigation versus Manual Conventional Ablation: A Propensity-Score Analysis. *J Cardiovasc Electrophysiol*. 2016;27 Suppl 1:S11-6.
10. Faddis MN, Chen J, Osborn J, Talcott M, Cain ME, Lindsay BD. Magnetic guidance system for cardiac electrophysiology: a prospective trial of safety and efficacy in humans. *J Am Coll Cardiol*. 2003;42(11):1952-8.
11. Bauernfeind T, Akca F, Schwagten B, de Groot N, Van Belle Y, Valk S, et al. The magnetic navigation system allows safety and high efficacy for ablation of arrhythmias. *Europace*. 2011;13(7):1015-21.
12. Grace A, Willems S, Meyer C, Verma A, Heck P, Zhu M, et al. High-resolution noncontact charge-density mapping of endocardial activation. *JCI Insight*. 2019;4(6).
13. Chierchia GB, Sieira J, Vanderper A, Osorio TG, Bala G, Stroker E, et al. Substrate mapping of the left atrium in persistent atrial fibrillation: spatial correlation of localized complex conduction patterns in global charge-density maps to low-voltage areas in 3D contact bipolar voltage maps. *J Interv Card Electrophysiol*. 2021;62(3):539-47.
14. Faddis MN, Blume W, Finney J, Hall A, Rauch J, Sell J, et al. Novel, magnetically guided catheter for endocardial mapping and radiofrequency catheter ablation. *Circulation*. 2002;106(23):2980-5.
15. Noten AME, Geczy T, Yap SC, Kis Z, Szili-Torok T. Introducing a novel catheter-tissue contact feedback feature in robotic navigated catheter ablation: Utility, feasibility, and safety. *Heart Rhythm O2*. 2020;1(2):103-10.
16. Pope MTB, Leo M, Briosa EGA, Betts TR. Clinical utility of non-contact charge density 'SuperMap' algorithm for the mapping and ablation of organized atrial arrhythmias. *Europace*. 2021.
17. Turagam MK, Atkins D, Tung R, Mansour M, Ruskin J, Cheng J, et al. A meta-analysis of manual versus remote magnetic navigation for ventricular tachycardia ablation. *J Interv Card Electrophysiol*. 2017;49(3):227-35.
18. Noten AME, Hendriks AA, Yap SC, Mol D, Bhagwandien R, Wijchers S, et al. Contact feedback improves 1-year outcomes of remote magnetic navigation-guided ischemic ventricular tachycardia ablation. *Int J Cardiol*. 2020;315:36-44.
19. Qian P, De Silva K, Kumar S, Nadri F, Samanta R, Bhaskaran A, et al. Early and long-term outcomes after manual and remote magnetic navigation-guided catheter ablation for ventricular tachycardia. *Europace*. 2018;20(suppl\_2):ii11-ii21.
20. Virk SA, Kumar S. Remote Magnetic Versus Manual Catheter Navigation for Atrial Fibrillation Ablation: A Meta-Analysis. *Circ Arrhythm Electrophysiol*. 2019;12(10):e007517.
21. Szili-Torok T, Akca F. Remote magnetic navigation in atrial fibrillation. *Expert Rev Med Devices*. 2012;9(3):249-55.
22. Pope MT, Kuklik P, Briosa EGA, Leo M, Mahmoudi M, Paisey J, et al. Spatial and temporal variability of rotational, focal, and irregular activity: Practical implications for mapping of atrial fibrillation. *J Cardiovasc Electrophysiol*. 2021;32(9):2393-403.
23. Akca F, Onsesveren I, Jordaens L, Szili-Torok T. Safety and efficacy of the remote magnetic navigation for ablation of ventricular tachycardias--a systematic review. *J Interv Card Electrophysiol*. 2012;34(1):65-71.
24. Willems S, Verma A, Betts TR, Murray S, Neuzil P, Ince H, et al. Targeting Nonpulmonary Vein Sources in Persistent Atrial Fibrillation Identified by Noncontact Charge Density Mapping: UNCOVER AF Trial. *Circ Arrhythm Electrophysiol*. 2019;12(7):e007233.



# Radiofrequency Ablation Of Paroxysmal And Persistent Atrial Fibrillation Using EnSite Precision Mapping System And Robotic Magnetic Navigation: The Efficacy, Long-Term Follow-Up Outcome And Recurrence Risk Factors

Shipeng Dang<sup>1,2</sup>, Christian Jeons<sup>2</sup>, Peter Karl Jacobsen<sup>2</sup>, Steen Pehrson<sup>2</sup>, Ru-Xing Wang<sup>1</sup>, Xu Chen<sup>2</sup>

<sup>1</sup>Department of Cardiology, The Affiliated Wuxi People's Hospital of Nanjing Medical University, Qingyang Road 299, Wuxi, China

<sup>2</sup>Department of Cardiology, The Heart Centre, Rigshospitalet, Copenhagen University Hospital, Inge Lehmanns Vej 7, Copenhagen, Denmark

## Abstract

**Background:** This research is focused on robotic magnetic navigation (RMN) when used in conjunction with a non-integrated 3D mapping system to perform catheter ablation. Currently, only CARTO and AcQMap mapping system are fully integrated with RMN for performing catheter ablation. This study aimed to evaluate the efficacy of combining the not yet integrated mapping system EnSite Precision with RMN for atrial fibrillation (AF) ablation.

**Methods:** A total of 103 consecutive patients with AF (paroxysmal, 61.2%) underwent catheter ablation with EnSite Precision and RMN. Left atrial (LA) mapping data was acquired using a circular mapping catheter and pulmonary vein isolation (PVI) was performed with magnetic RMN navigated catheter in all cases. The procedural data, procedure-related complications and AF free recurrence rates were analyzed between paroxysmal and persistent AF groups. Cox regression was performed to analyze the recurrence risk factors.

**Results:** There were no significant differences in the total procedure time, fluoroscopy time, LA mapping time and radiofrequency energy. Ablation and mapping times were longer in the persistent AF group than in the paroxysmal AF group ( $P = 0.028$ ). More complex fractionated atrial electrograms were ablated in the persistent AF group than in the paroxysmal AF group ( $P = 0.008$ ). No major complications occurred in either group. After  $11.3 \pm 5.3$  months of follow-up, the AF-free rates were 79.0% for paroxysmal AF and 61.0% for persistent AF, respectively. Cox-regression analysis demonstrated that female gender (HR: 3.029, 95% CI: 1.315-6.976,  $P = 0.009$ ) and left ventricular ejection fraction (LVEF)  $\leq 40\%$  (HR: 4.250, 95% CI: 1.639-11.019,  $P = 0.003$ ) were factors associated with a higher AF recurrence.

**Conclusions:** Collaboration of EnSite Precision and RMN is effective in patients with both paroxysmal and persistent AF. Female gender and low LVEF were two significant predictors of AF recurrence.

## Introduction

Atrial fibrillation (AF) is a common arrhythmia with increasing prevalence globally and traditionally poor outcomes even when treated with drugs<sup>1,2</sup>. Catheter ablation (CA) is an established and promising AF treatment. Electrical pulmonary vein isolation (PVI) via CA is a

widely accepted basic procedure for AF treatment and achieves high success rates in paroxysmal AF, although success rates are still low in chronic AF<sup>3,4</sup>. Additional ablations, such as trigger ablation, substrate modification, defragmentation, or linear ablation, have been reported to improve treatment results<sup>5,6</sup>.

## Key Words

Robotic Magnetic Navigation, Atrial Fibrillation, EnSite Precision, Catheter Ablation, Risk Factor.

## Corresponding Author

Dr. Xu Chen,  
Department of Cardiology, The Heart Centre, Rigshospitalet, Copenhagen University Hospital, Inge Lehmanns Vej 7, 2100 Copenhagen, Denmark

Reliable three-dimensional (3D) electro-anatomical mapping systems (EAMs) are required for AF ablation in order to avoid complications and improve success rates<sup>7</sup>. Currently, the most common EAMs for AF ablation are the CARTO (Biosense Webster, Baldwin Park, CA, USA) and the EnSite NavX system (Abbot, Chicago, IL, USA, St. Paul, MN, USA)<sup>8,9</sup>. These systems have shown promising results for AF ablation and helped pave the way to a new era of



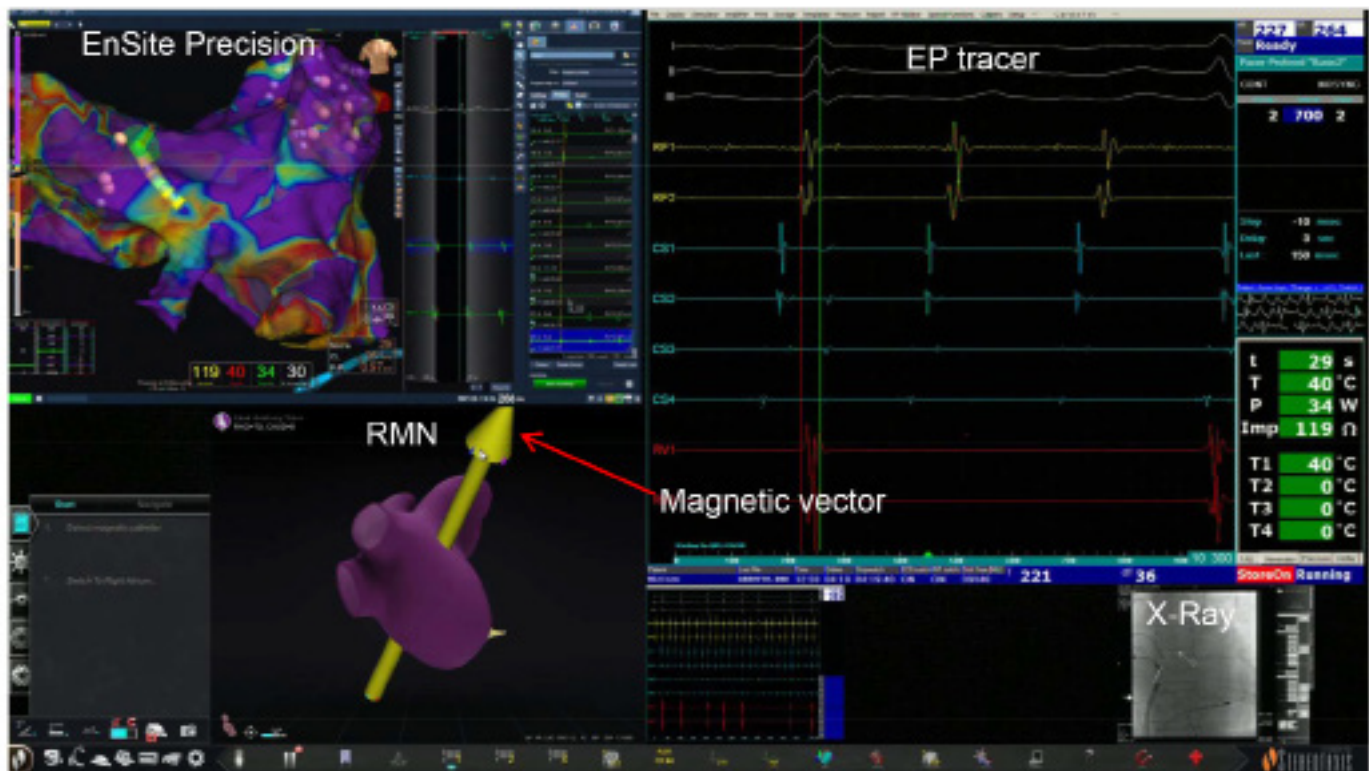


Figure 1:

The interface of Odyssey system. EnSite Precision, electrophysiological recording system, X-Ray and RMN were shown on the interface of Odyssey system. The magnetic vector could be only seen and moved in RMN panel but not in EnSite Precision panel.

substrate characterization and individual ablation strategies<sup>7</sup>. The CARTO system is a reliable sensor based 3D mapping system for AF treatment. In contrast, the EnSite NavX system, which is based on an impedance-based tracking technology, is capable of creating 3D maps of intracardiac and tracking intracardiac electrodes<sup>10</sup>. The new generation of this system, EnSite Precision, has combined both impedance and magnetic technologies with much more precision and improved stability<sup>9</sup>. We reported that EnSite Precision combined with robotic magnetic navigation (RMN) can be effectively used for AF ablation without impacting the overall procedural time<sup>11</sup>. However, the long-term follow-up outcome of the RMN and EnSite Precision combination has not yet been reported.

In this study, we sought to determine the acute procedural efficacy, safety and long-term outcome of the EnSite Precision and RMN collaboration in AF ablation. We found that RMN combined with the EnSite Precision mapping system is effective and safe for catheter ablation in AF.

## Methods

### Study population

In this retrospective study, a total of 103 consecutive AF patients, including 62 paroxysmal and 41 persistent AF patients, with a mean age of  $59.6 \pm 10.6$  years, were enrolled for AF ablation using RMN and EnSite Precision from April 2016 to October 2017. All patients previously failed with antiarrhythmic drug (AAD) therapy or failed to maintain sinus rhythm if they chose to discontinue AAD therapy due to side effects. All patients signed an informed consent form prior

to ablation procedure. In Denmark, a retrospective study comparing the outcome of two patient groups after radiofrequency ablation does not require approval from the local ethical committee. AF diagnosis in each patient was documented by 12-lead electrocardiograms (ECGs) or Holter monitor. All patients received effective anticoagulation therapy with warfarin (target international normalized ratio [INR] of 2–3) or novel anticoagulants for more than 1 month. Anticoagulation therapy continued during the perioperative period of the AF ablation procedure. In all patients, a transoesophageal echocardiography was performed to exclude atrial thrombus prior to ablation. Patients were excluded from the study if (1) they were younger than 18 years, or (2) they had echocardiographically or angiographically determined severe valvular disease.

Paroxysmal and persistent AF were defined according to current guidelines<sup>2</sup>. Paroxysmal AF was defined as self-terminating within the first 48 hours and up to 7 days after onset, documented by previous routine or Holter ECGs. Persistent AF was defined as any AF episode lasting longer than 7 days or requiring termination by cardioversion, either with drugs or by direct cardioversion.

### Procedural preparation

After femoral vein puncture, a 6F steerable catheter (Inquiry, Abbott, Inc.) and a 5F quadripolar catheter (Medtronic, Inc.) were placed in the coronary sinus and in the right ventricle apex, respectively. One transseptal puncture was performed under hemodynamic pressure and fluoroscopic monitoring. A single bolus of 75 IU/kg body weight of heparin was administered after transseptal puncture. Additional

heparin (1,000-3000 IU) was administered every hour of the procedure, according to the ACT. Surface ECGs and endocardial electrograms were monitored and recorded continuously with an EP tracer (Schwarzer Cardiotek, Inc.). Left atrial (LA) anatomical mapping was acquired with a circular magnetic mapping catheter (Advisor FL, Sensor Enabled; Abbott, Inc.) manually. LA mapping acquisition time was designated as the advisor mapping time. Subsequently, the circular catheter was replaced by the open-irrigated magnetic catheter (Celsius®ThermoCool® RMT, Biosense Webster, Inc.) for precise mapping and ablation navigated by the Niobe ES™ system (Stereotaxis, Inc. St. Louis, MO). Odyssey Vision™ system (Stereotaxis, Inc.) was used to gather EnSite Precision mapping system, X-Ray, electrophysiological recording system and RMN. As EnSite Precision mapping system was not integrated with the RMN system, the movement of the magnetic vector was performed on an anatomical model in the Navigant panel while watching in the EnSite panel (Figure 1). The time for this procedure was designated as ablation & mapping time. A catheter-advancement system (Cardiodrive®,

Stereotaxis, Inc., St. Louis, MO, USA) was used to control catheter advancement and retraction from the control room.

### Catheter ablation

All patients underwent PVI and additional complex fractionated atrial electrograms (CFAEs) ablation was performed after PVI in persistent AF patients. CFAEs were defined as those with “two or more deflections and/or perturbation of the baseline with continuous deflection of a prolonged activation complex”<sup>12</sup>. Procedure end-point was electrical isolation of the PVs as verified by repeated mapping for residual potentials around the entire circumference of the PV ostia after obtaining sinus rhythm (SR) by ablation or electrical cardioversion. Linear ablations were applied when macro-reentrant atrial tachycardias were detected during the procedure. Termination and non-inducibility of the tachycardia was the endpoint. Radiofrequency (RF) ablation was performed with a target temperature not exceeding 43°C. The power was set at 35 - 40 W with a flush rate of 10 mL/min for the anterior wall and 30 - 35 W for the posterior wall. Fentanyl was administered to all patients to ease pain.

### Follow-up

Patients continued antiarrhythmic and anticoagulation treatment during the blanking period of 3 months post procedure. All patients were routinely evaluated in the outpatient clinic by their local cardiologist at intervals of 3 months, 6 months, 1 year, and thereafter, once a year. Twelve-lead ECGs, event recording or Holter recordings were performed on patients with symptomatic palpitations. In addition to the scheduled follow-up visits, patients were instructed to contact a physician at any time when suspecting AF recurrence or tachycardia for ECG and/or Holter documentation. Recurrence was defined as symptomatic and/or asymptomatic AF or AT episode > 30 s confirmed by ECG or Holter recordings. Long-term success was defined as no AF or AT recurrence. An additional ablation procedure was recommended for patients who had documented AF recurrences.

### Statistical analysis

Continuous variables were expressed as mean ± standard deviation. Categorical variables were expressed as ratios and percentages. Levene's test was used to assess the homogeneity of variance. Normally distributed data were compared using the independent Student's t test and non-normally distributed data were compared using the Mann-Whitney U test. Chi-square was used for categorical variables. The probability of long-term AF recurrence between the two groups was determined by the Kaplan-Meier analysis with Mantel-Cox (Log-rank) test. Univariable and multivariable COX-regression analyzes were performed to identify predictors of AF long term recurrence at follow-up. All tests were performed with a two-tailed significance level of 0.05. SPSS 17.0 software was used for data analysis.

### Results

#### Baseline characteristics of patients

In this retrospective study, 103 patients were included, with a mean age of 59.6 ± 10.6 years. Among them, 62 patients and 41 patients had paroxysmal and persistent AF, respectively. The clinical baseline characteristics of the patients in these two groups were nearly identical. There were no statistically significant differences between paroxysmal

**Table 1: Baseline Characteristics of Patients**

Parameters	Paroxysmal AF (n=62)	Persistent AF (n=41)	Total (n=103)	P value
Age (years)	58.6 ± 11.2	61.2 ± 9.5	59.6 ± 10.6	0.222
Gender, (Female, %)	16 (25.8)	12 (29.3)	28 (27.2)	0.699
BMI	27.2 ± 5.3	30.0 ± 5.4	28.4 ± 5.5	0.024*
Smoking	27 (43.5)	13 (31.7)	40 (38.8)	0.227
Alcohol	16 (25.8)	14 (34.1)	30 (29.1)	0.362
Ejection fraction	58.7 ± 12.3	54.6 ± 14.3	57.1 ± 13.2	0.122
CHA2DS2-VASc score	1.0 ± 1.0	1.3 ± 0.9	1.1 ± 1.0	0.072
Common PV	12 (19.4)	3 (7.3)	15 (14.6)	0.090
Left common PV	11 (17.7)	3 (7.3)	14 (13.6)	0.131
Right common PV	1 (1.6)	0 (0.0)	1 (1.0)	0.414
<b>CIED</b>				
PM	3 (4.8)	3 (7.3)	6 (5.8)	0.599
ICD	2 (3.2)	0 (0.0)	2 (1.9)	0.245
CRT-P/D	2 (3.2)	1 (2.4)	3 (2.9)	0.816
Ablation procs	1.5 ± 0.7	1.6 ± 0.6	1.5 ± 0.7	0.492
<b>Redo cases</b>				
2nd	15 (24.2)	17 (41.5)	32 (31.1)	0.064
3rd	7 (11.3)	3 (7.3)	10 (9.7)	0.505
<b>Diseases</b>				
HBP, (N, %)	18 (29.0)	17 (41.5)	35 (34.0)	0.192
SHD, (N, %)	15 (24.2)	15 (36.6)	30 (29.1)	0.175
Stroke, (N, %)	2 (3.2)	0 (0.0)	2 (1.9)	0.245
T2DM, (N, %)	2 (3.2)	7 (17.1)	9 (8.7)	0.015*
<b>Drug</b>				
ACEI/ARB	18 (29.0)	24 (58.5)	42 (40.8)	0.003*
β-blocker	31 (50.0)	26 (63.4)	57 (55.3)	0.180
Anti-arrhythmia medication	39 (62.9)	31 (75.6)	70 (68.0)	0.176
Anti-coagulants	46 (74.2)	34 (82.9)	80 (77.7)	0.298
Statins	20 (32.3)	14 (34.1)	34 (33.0)	0.842

Abbreviations: BMI, body weigh index; PV, pulmonary vein; CIED, Cardiovascular implantable electronic device; PM, pacemaker; ICD, implantable cardioverter defibrillator; CRT-P/D, cardiac resynchronization therapy-pace/ defibrillator; HBP, hypertension; SHD, structural heart diseases.

**Table 2: Procedural outcome**

Parameters	Paroxysmal AF (n=62)	Persistent AF (n=41)	Total (n=103)	P value
Procedure time (min)	113.9 ± 27.9	124.8 ± 33.8	118.3 ± 30.7	0.078
Advisor mapping time (min)	4.3 ± 1.2	4.4 ± 1.2	4.4 ± 1.2	0.667
Ablation & mapping time (min)	56.0 ± 24.3	67.6 ± 26.0	60.6 ± 25.5	0.028
RFCA time (min)	26.4 ± 18.5	34.1 ± 27.1	29.5 ± 22.9	0.103
Fluoroscopy time (min)	5.6 ± 3.5	5.3 ± 2.9	5.5 ± 3.3	0.717
X-ray dose (Gycm2)	4.6 ± 6.1	5.8 ± 6.0	5.1 ± 6.1	0.304
CFAE ablation (N, %)	3 (4.8)	9 (22.0)	12 (11.7)	0.008
RA ablation (N, %)	8 (12.9)	5 (12.2)	13 (12.6)	0.916
<b>AF termination mode</b>				
Ablation (N, %)	11 (17.7)	4 (9.8)	15 (14.6)	0.261
DCC (N, %)	9 (14.5)	35 (85.4)	44 (42.7)	< 0.001
Ablation + DCC (N, %)	0 (0.0)	2 (4.9)	2 (1.9)	0.079
<b>Complication</b>				
Heparin (U)	6503.6 ± 1433.0	7600.0 ± 2073.0	6960.4 ± 1802.3	0.005
Fentanyl (U)	236.3 ± 92.3	219.2 ± 79.4	229.1 ± 87.0	0.355

DCC, Direct Current Cardioversion.

and persistent AF groups in terms of sex, age, left ventricular ejection fraction (LVEF), smoking, alcohol, CHA2DS2-VASc score, common pulmonary vein, cardiovascular implantable electronic device and ablation time. However, the body mass index (BMI) and diabetes ratio were significant higher in persistent AF group than in paroxysmal AF group. ACEI/ARB was administered to more persistent AF patients (Table 1).

### Procedural characteristics

There were no significant differences of procedure time (113.9 ± 27.9 vs. 124.8 ± 33.8 min,  $P = 0.078$ ), advisor mapping time (4.3 ± 1.2 vs. 4.4 ± 1.2 min,  $P = 0.667$ ), radiofrequency ablation time (26.4 ± 18.5 vs. 34.1 ± 27.1 min,  $P = 0.103$ ), fluoroscopy time (5.6 ± 3.5 vs. 5.3 ± 2.9 min,  $P = 0.717$ ), X-ray dose (4.6 ± 6.1 vs. 5.8 ± 6.0 min,  $P = 0.304$ ) and fentanyl dose (236.3 ± 92.3 vs. 219.2 ± 79.4 U,  $P = 0.35$ ) between paroxysmal and persistent AF patients. Ablation and mapping time was longer in the persistent AF group than in the paroxysmal AF group (56.0 ± 24.3 vs. 67.6 ± 26.0 min,  $P = 0.028$ ), suggesting that persistent AF may require additional time for precise and sufficient mapping. One third of paroxysmal AF patients induced AF during mapping and ablation, with 55% of them could be terminated by ablation and 45% of them requiring cardioversion. Most persistent AF patients needed cardioversion and only about 10% percent of them were terminated by ablation. Therefore, the persistent AF group more often required direct current cardioversion than the paroxysmal AF group ( $P < 0.001$ ). No major or minor procedural complications occurred in either group (Table 2).

### Recurrence rates of AF

The recurrence rates of paroxysmal AF were 21.0% and those of persistent AF were 39.0% after a mean follow-up time of 11.3 ± 5.3 months with 3-month blanking interval (Table 3). The overall AF-free survival was 71.8% (Figure 2A). The incidences of AF-free survival were 79.0% and 61.0% in paroxysmal and persistent AF patients, respectively (Figure 2B). AF recurrence rate for the second ablation

was significantly higher in persistent AF patients than in paroxysmal AF patients (Table 3). The Kaplan-Meier analysis showed that the overall incidence of AF free-survival was lower in patients with three ablations (40%) than in those with only one (81.3%,  $P = 0.01$ ) or two ablations (72.1%,  $P = 0.031$ ) (Figure 3A). In the paroxysmal AF group, the incidence of AF-free survival was remarkably higher in patients with two ablations (100%) versus in those patients with one (75%) or three (57.1%) ablations (Figure 3B). In the persistent AF group, there was no statistical difference in the AF-free survival incidence between patients with one (66.7%) and two ablations (64.7%,  $P = 0.995$ ). However, patients with three ablations experienced 100% AF recurrence during 12-month follow-up (Figure 3C).

### Predictors of AF recurrence

Cox regression from Univariate analysis demonstrated that AF recurrence was associated with female gender, coronary heart disease (CHD) and low LVEF (Figure 4A-C,  $P < 0.05$ ) but not with age, gender, smoking, alcohol, BMI, common PV, hypertension and diabetes ( $P > 0.05$ ). Cox regression from multivariate analysis showed that female gender (HR: 3.029, 95% CI: 1.315-6.976,  $P = 0.009$ ) and LVEF ≤ 40% (HR: 4.250, 95% CI: 1.639-11.019,  $P = 0.003$ ) were two independent risk factors to predict postoperative AF recurrence (Table 4).

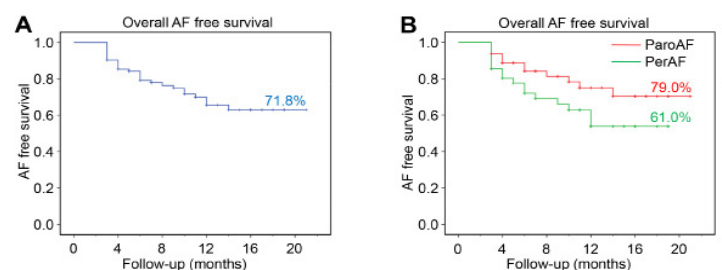
## Discussion

### 4.1 Main findings

This study, to the best of our knowledge, is the first to evaluate long term outcomes using EnSite Precision and RMN for AF ablation. The main findings of this study were as follows: (1) AF ablation using EnSite Precision and RMN was effective and safe, both in patients with paroxysmal AF and in those with persistent AF; (2) The efficiency and safety of the procedure was not impeded by non-integration of EnSite system with RMN.

### 4.2 Mapping and ablation of AF with EnSite Precision

The EnSite 3D mapping system (EnSite Velocity) has been applied to AF ablation for more than ten years<sup>5,13,14</sup>. This system has become increasingly adopted by electrophysiologists with the ten years procedure experience, practice and technology development, especially after the EnSite Precision release. EnSite Precision uses a hybrid of impedance and magnetic field technology to accurately locate diagnostic



**Figure 2:** Kaplan-Meier analysis of time to AF recurrence after last ablation procedure. (A) Overall AF free survival curve. (B) The AF free survival curve of paroxysmal AF and persistent AF.



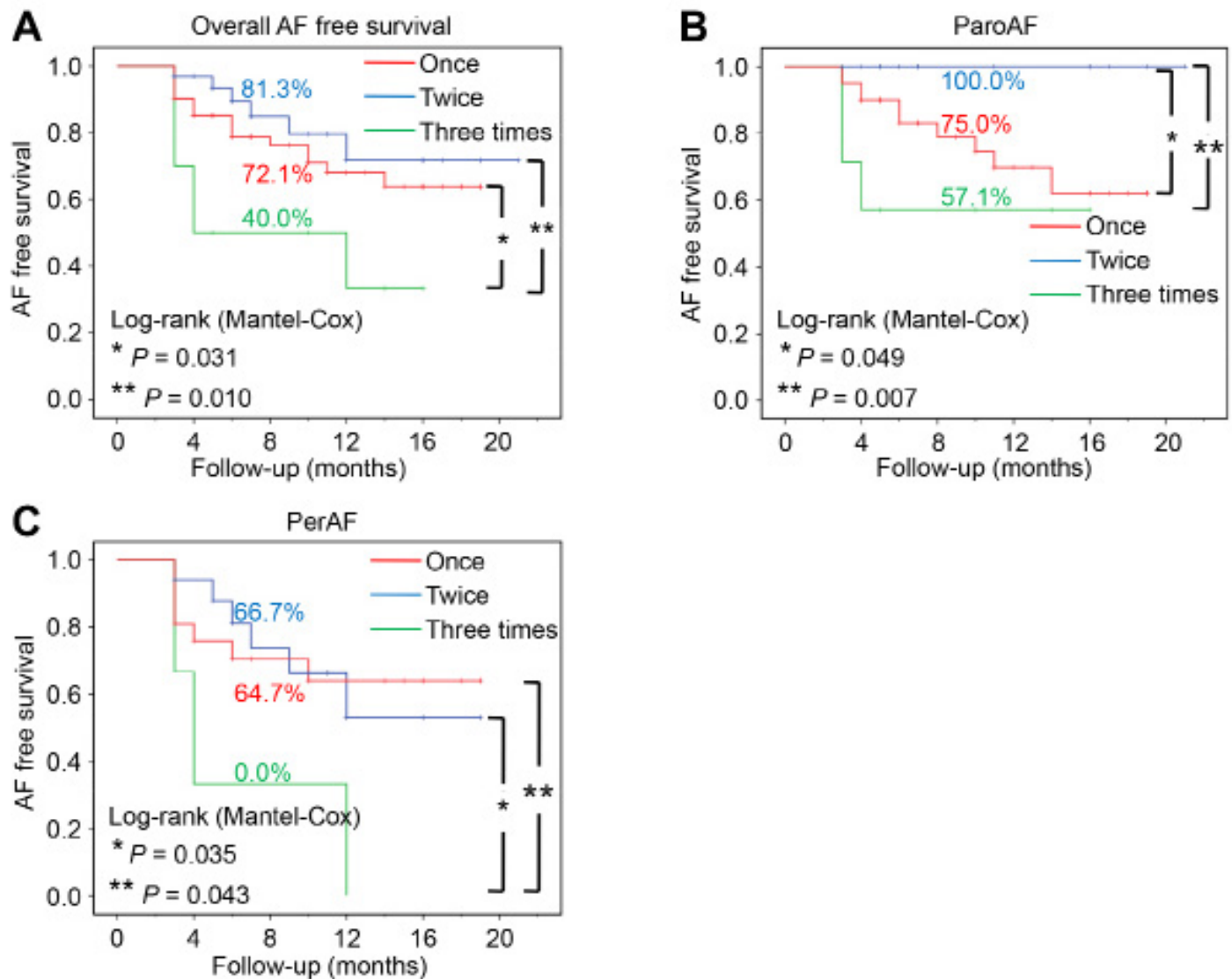


Figure 3:

**Kaplan-Meier analysis of time to AF recurrence after last ablation procedure with different ablation times. (A) Overall AF free survival curve with one, two or three ablations. (B) AF free survival curve with one, two or three ablations in patients with paroxysmal AF. (C) AF free survival curve with one, two or three ablations in patients with persistent AF.**

and ablation catheters within the body. The resolution, accuracy, and stability of this system are much higher compared to the those of its predecessors, EnSite NavX and EnSite Velocity<sup>9</sup>. In comparison with Carto system, EnSite Precision is an open platform compatible with almost any EP catheter. Using this novel integrated impedance and magnetic-field-based electroanatomical mapping system, a zero-fluoroscopic approach could be achieved in most SVT cases without compromising procedure time, success rates or complications<sup>15</sup>. It has also been proven safe and effective for catheter ablation of premature ventricular contractions and scar-based ventricular tachycardia<sup>16,17</sup>. In addition, the EnSite Precision mapping system was also helpful in achieving left bundle branch area pacing with the guidance of 3D maps created with this mapping system. This technique may be a valuable tool to reduce the learning curve of implanters with minimal experience in left bundle branch area pacing<sup>18</sup>. Gramlich et al. reported that, prior to ablation, left atrial voltage mapping using EnSite Precision or Velocity in patients with persistent atrial fibrillation undergoing cryoballoon PVI, made the extent of left atrial low-voltage areas capable

of predicting AF-free survival<sup>19</sup>. Previously, it was reported that the LA mapped by EnSite Precision was stable and reliable for AF ablation without impacting overall procedural time when combined with RMN, which was comparable to the CARTO-3 system<sup>11</sup>. Borlich et al

Table 3: Follow-up

Parameters	Paroxysmal AF (n=62)	Persistent AF (n=41)	Total (n=103)	P value
Follow-up time (month)	11.0 ± 5.6	11.8 ± 4.7	11.3 ± 5.3	0.588
Total recurrence	13 (21.0)	16 (39.0)	29 (28.2)	0.093
<b>Time to recurrence</b>				
Early recurrence (3-6 month)	9 (14.5)	11 (26.8)	20 (19.4)	0.122
Late recurrence (> 6 month)	4 (6.5)	5 (12.2)	9 (8.7)	0.312
<b>Ablation times to recurrence</b>				
1st	10 (16.1)	7 (17.1)	17 (16.5)	0.899
2nd	0 (0.0)	6 (14.6)	6 (5.8)	0.002
3rd	3 (4.8)	3 (7.3)	6 (5.8)	0.599

presented a workflow that made both CARTO-3 and EnSite Precision systems valuable for AF interventional treatment, uniting three-dimensional LA mapping, image integration and contact force based ablation approach<sup>8</sup>. In this retrospective study, the procedural outcomes of 103 consecutive AF patients were analyzed. It was determined that a reliable LA map can be quickly acquired in 5 minutes using EnSite Precision with a circular mapping catheter for either paroxysmal or persistent AF. CS catheter middle electrode was setup as the system reference in all cases. Map dislocation occurred in some procedures, but in each case it could be corrected by moving the CS catheter back according to its shadow. RFCA and fluoroscopy times showed no significant difference between the two groups. However, the ablation and mapping times were lower in the paroxysmal group than in the persistent group, suggesting that persistent AF requires more time for precise mapping. Using the EnSite Precision system, PVI was achieved in all cases. These acute results indicate that this novel mapping system facilitates catheter ablation of AF.

### 4.3 Combination of EnSite Precision and RMN in AF ablation

At present, only CARTO and AcQMap (Acutus Medical Inc, Carlsbad, CA) mapping systems are integrated with RMN. The movement of the mapping and ablation catheter can be controlled in the CARTO system, which made catheter operation very convenient<sup>20</sup>. Owing to the better stability and maneuverability of magnetic ablation catheters, many studies have demonstrated that acute PVI success rates in MNS-guided catheter ablation are as good as manual navigation ablation<sup>21-25</sup>. Although the EnSite Precision system is not integrated with RMN, they are compatible with each other and can be similarly used for mapping and ablation of ventricular arrhythmias and AF<sup>11,16</sup>. In the present study, the LA geometry map was acquired using a circular mapping catheter manually; then precise mapping of LA and ablation were performed with the open-irrigated magnetic catheter navigated from the RMN system's software. This workflow proved as stable and effective as integrated operation of CARTO-3 with RMN system. Previous reports suggested that RMN technique was associated with lower fluoroscopy times when compared with manual catheter navigation during AF ablation<sup>23-25</sup>. The fluoroscopy time of the current study was  $5.5 \pm 3.3$  min, which was shorter than these studies<sup>24,25</sup>. Other studies have demonstrated that the incidence of serious complications, such as cardiac perforation, pulmonary vein stenosis and left atrial esophageal fistula was much lower in MNS-navigated ablation when compared with manual ablation<sup>22,23,26</sup>. In the present study, no serious complications occurred in either paroxysmal or persistent AF patients.

### 4.4 Risk factors for AF recurrence after ablation using EnSite Precision

AF recurrences remain a common issue after catheter ablation, often requiring repeated ablation procedures<sup>27</sup>. Therefore, the accurate prediction of AF recurrences in patients undergoing AF ablation has important clinical significance<sup>28</sup>. Univariate and multivariate Cox-regression analyzes were performed to identify the risk factors of AF recurrence after ablation using EnSite Precision and RMN. The results showed that AF recurrence was not correlated with sex, age, smoking, alcohol, BMI, common PV, hypertension and diabetes, but was correlated with female gender, CHD and low LVEF. Furthermore, we found that female gender and low LVEF were two independent

risk factors for the recurrence of AF. Indeed, the female gender has been previously reported to be an independent risk factor and strongly associated with arrhythmia recurrence in patients undergoing ablation<sup>29-31</sup>. Therefore, our results were consistent with these findings. Regarding LVEF, it has not been previously reported as an AF recurrence risk factor, as it was almost normal in several preceding studies<sup>27,28</sup>. In our study, fourteen patients with LVEF  $\leq 40\%$  met the inclusion criteria were included, and the recurrence of AF in these patients was significantly higher than among normal LVEF patients.

### 4.5 Limitations

Although this is the first study to report follow-up data on AF ablation using EnSite Precision, the number of patients was relatively low and additional large-scale, multi-center studies with longer follow-up duration periods are needed to validate the results. Additionally, this study is limited by the inherent nature of a retrospective study and, therefore, the results demonstrated should be further evaluated by prospective studies.

### Conclusions

The EnSite Precision system is compatible with RMN to perform AF ablation. Combining these two technologies is both safe and effective for AF ablation with achievement of desired long term outcomes. Female gender and low LVEF are two significant independent predictors of late AF recurrence.

### Acknowledgements

The authors wish to thank the technical staff of the Cardiac Catheterization Laboratory for their help.

### Conflict of interest

There are no conflicts of interest.

### Funding

This study was supported by grants from the National Natural Science Foundation of China (81770331), Jiangsu province Young Medical Talents (QNRC2016185), Top Talent Support Program for young and middle-aged people of Wuxi Health Committee (BJ016) and Program of Wuxi translational medicine center (2020ZHYB14).

**Table 4:** Univariate and multivariate Cox proportional Hazard modeling results of AF recurrence after catheter ablation using RMN and EnSite Precision

Variables	Univariate model			Multivariate model		
	HR	95% CI	P	HR	95% CI	P
Age > 60	1.108	0.529-2.324	0.785			
Gender (Female)	2.078	0.987-4.375	0.047*	3.029	1.315-6.976	0.009*
Smoking	1.893	0.905-3.959	0.090			
Alcohol	1.171	0.528-2.596	0.698			
BMI > 25	0.538	0.216-1.342	0.184			
LVEF < 40%	2.790	1.181-6.591	0.019*	4.250	1.639-11.019	0.003*
Common PV	0.244	0.033-1.806	0.167			
Hypertension	1.562	0.746-3.269	0.237			
CHD	2.542	1.049-6.163	0.039*			
Diabetes mellitus	1.916	0.703-5.226	0.204			

BMI, body mass index; CI, confidence interval; LVEF, left ventricle ejection fraction; PV, pulmonary vein; CHD, Coronary heart diseases; \*P < 0.05

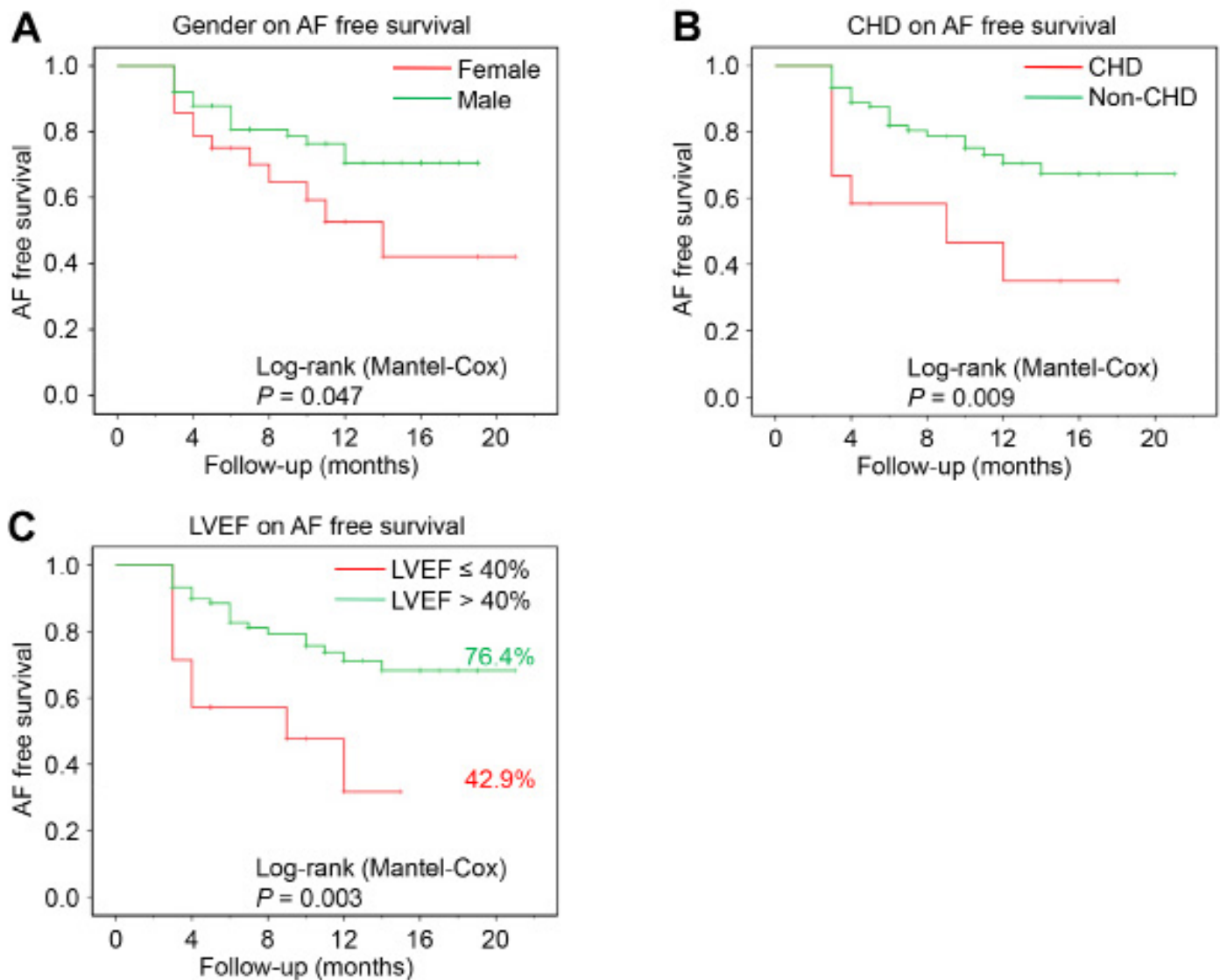


Figure 4:

**Kaplan-Meier analysis of time to AF recurrence after last ablation procedure with different risk factors. (A) Gender on AF free survival. (B) CHD on AF free survival. (C) LVEF on AF free survival.**

## References

- Kallistratos MS, Poulimenos LE, Manolis AJ. Atrial fibrillation and arterial hypertension. *Pharmacol Res.* 2018;128:322-326.
- Kirchhof P, Benussi S, Kotecha D, et al. 2016 ESC Guidelines for the management of atrial fibrillation developed in collaboration with EACTS. *Europace.* 2016;18(11):1609-1678.
- Schneider R, Lauschke J, Tischer T, et al. Pulmonary vein triggers play an important role in the initiation of atrial flutter: Initial results from the prospective randomized Atrial Fibrillation Ablation in Atrial Flutter (Triple A) trial. *Heart rhythm* 2015;12(5):865-871.
- Verma A, Jiang CY, Betts TR, et al. Approaches to catheter ablation for persistent atrial fibrillation. *N Engl J Med.* 2015;372(19):1812-1822.
- Willems S, Klemm H, Rostock T, et al. Substrate modification combined with pulmonary vein isolation improves outcome of catheter ablation in patients with persistent atrial fibrillation: a prospective randomized comparison. *Eur Heart J.* 2006;27(23):2871-2878.
- Seitz J, Bars C, Theodore G, et al. AF Ablation Guided by Spatiotemporal Electrogram Dispersion Without Pulmonary Vein Isolation: A Wholly Patient-Tailored Approach. *J Am Coll Cardiol.* 2017;69(3):303-321.
- Nedios S, Sommer P, Bollmann A, Hindricks G. Advanced Mapping Systems To Guide Atrial Fibrillation Ablation: Electrical Information That Matters. *J Atr Fibrillation.* 2016;8(6):1337-1344.
- Borlich M, Iden L, Kuhnhardt K, Paetsch I, Hindricks G, Sommer P. 3D Mapping for PVI- Geometry, Image Integration and Incorporation of Contact Force Into Work Flow. *J Atr Fibrillation.* 2018;10(6):1795.
- Borlich M, Sommer P. Cardiac Mapping Systems: Rhythmia, Topera, EnSite Precision, and CARTO. *Card Electrophysiol Clin.* 2019;11(3):449-458.
- Eitel C, Hindricks G, Dages N, Sommer P, Piorkowski C. EnSite Velocity cardiac mapping system: a new platform for 3D mapping of cardiac arrhythmias. *Expert Rev Med Devices.* 2010;7(2):185-192.
- Lin C, Pehrson S, Jacobsen PK, Chen X. Initial experience of a novel mapping system combined with remote magnetic navigation in the catheter ablation of atrial fibrillation. *J Cardiovasc Electrophysiol.* 2017;00:1-6.



12. Lau DH, Zeemering S, Maesen B, Kuklik P, Verheule S, Schotten U. Catheter Ablation Targeting Complex Fractionated Atrial Electrogram in Atrial Fibrillation. *J Atr Fibrillation*. 2013;6(3):907.
13. Liu X, Wang XH, Gu JN, Zhou L, Qiu JH. Electroanatomical systems to guided circumferential pulmonary veins ablation for atrial fibrillation: initial experience from comparison between the EnSite/NavX and CARTO system. *Chin Med J (Engl)*. 2005;118(14):1156-1160.
14. Khaykin Y, Oosthuizen R, Zarnett L, et al. CARTO-guided vs. NavX-guided pulmonary vein antrum isolation and pulmonary vein antrum isolation performed without 3-D mapping: effect of the 3-D mapping system on procedure duration and fluoroscopy time. *J Interv Card Electrophysiol*. 2011;30(3):233-240.
15. Walsh KA, Galvin J, Keaney J, Keelan E, Szeplaki G. First experience with zero-fluoroscopic ablation for supraventricular tachycardias using a novel impedance and magnetic-field-based mapping system. *Clin Res Cardiol*. 2018;107(7):578-585.
16. Dang S, Jons C, Jacobsen PK, Pehrson S, Chen X. Feasibility of a novel mapping system combined with remote magnetic navigation for catheter ablation of premature ventricular contractions. *J Arrhythm*. 2019;35(2):244-251.
17. Launer H, Clark T, Dewland T, Henrikson CA, Nazer B. An automated fractionation mapping algorithm for mapping of scar-based ventricular tachycardia. *Pacing Clin Electrophysiol*. 2019;42(8):1133-1140.
18. Vijayaraman P, Panikkath R, Mascarenhas V, Bauch TD. Left bundle branch pacing utilizing three dimensional mapping. *J Cardiovasc Electrophysiol*. 2019;30(12):3050-3056.
19. Gramlich M, Maleck C, Marquardt J, et al. Cryoballoon ablation for persistent atrial fibrillation in patients without left atrial fibrosis. *J Cardiovasc Electrophysiol*. 2019;30(7):999-1004.
20. Ernst S. Catheter Ablation: General Principles and Advances. *Card Electrophysiol Clin*. 2017;9(2):311-317.
21. Yuan S, Holmqvist F, Kongstad O, et al. Long-term outcomes of the current remote magnetic catheter navigation technique for ablation of atrial fibrillation. *Scand Cardiovasc J*. 2017;51(6):308-315.
22. Proietti R, Pecoraro V, Di Biase L, et al. Remote magnetic with open-irrigated catheter vs. manual navigation for ablation of atrial fibrillation: a systematic review and meta-analysis. *Europace*. 2013;15(9):1241-1248.
23. Aksu T, Bozyel S, Golcuk E, Yalin K, Guler TE. Atrial Fibrillation Ablation Using Magnetic Navigation Comparison With Conventional Approach During Long-Term Follow-Up. *J Atr Fibrillation*. 2015;8(3):1276.
24. Adragao PP, Cavaco D, Ferreira AM, et al. Safety and Long-Term Outcomes of Catheter Ablation of Atrial Fibrillation Using Magnetic Navigation versus Manual Conventional Ablation: A Propensity-Score Analysis. *J Cardiovasc Electrophysiol*. 2016;27 Suppl 1:S11-16.
25. van den Bruck JH, Sultan A, Luker J, et al. Remote vs. conventional navigation for catheter ablation of atrial fibrillation: insights from prospective registry data. *Clin Res Cardiol*. 2019;108(3):298-308.
26. Danon A, Shurrab M, Nair KM, et al. Atrial fibrillation ablation using remote magnetic navigation and the risk of atrial-esophageal fistula: international multicenter experience. *J Interv Card Electrophysiol*. 2015;43(2):169-174.
27. Kornej J, Schumacher K, Sommer P, et al. Very late arrhythmia recurrences in patients with sinus rhythm within the first year after catheter ablation: The Leipzig Heart Center AF Ablation Registry. *Europace*. 2019;21(11):1646-1652.
28. Zhao XX, Li KL, Wang RX, et al. Comparisons of efficacy, safety, and recurrence risk factors of paroxysmal and persistent atrial fibrillation catheter ablation using robotic magnetic navigation system. *Clin Cardiol*. 2019;42(4):418-424.
29. Schreiber D, Rostock T, Frohlich M, et al. Five-year follow-up after catheter ablation of persistent atrial fibrillation using the stepwise approach and prognostic factors for success. *Circ Arrhythm Electrophysiol*. 2015;8(2):308-317.
30. Mesquita J, Ferreira AM, Cavaco D, et al. Development and validation of a risk score for predicting atrial fibrillation recurrence after a first catheter ablation procedure - ATLAS score. *Europace*. 2018;20(FI\_3):f428-f435.
31. Sugumar H, Nanayakkara S, Chieng D, et al. Arrhythmia recurrence is more common in females undergoing multiple catheter ablation procedures for persistent atrial fibrillation: Time to close the gender gap. *Heart rhythm* 2020;17(5 Pt A):692-698.



## Remote Magnetic Catheter Ablation of Ventricular Arrhythmias with Rhythmia™ High Resolution Mapping System

Johan D. Aasbo<sup>1</sup>, Kristie Schneider<sup>1</sup>, Gery F. Tomassoni<sup>1</sup>

<sup>1</sup>Baptist Health Lexington, Lexington KY

### Abstract

**Background:** Stereotaxis™ remote magnetic navigation (RMN) and high density mapping with the Rhythmia™ system have been individually shown to be safe and effective for ablation of ventricular arrhythmias (VAs). No studies have described the conjoint use of Stereotaxis™ with Rhythmia™ for the ablation of VAs.

**Methods:** We describe our single center experience of conjoint Rhythmia™ mapping of VAs and catheter ablation with RMN in a retrospective cohort of ten patients, five with extensive structural heart disease (SHD) due to ischemic and nonischemic cardiomyopathies requiring recurrent ICD shocks despite antiarrhythmic medications, and five with structurally normal hearts.

**Results:** All patients underwent successful procedures targeting their VAs with conjoint Rhythmia™ mapping and Stereotaxis™ RMN. No complications occurred. Over a follow up period ranging between 2 - 25 months (average of  $9 \pm 6$  months), one SHD patient received a single shock for VF. No sustained VAs were recorded in the other SHD patients. No patients with normal hearts had VA recurrence.

**Conclusions:** Conjoint use of Stereotaxis™ RMN and Rhythmia™ to treat VAs in patients with and without SHD is technically feasible and in our ten patient series, was safe and effective.

### Introduction

Catheter ablation using a remote magnetic navigation (RMN) system (Stereotaxis™, St. Louis, MO) has served as a viable alternative to manual catheter ablation since the robotic system's introduction in 2003. The RMN system was integrated exclusively with a 3-dimensional mapping system (CARTO, J&J, Irvine, CA) and required the use of a proprietary ablation catheter, Thermocool RMT (CARTO, J&J, Irvine, CA). This integration led to CARTO being the predominant mapping modality used with the Stereotaxis™ system. The exclusive nature of the collaboration however has led to a limited choice of three-dimensional mapping systems and ablation catheters for physicians. In addition, since the latest iterations of CARTO software have not been incorporated in the RMN system, many of the updated software advantages are not available.

Progress in several areas of VA ablation has been achieved in recent years. A body of literature has found RMN to be a safe and effective


### Key Words

Rhythmia, High density mapping, Stereotaxis, Remote magnetic navigation, Catheter ablation, Ventricular tachycardia

### Corresponding Author

Johan Aasbo, DO, FACC, FHRS  
1720 Nicholasville Rd., Ste. 400, Lexington.

alternative to manual catheter ablation for the ablation of ventricular arrhythmias (VAs).<sup>1-6</sup> RMN has been utilized consistently as an effective and safe tool for ablation of VAs since our center acquired it in 2004. Substrate ablation in its various forms during sinus or ventricular pacing has developed into an attractive alternative to mapping during VAs in patients with structural heart disease. These patients often have multiple hemodynamically unstable VAs. Repeated VA inductions, attempts at entrainment, and activation mapping during VT can lead to progressive hemodynamic compromise and frequent rescue shocks thus increasing the risk of procedural morbidity and mortality.<sup>7-20</sup> In recent years, there has been considerable interest in high resolution mapping of VAs utilizing the Rhythmia™ mapping system (Boston Scientific, Natick, MA). Potential benefits of mapping with Rhythmia™ include the rapid acquisition of thousands of points via the Orion mapping catheter (featuring 64 0.4mm printed unidirectional electrodes) and consistent detection/annotation of ultra-low amplitude signals arising from diseased myocardial tissue.<sup>21-25</sup> Studies have suggested incremental benefit of Rhythmia's algorithm Lumipoint™ for the automatic detection and rapid annotation of abnormal electrograms including late potentials (LPs).<sup>26-28</sup> Regions of anisotropy, slowed conduction and isochronal "crowding" identified during either sinus or ventricular paced rhythms (rather than during VT) correlate with diastolic VT corridors and effective sites for ablation further erode the need for mapping during VT.<sup>29-30</sup>



**Figure 1:** Schematic of connections between Rhythmia, Smart Ablate Connection box, Smart Ablate RF generator and Thermocool RMT ablation catheter

A pair of Boston Scientific D130302 cables is required to connect both the Thermocool RMT catheter and the SmartAblate RF generator to the Boston Scientific manufactured SmartAblate Connection box.

With this background, we sought to explore the possibility of conjoint utilization of high density Rhythmia™ mapping with Stereotaxis™ specifically for the remote magnetic ablation of VAs.

## Methods

### Patient enrollment

Ten consecutive patients to have ablation of their VAs with the conjoint use of Stereotaxis™ RMN and Rhythmia™ high density mapping were evaluated. This study was performed with approval of the IRB at Baptist Hospital Lexington. All patients provided written informed consent. The procedures were performed by one of two operators. The patients were referred for clinical evaluation to our arrhythmia clinic and deemed appropriate for catheter ablation of their VAs by one or both of the operators.

The patients in the study were approached in two different ways depending upon their cardiac substrate: patients 1,4,5,6 and 7 had significant structural heart disease (SHD) and were included in the structural heart disease group, whereas patients 2,3,8,9 and 10 did not and were included in the normal heart group (Table 1).

Patients in the SHD group all had significant arrhythmia recurrence despite antiarrhythmic drug therapy. Patients in this group were scheduled with general anesthesia as is our routine clinical practice.

Patients in the normal heart group all had highly symptomatic recurrent PVCs and/or ventricular tachycardia that were refractory or intolerant to medical therapy. Patients in this group had their procedures performed with moderate sedation.

For all patients in the study, antiarrhythmic medications were discontinued 3 days prior to the procedure or, in the case of amiodarone, 90 days prior to the procedure, as per our standard clinical practice. Anticoagulants were held prior to the procedure and continued post

procedure at the discretion of the operator.

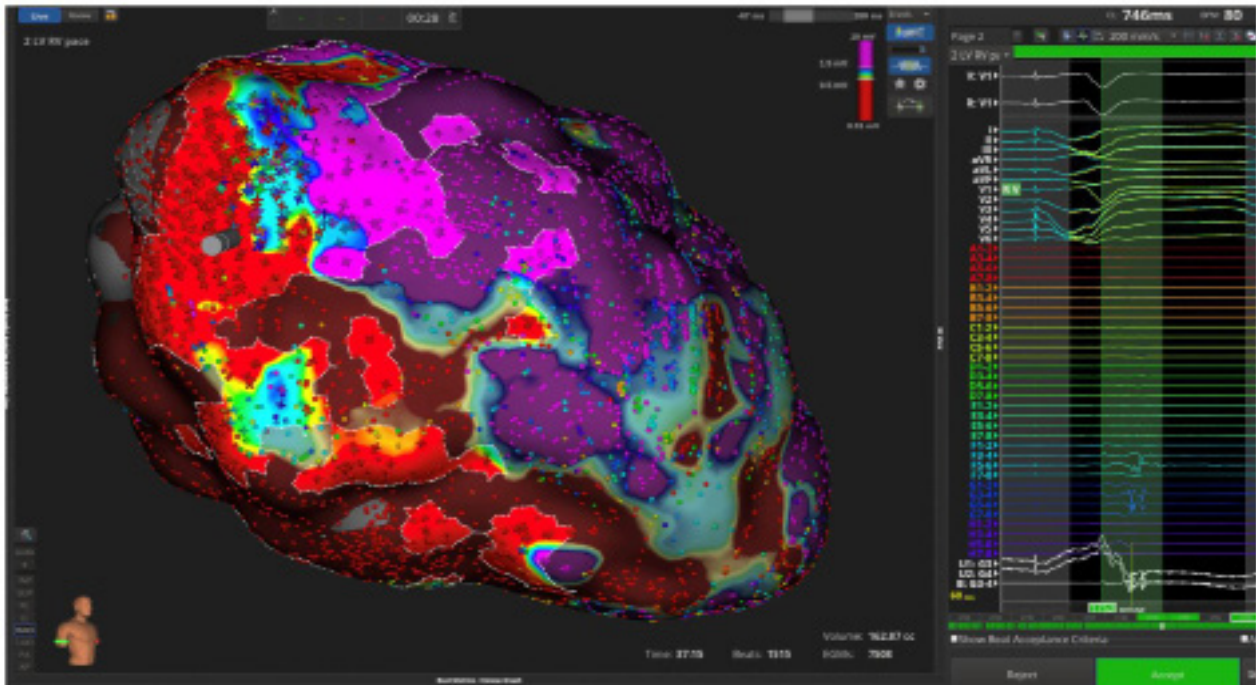
### Procedural details

All procedures were performed at Baptist Lexington Hospital in the EP laboratory equipped with Stereotaxis™. After receiving anesthesia, patients were prepared and draped in routine sterile fashion. Unilateral or bilateral femoral vascular access was obtained based upon operator discretion. Vascular access was obtained using ultrasound and the standard Seldinger technique. All patients immediately after vascular access were given an intravenous heparin bolus of 150 units per kilogram followed by a continuous infusion of 50 units per kilogram per hour. Heparin infusion rates were adjusted to target an activated clotting time between 350 and 400 seconds per our institutional nomogram. A woven JSN penta-polar electrophysiology catheter (Boston Scientific, Natick, MA) was placed at the apex of the right ventricle. Four of the electrodes on this catheter are located at the distal portion of the catheter and allow for pacing and recording of the right ventricle. The fifth electrode is more proximal, lying typically in the inferior vena cava when the tip of the catheter is in the right ventricle. This fifth electrode was utilized as a unipolar reference for the Rhythmia™ system (rather than Wilson's central terminal). Care was taken to ensure that this catheter remained stable throughout the procedure. Intracardiac and surface signals were recorded using the CardioLab recording system (GE, Milwaukee, WI). Intracardiac signals were band pass filtered (10–400 Hz). Cardiac stimulation was performed with a Bloom stimulator (Fischer Medical, Wheat Ridge, Colorado). An 8 French phased array intra-cardiac echocardiography probe (ICE) was used for all cases (Siemens, Germany). The ICE catheter was used throughout the procedure to monitor catheter position with respect to critical anatomy (such as the coronary cusps, coronary artery ostia, etc), assess intermittently for complications such as pericardial effusion, and to assist with transseptal puncture if necessary. Mapping was performed exclusively with the Rhythmia mapping system and the Orion 64 electrode electrophysiology catheter (Boston Scientific, Natick, MA). A 3.5 mm non-Nav Celsius RMT Thermocool open-irrigated tip ablation catheter was used for all ablation (J&J, Irvine, CA, Biosense Webster catalog CR7TCSIRT). Transseptal punctures were performed with braided deflectable sheaths and a BRK needle (Agilis, Abbott Medical, St Paul, MN). Femoral arterial access for mapping of the left ventricle with the Orion catheter was obtained with a 8.5 French short sheath. In one patient, ablation was performed in the right coronary cusp with the use of a LAMP sheath (Abbott Medical, St Paul, MN) placed into the ascending aorta via the right common femoral artery. In a separate single patient, epicardial mapping was performed after percutaneous pericardial access was obtained with a Touhy needle (Codman Inc, Rayham, MA), a short 9 French sheath and standard methods for percutaneous pericardial access.<sup>31</sup> Patients who received general anesthesia had continuous intra-arterial blood pressure monitoring via the left radial artery or left common femoral arterial line.

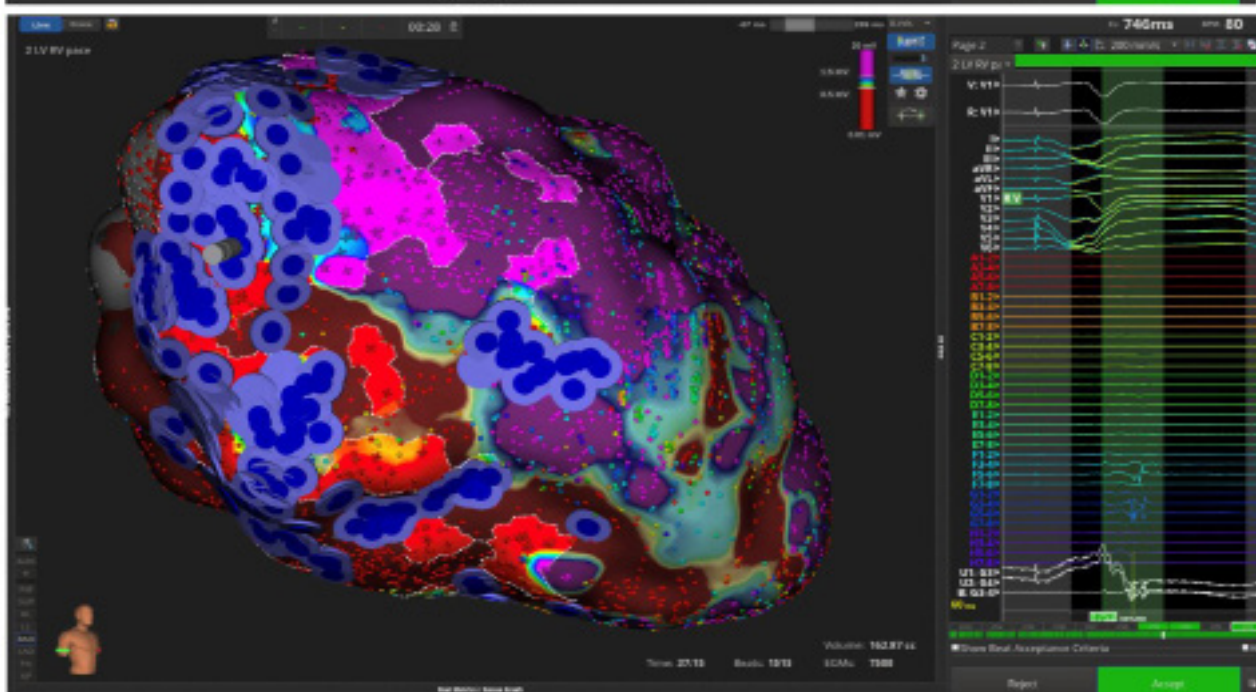
Rhythmia™ uses a hybrid of magnetic and impedance location technologies. A magnetic field generator is located under the procedure table. Magnetic tracking is achieved with this magnetic field generator in combination with a back patch and a catheter equipped with a proprietary magnetic location sensor. Impedance tracking is achieved via ECG leads RA, LA, LL, V1, V3, and V6 and an impedance reference



2a



2b



**Figure 2a and 2b:** Patient 4, a 72 year old male with ischemic cardiomyopathy and recurrent ICD therapy.

This left ventricular endocardial map was obtained during right ventricular pacing. Lumipoint areas indicating late potentials are highlighted and overlaid on voltage mapping (> 1.5 mV indicated as purple, < 0.5 mV indicated as red, abnormal voltage as a gradient colors, see color bar scheme top right). The electrograms on the right side of the figures were recorded with the Orion catheter at the location indicated and the virtual roving catheter at approximately 10 o'clock. The light blue markers with dark blue core indicate ablation locations.

within the body, which for this study was the tip of the RV catheter. Rhythmia™ is able to track catheters that are not equipped with a proprietary magnetic location sensor, such as the Thermocool RMT. This feature first requires that an impedance field map is generated for each chamber mapped by a catheter equipped with a magnetic location sensor. The Orion catheter was first used to simultaneously generate an anatomic shell, perform voltage mapping and, when applicable, an activation map of the VA, all-the-while generating the impedance field map required for subsequent visualization and tracking of the ablation catheter.

The Stereotaxis™ rare earth magnetics by nature cannot be “de-activated,” however in the “stowed” position, pivoted away from the patient, the magnetic field generated by Stereotaxis™ does not interfere with Rhythmia’s magnetic navigation. Impedance tracking is unencumbered by the magnets. Workflow for all patients in this study was such that mapping was performed first with the Orion catheter with the magnets positioned in the “stowed” position. After mapping was complete, the ablation phase of the procedure commenced; the Orion catheter was removed from the chamber being targeted in favor of the ablation catheter, the magnets were moved in the “navigate” position and magnetic catheter navigation was commenced by the operator in the control room.

### Integration of Rhythmia with Stereotaxis

Video output from Rhythmia™ was sent to the Stereotaxis Odyssey monitor via fiber optic cable. This permitted the map and all information displayed on the Rhythmia™ workstation to be duplicated in a separate window within the Odyssey workstation, alongside fluoroscopy, recording system data, ICE images, etc. Both the operator and mapping specialist retained control over Rhythmia™ via a duplicate wireless keyboard and mouse at the Odyssey workstation. A pair of SmartAblate connection cables (Boston Scientific, catalog number D130302) connected the Rhythmia™ CPU, the Rhythmia™ SmartAblate connection box, the Thermocool ablation catheter and the SmartAblate RF generator (Biosense Webster) (Figure 1). The Rhythmia™ system was connected to the recording system in the usual fashion.

### Mapping and Ablation

An electrophysiology study was performed in all patients using standard protocols. The SHD group patients had procedural endpoints of the elimination of all LPs in areas of abnormal voltage as well as homogenization of areas of scar. Scar was defined as less than 0.5mV. Normal tissue was defined as greater than 1.5 mV. Abnormal tissue was defined as having voltage of less than 1.5 mV but greater than 0.5mV. Protocols specifically intended to induce ventricular tachycardia were not performed. The focus of ablation was substrate modification. Mapping was performed with obligate pacing from the RV to elucidate LPs.<sup>28</sup> LPs were defined as bipolar electrograms inscribed after the end of the surface QRS complex, separated by an isoelectric interval prior to the local ventricular electrogram. Voltage maps were analyzed using the Rhythmia Lumipoint™ algorithm to filter for LPs. This algorithm allowed the operator to highlight areas with LPs and view areas with LPs as a highlighted overlay on the voltage map. Areas of abnormal voltage that contained LPs as revealed by Lumipoint™ were then manually confirmed by the operators and

subsequently targeted for ablation. Activation during ventricular paced rhythm was carefully analyzed for regions of anisotropic conduction, slowed conduction and isochronal crowding. When present in regions of abnormal voltage, these areas were targeted for ablation. When areas targeted for ablation were adjacent to dense scar, ablation was extended to create a contiguous ablation lesion set with the goal of the elimination of possible reentrant corridors.

The patients in the normal heart group underwent activation mapping of their clinical VAs. Sedation was kept at a minimum to ensure patient comfort and to maximize the occurrence of VAs. IV isoproterenol was titrated up to 10 mcg/kg/minute, as needed, to elicit and map clinical VAs. The activation timing reference was determined by operator preference. The VA site of origin (SOO), defined as the earliest bipolar activation with EGM bipolar activation at least 15 milliseconds earlier than the earliest surface QRS onset and QS unipolar morphology, was targeted for ablation. The initial chamber mapped was the chamber thought to be most likely chamber of origin based upon 12 lead ECG VA characteristics.<sup>32-33</sup> If the earliest bipolar EGM onset did not precede the earliest QRS onset by at least 15 milliseconds, or if the apparent SOO displayed on the map was not discrete, adjacent cardiac chambers were then mapped. All chambers mapped were displayed simultaneously on the Rhythmia mapping system. The clinical endpoint of ablation was non-inducibility of clinical VAs with isoproterenol infusion and ventricular pacing induction attempts.

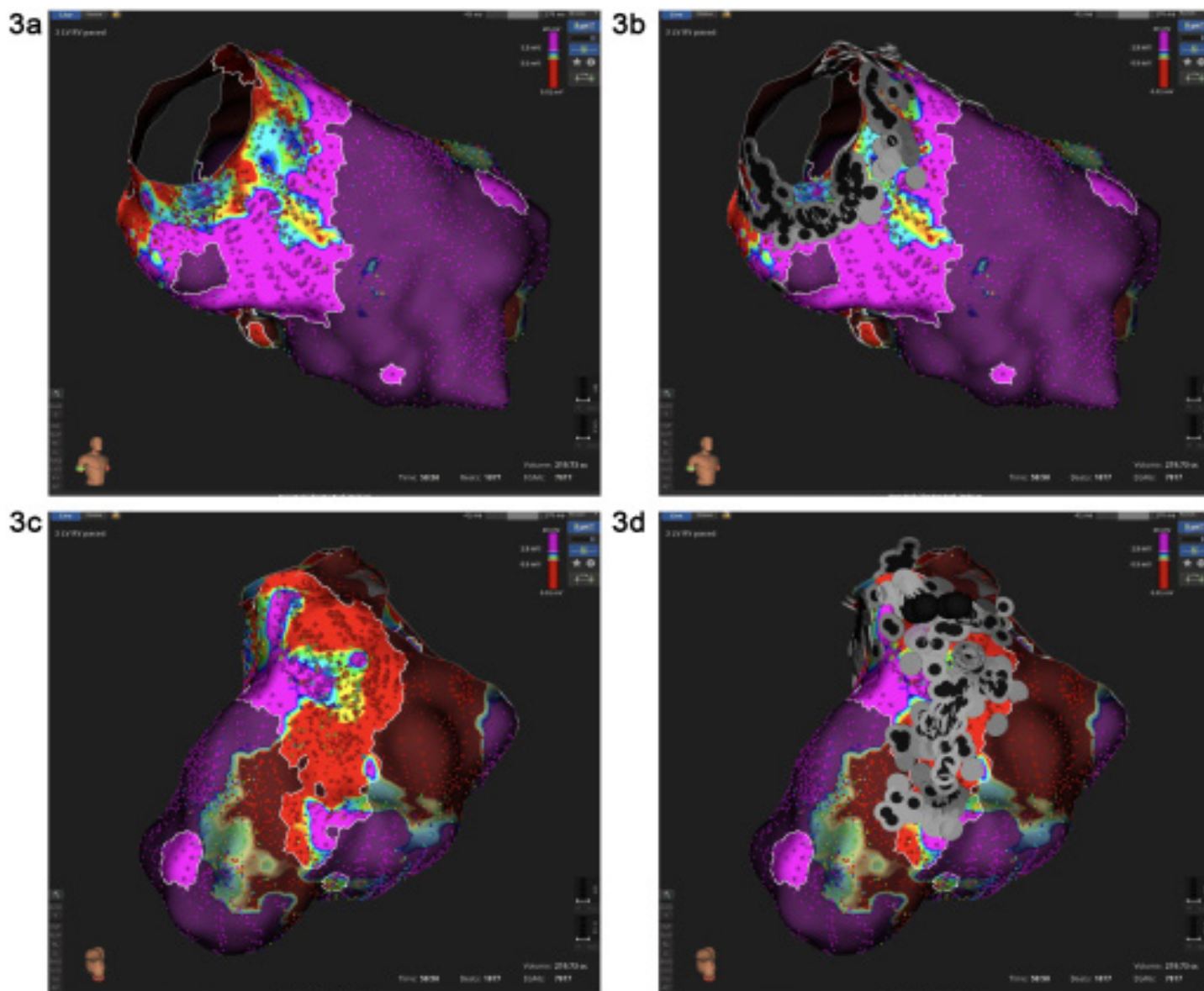
For both groups of patients, ablation power was initially set at 30 Watts and titrated to 50 Watts while monitoring the ablation catheter impedance. Radiofrequency (RF) applications were up to 30 seconds in duration. In the event of a brisk drop in impedance of 15 Ohms or greater, RF applications were immediately discontinued. All ablation was power controlled with a temperature maximum of 45 degrees Celsius. RF application sites were assessed after ablation at each location with pacing from the ablation catheter distal bipole. RF applications were repeated if the pacing at 2.5 V at 20 milliseconds pulse width resulted in capture. If after three applications local capture was still achieved, no further ablation was given at this location and the catheter was moved elsewhere. Prior to the initiation of ablation, catheter to tissue contact was assessed via monitoring impedance stability and curvature of the catheter shaft on fluoroscopy as needed.

At the end of the procedure, hemostasis was achieved with Vascade closure devices (Cardiva Medical, Santa Clara, California) for all venous access and arterial access less than 6 French. Heparin was reversed with 100 mg of intravenous protamine. Perclose closure devices (Abbott, St. Paul, MN) were used for arterial access greater than 6 French.

### Results

Ten patients (8 men, 2 women) ranging in age from 30 to 75 years were included in the study (mean age of  $59 \pm 13$  years). Patient 1 was initially admitted for recurrent VT and underwent his procedure as an inpatient. Patients 2 through 10 had their procedures performed electively as outpatients. The average weight was  $92.7 \pm 9.2$  kg corresponding to an average body mass index of  $30.2 \pm 3.3$ . Patients 5 and 9 had undergone prior unsuccessful ablation procedures at outside institutions (Table 1).





**Figure 3:** Patient 6 is a 52 year old male with nonischemic cardiomyopathy and recurrent ICD therapy.

This left ventricular endocardial map was obtained during right ventricular pacing. Right anterior oblique (panels a and b) and left lateral cranial views (panels c and d; both with and without grey with black core ablation markers) are presented. Lumpoint areas indicating late potentials are highlighted and overlaid on voltage mapping (> 1.5 mV indicated as purple, < 0.5 mV indicated as red, abnormal voltage as a gradient colors, see color bar scheme top right).

### Structural Heart Disease Group

Patients (1,4,5,6 and 7) had clinical VAs that were recurrent, unstable, associated with syncope or hemodynamic compromise and ICD therapies. Patient 1 was naive to antiarrhythmic medications at the time of his ablation. The other four patients had ICD therapies despite antiarrhythmic drug therapy. Patient 1 had a combined nonischemic and ischemic cardiomyopathy. Patients 4 (Figure 2), 5 and 7 had ischemic cardiomyopathy with previous coronary artery bypass graft surgery. Patient 6 had a nonischemic cardiomyopathy (Figure 3). The average left ventricular ejection fraction (LVEF) was  $31 \pm 4\%$  and the average left ventricular end diastolic dimension (LVEDV) was  $5.8 \pm 0.2$  cm. All patients were NYHA class II or III.

The patients underwent endocardial left ventricular mapping via a transseptal approach for both the Orion mapping and ablation catheters. Additionally, patient 1 underwent epicardial mapping with the Orion mapping catheter only. For this patient, no significant abnormal epicardial substrate was found and no epicardial ablation was performed. Patients 5, 6 and 7 additionally underwent LV mapping with the Orion catheter via a retrograde aortic approach after transseptal mapping. In these three patients, this retrograde approach was performed to aid with mapping of the left ventricular outflow tract and the left ventricular aspect of the atrio-ventricular septum. The average total procedure time for this group was  $244 \pm 37$  min. The average radiation exposure was  $38 \pm 23$  mGy over an average of  $12 \pm 4$



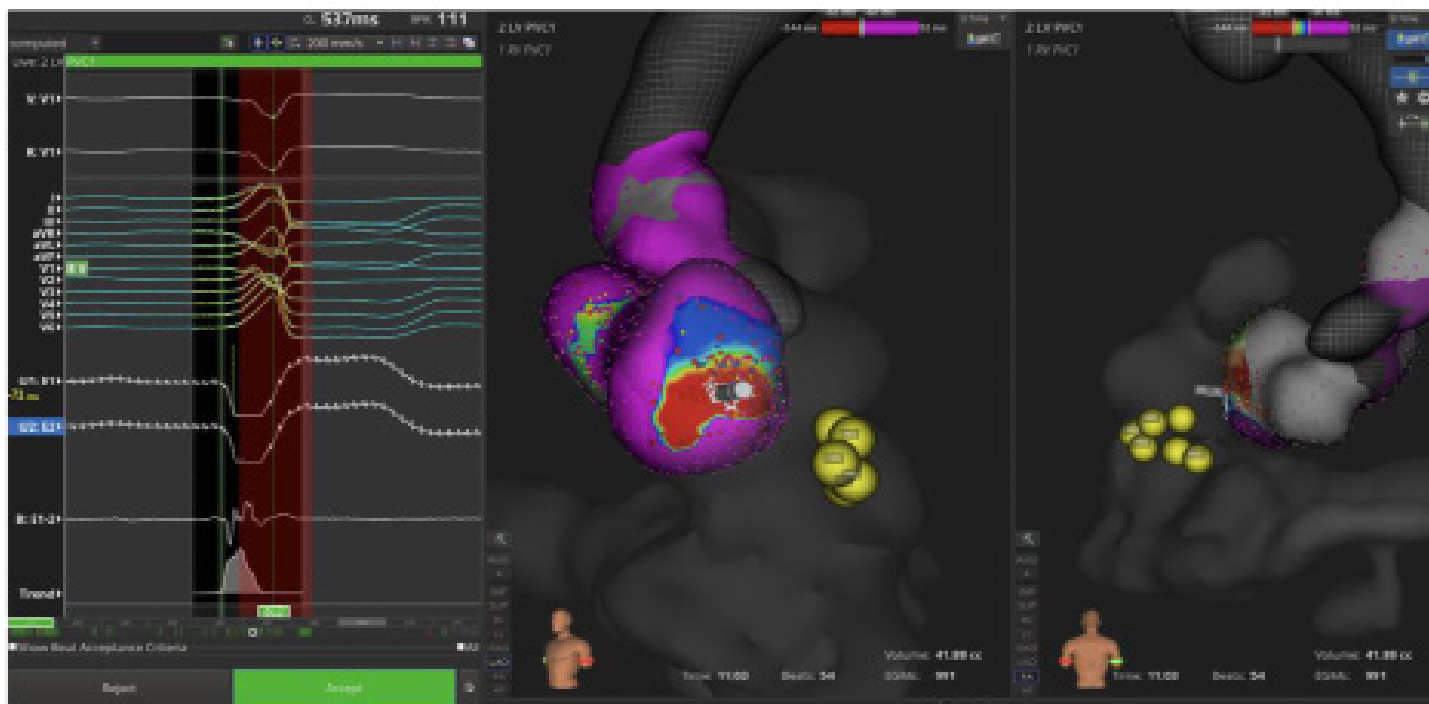


Figure 4:

**Patient 3 is a 68 year old female with a structurally normal heart and a recurrent PVC mapped and ablated in the right coronary cusp of the aortic valve.**

minutes. Mapping time averaged  $44 \pm 15$  min and the average number of electrogram points included in the LV maps were  $5,963 \pm 2075$ .

### Normal Heart Group

Patients (2,3,8, 9 and 10) had either clinical isolated unimorphic PVCs, ventricular tachycardia, or both. All patients had failed at least oral beta-blocker therapy and/or had significant VAs breakthrough despite antiarrhythmic meds. All antiarrhythmic medications were discontinued post procedure. The average LVEF was  $58 \pm 8\%$  and the average LVEDV was  $4.8 \pm 0.4$  cm.

Patient 2 had a PVC burden of 24% and a LVEF of 45%. A cardiac MRI demonstrated no delayed enhancement. The patient's VA was successfully ablated at a discrete LV endocardial site consistent with an idiopathic left posterior fascicular SOO. 30 days post PVC ablation, the LVEF had normalized to 65%.

Patient 3 had a PVC burden of 10%. Mapping of the RV outflow tract demonstrated no suitable sites for ablation. Using the retrograde aortic approach, the VA was successfully ablated at the right coronary cusp (Figure 4).

Patient 8 had a PVC burden of 22% and a LVEF of 52% along with a small and discrete area of delayed enhancement by cardiac MRI. The SOO was determined to be the inferior and basal aspect of the right ventricle and the VA was successful ablated. LVEF improved to 60% on follow up echocardiogram.

Patients 9 and 10 had a PVC burden of 14% and 17.5% respectively and normal LVEFs. Successful ablation of the RV outflow tract and along the tricuspid valve annulus approximately 2 cm inferior to the location of the His bundle was performed.

The average total procedure time for this group was  $153 \pm 22$  min. The average radiation exposure was  $63 \pm 37$  mGy over an average of  $9 \pm 4$  min. Mapping time averaged  $18 \pm 6$  min and the average number of electrogram points included in the LV maps were  $1459 \pm 492$ .

### Clinical Endpoints for All Patients

All patients successfully met the clinical procedural endpoints. No complications occurred. The duration of procedural follow up ranged between 2-25 months with an average of  $9 \pm 6$  months. Patient 4 had an ICD shock 6 months post procedure for ventricular fibrillation occurring during sleep. The other four ICD patients had no ventricular arrhythmia stored events. The normal heart patients had no VA recurrence.

### Discussion

To our knowledge, this retrospective cohort study is the first to describe a clinical experience of the conjoint use of the high density cardiac mapping system Rhythmia™ with Stereotaxis™ remote magnetic navigation for the ablation of VAs. There has been a case report of ablation of AV nodal reentry tachycardia in a single patient with Rhythmia™ and Stereotaxis™.<sup>34</sup> Use of Stereotaxis™ magnetic navigation with the Rhythmia™ mapping system has been both safe and effective in our experience. The reason to integrate the two systems was to yield the simultaneous benefit of high density mapping of VAs and remote magnetic catheter navigation and ablation. Indeed this was achievable after careful consideration and management of the following issues:

- 1) The logistics of connecting the hardware of the Rhythmia™ system, Stereotaxis™ system including the Odyssey monitor, RF generator, and ablation catheter.

2) The procedural workflow to allow for initial creation of a map that will allow tracking of the impedance based ablation catheter, and potentially any other non-proprietary magnetic enabled catheters if so desired. The procedures in this study were approached in two distinct phases: mapping of arrhythmia and substrate, followed by a shift to magnetic catheter navigation and ablation and no additional mapping. While all mapping in this study was performed with the Orion catheter utilized as a magnetic enabled catheter, the authors have utilized during procedures not included in this study impedance based Orion catheter tracking to create additional maps or to add to maps created with magnetic tracking. Consider the scenario where VT is encountered either spontaneously or as a result of RF application while the magnets are in the “navigate” position. Switching to VT activation mapping with Orion registered as an impedance based catheter while leaving the magnets in the “navigate” position allows for rapid activation mapping alternating with remote magnetic ablation.

3) How best to co-align the Rhythmia™ map with the Stereotaxis™ heart representation. One of the principal benefits of the software integration between CARTO and Stereotaxis™ is registration of the Stereotaxis™ ordinates and controls within the CARTO map. Such integration is not available with Rhythmia™ presently. Stereotaxis™ is now an “open source” platform however and indeed this is a first step towards high level software integration between the two. In the meantime, the authors have developed a five step work process to co-align the Rhythmia™ map with the Stereotaxis™ representation: First, rotate the Rhythmia™ map from AP to an RAO projection such that the long axis of the ventricle is without foreshortening. Second, the Stereotaxis™ representation of the ventricle is then rotated into an RAO projection where its ventricular long axis is also without foreshortening. Third, Rhythmia™ and Stereotaxis™ images are then rotated into an LAO view where the long axis of the ventricle is maximally foreshortened. Fourth, the Rhythmia™ map is then rotated about the long axis of the ventricle (now pointing directly in and out of the screen) as necessary either clockwise or counterclockwise such that the inferior wall of the ventricle is parallel to the inferior wall of the Stereotaxis™ image. Fifth, manipulate both maps simultaneously into a working view that allows for greatest exposure of the anatomy that will be the focus of ablation. This is of course a starting point that requires iterative refinement.

In this limited series of ten patients, we found the location of the ablation catheter representation via impedance tracking to be both accurate and consistent over the duration of the procedure and that it did not significantly evolve with saline infused during the procedure. While neither system offers official system integration with the other, the conjoint utilization of the two systems has been relatively straightforward.

### Limitations

Limitations include the fact that this is a retrospective cohort study. While our center utilizes standardized follow up protocols for these procedures, the follow up is focused on what is clinically relevant to the patient. A prospective cohort study, ideally with an historical control arm, or better still, a randomized study with a manual ablation arm compared to a remote magnetic navigation arm would be able to

include follow up data not assessed routinely in clinical follow up such as post ablation MRI lesion assessment and standardized long term arrhythmia monitoring, among others. Additionally a prospective randomized study would potentially be able to standardize ICD monitoring zones, antiarrhythmic drug post procedure management, and likely afford longer follow up. Patient quality of life of assessment would also be valuable clinical data in a future study.

The currently available Thermcool RMT catheter is a design that is many years old. Newer magnetic ablation catheter designs with potentially improved agility, endocardial contact force, and more modern energy delivery may offer incremental clinical benefit to patients. Ideally new ablation catheter designs would allow for magnetic enabled navigation with Rhythmia™ while minimizing field distortion of rare earth magnets of Stereotaxis™. It remains to be seen if and how this may be achieved.

### Conclusion

In summary, we publish this paper to describe our nascent experience with high density mapping of VAs with Stereotaxis™ remote magnetic catheter ablation. Our hope is that our experience will serve as a nidus for the publication of additional data, collaboration between Stereotaxis™, Rhythmia™ and indeed potentially other mapping solutions that will provide complete integration of systems.

### Please Click for Table 1

### References

1. Aryana A, d'Avila A, Heist EK, et al. Remote magnetic navigation to guide endocardial and epicardial catheter mapping of scar-related ventricular tachycardia. *Circulation* 2007;115(10):1191-200. DOI: 10.1161/CIRCULATIONAHA.106.672162.
2. Dinov B, Schonbauer R, Wojdyla-Hordynska A, et al. Long-term efficacy of single procedure remote magnetic catheter navigation for ablation of ischemic ventricular tachycardia: a retrospective study. *J Cardiovasc Electrophysiol* 2012;23(5):499-505. DOI: 10.1111/j.1540-8167.2011.02243.x.
3. Skoda J, Arya A, Garcia F, et al. Catheter Ablation of Ischemic Ventricular Tachycardia With Remote Magnetic Navigation: STOP-VT Multicenter Trial. *J Cardiovasc Electrophysiol* 2016;27 Suppl 1:S29-37. DOI: 10.1111/jce.12910.
4. Szili-Torok T, Schwagten B, Akca F, et al. Catheter ablation of ventricular tachycardias using remote magnetic navigation: a consecutive case-control study. *J Cardiovasc Electrophysiol* 2012;23(9):948-54. DOI: 10.1111/j.1540-8167.2012.02340.x.
5. Turagam MK, Atkins D, Tung R, et al. A meta-analysis of manual versus remote magnetic navigation for ventricular tachycardia ablation. *J Interv Card Electrophysiol* 2017;49(3):227-235. DOI: 10.1007/s10840-017-0257-3.
6. Zhang F, Yang B, Chen H, et al. Magnetic versus manual catheter navigation for mapping and ablation of right ventricular outflow tract ventricular arrhythmias: a randomized controlled study. *Heart Rhythm* 2013;10(8):1178-83. DOI: 10.1016/j.hrthm.2013.05.012.
7. Arenal A, del Castillo S, Gonzalez-Torrecilla E, et al. Tachycardia-related channel in the scar tissue in patients with sustained monomorphic ventricular tachycardias: influence of the voltage scar definition. *Circulation* 2004;110(17):2568-74. DOI: 10.1161/01.CIR.0000145544.35565.47.
8. Arenal A, Glez-Torrecilla E, Ortiz M, et al. Ablation of electrograms with an isolated, delayed component as treatment of unmappable monomorphic ventricular tachycardias in patients with structural heart disease. *J Am Coll Cardiol* 2003;41(1):81-92. DOI: 10.1016/s0735-1097(02)02623-2.

9. Bogun F, Bender B, Li YG, et al. Analysis during sinus rhythm of critical sites in reentry circuits of postinfarction ventricular tachycardia. *J Interv Card Electrophysiol* 2002;7(1):95-103. DOI: 10.1023/a:1020832502838.
10. Bogun F, Good E, Reich S, et al. Isolated potentials during sinus rhythm and pace-mapping within scars as guides for ablation of post-infarction ventricular tachycardia. *J Am Coll Cardiol* 2006;47(10):2013-9. DOI: 10.1016/j.jacc.2005.12.062.
11. Bogun F, Marine JE, Hohnloser SH, Oral H, Pelosi F, Morady F. Relative timing of isolated potentials during postinfarction ventricular tachycardia and sinus rhythm. *J Interv Card Electrophysiol* 2004;10(1):65-72. DOI: 10.1023/B:JICE.0000011487.65849.26.
12. Harada T, Stevenson WG, Kocovic DZ, Friedman PL. Catheter ablation of ventricular tachycardia after myocardial infarction: relation of endocardial sinus rhythm late potentials to the reentry circuit. *J Am Coll Cardiol* 1997;30(4):1015-23. DOI: 10.1016/s0735-1097(97)00257-x.
13. Hsia HH, Callans DJ, Marchlinski FE. Characterization of endocardial electrophysiological substrate in patients with nonischemic cardiomyopathy and monomorphic ventricular tachycardia. *Circulation* 2003;108(6):704-10. DOI: 10.1161/01.CIR.0000083725.72693.EA.
14. Hsia HH, Lin D, Sauer WH, Callans DJ, Marchlinski FE. Anatomic characterization of endocardial substrate for hemodynamically stable reentrant ventricular tachycardia: identification of endocardial conducting channels. *Heart Rhythm* 2006;3(5):503-12. DOI: 10.1016/j.hrthm.2006.01.015.
15. Hsia HH, Lin D, Sauer WH, Callans DJ, Marchlinski FE. Relationship of late potentials to the ventricular tachycardia circuit defined by entrainment. *J Interv Card Electrophysiol* 2009;26(1):21-9. DOI: 10.1007/s10840-009-9421-8.
16. Jais P, Maury P, Khairy P, et al. Elimination of local abnormal ventricular activities: a new end point for substrate modification in patients with scar-related ventricular tachycardia. *Circulation* 2012;125(18):2184-96. DOI: 10.1161/CIRCULATIONAHA.111.043216.
17. Marchlinski FE, Callans DJ, Gottlieb CD, Zado E. Linear ablation lesions for control of unmappable ventricular tachycardia in patients with ischemic and nonischemic cardiomyopathy. *Circulation* 2000;101(11):1288-96. DOI: 10.1161/01.cir.101.11.1288.
18. Miller JM, Tyson GS, Hargrove WC, 3rd, Vassallo JA, Rosenthal ME, Josephson ME. Effect of subendocardial resection on sinus rhythm endocardial electrogram abnormalities. *Circulation* 1995;91(9):2385-91. DOI: 10.1161/01.cir.91.9.2385.
19. Sacher F, Lim HS, Derval N, et al. Substrate mapping and ablation for ventricular tachycardia: the LAVA approach. *J Cardiovasc Electrophysiol* 2015;26(4):464-471. DOI: 10.1111/jce.12565.
20. Santangeli P, Marchlinski FE. Substrate mapping for unstable ventricular tachycardia. *Heart Rhythm* 2016;13(2):569-83. DOI: 10.1016/j.hrthm.2015.09.023.
21. Hooks DA, Yamashita S, Capellino S, Cochet H, Jais P, Sacher F. Ultra-Rapid Epicardial Activation Mapping During Ventricular Tachycardia Using Continuous Sampling from a High-Density Basket (Orion(TM) ) Catheter. *J Cardiovasc Electrophysiol* 2015;26(10):1153-4. DOI: 10.1111/jce.12685.
22. Martin R, Hocini M, Haisaguerre M, Jais P, Sacher F. Ventricular Tachycardia Isthmus Characteristics: Insights from High-density Mapping. *Arrhythm Electrophysiol Rev* 2019;8(1):54-59. DOI: 10.15420/aer.2018.78.2.
23. Martin R, Maury P, Biscaglia C, et al. Characteristics of Scar-Related Ventricular Tachycardia Circuits Using Ultra-High-Density Mapping: A Multi-Center Study. *Circ Arrhythm Electrophysiol* 2018;11(10):e006569. DOI: 10.1161/CIRCEP.118.006569.
24. Nuhric JM, Kaiser L, Akbulak RO, et al. Substrate characterization and catheter ablation in patients with scar-related ventricular tachycardia using ultra high-density 3-D mapping. *J Cardiovasc Electrophysiol* 2017;28(9):1058-1067. DOI: 10.1111/jce.13270.
25. Yang F, Roy J, Saxena A, Kulbak G, Greenberg Y. Initial Experience with High-density Mapping of Ischemic Ventricular Tachycardia Using a Narrow 0.1-mV to 0.25-mV Border-zone Window. *J Innov Card Rhythm Manag* 2020;11(10):4250-4255. DOI: 10.19102/icrm.2020.111006.
26. Viswanathan K, Mantziari L, Butcher C, et al. Evaluation of a novel high-resolution mapping system for catheter ablation of ventricular arrhythmias. *Heart Rhythm* 2017;14(2):176-183. DOI: 10.1016/j.hrthm.2016.11.018.
27. Martin CA, Takigawa M, Martin R, et al. Use of Novel Electrogram "Lumipoint" Algorithm to Detect Critical Isthmus and Abnormal Potentials for Ablation in Ventricular Tachycardia. *JACC Clin Electrophysiol* 2019;5(4):470-479. DOI: 10.1016/j.jacep.2019.01.016.
28. Nakatani Y, Maury P, Rollin A, et al. Accuracy of automatic abnormal potential annotation for substrate identification in scar-related ventricular tachycardia. *J Cardiovasc Electrophysiol* 2021;32(8):2216-2224. DOI: 10.1111/jce.15148.
29. Ng J, Chhachhi B, Stobie P, Keren A, Popal S, Reichlin T. Noncentrifugal activation patterns in focal RVOT PVC/VT: New insights from high density multielectrode mapping. *J Cardiovasc Electrophysiol* 2021;32(1):102-109. DOI: 10.1111/jce.14796.
30. Martin CA, Martin R, Maury P, et al. Effect of Activation Wavefront on Electrogram Characteristics During Ventricular Tachycardia Ablation. *Circ Arrhythm Electrophysiol* 2019;12(6):e007293. DOI: 10.1161/CIRCEP.119.007293.
31. d'Avila A, Koruth JS, Dukkipati S, Reddy VY. Epicardial access for the treatment of cardiac arrhythmias. *Europace* 2012;14 Suppl 2:ii13-ii18. DOI: 10.1093/europace/eus214.
32. Josephson ME, Horowitz LN, Waxman HL, et al. Sustained ventricular tachycardia: role of the 12-lead electrocardiogram in localizing site of origin. *Circulation* 1981;64(2):257-72. DOI: 10.1161/01.cir.64.2.257.
33. Josephson ME, Callans DJ. Using the twelve-lead electrocardiogram to localize the site of origin of ventricular tachycardia. *Heart Rhythm* 2005;2(4):443-6. DOI: 10.1016/j.hrthm.2004.12.014.
34. Latcu DG, Bun SS, Saoudi N. Combined remote magnetic navigation and ultra-high-density mapping (Rhythmia) in slow pathway ablation. *Europace* 2016;18(6):814. DOI: 10.1093/europace/euv459.





## Combined Use of Noninvasive ECG Localization and Robotic Catheter Manipulation for the Ablation of Ventricular Arrhythmias

Sandeep G. Nair<sup>1</sup>, Sean P. Mazer<sup>1</sup>, Yaw A. Adjei-Poku<sup>1</sup>, Michael T. Bestawros<sup>1</sup>, and Michael H. Hoskins<sup>1</sup>

<sup>1</sup>New Mexico Heart Institute Lovelace Medical Group Albuquerque, NM United States.

### Abstract

**Background:** Robotic catheter manipulation is an accepted tool for the ablation of premature ventricular complexes (PVCs) and ventricular tachycardia (VT). Non-invasive electrocardiogram (ECG) localization is an emerging technology used to aid in identifying ablation targets. The combined use of these technologies has not been well described.

**Methods:** We combined the use of non-invasive ECG localization using the View Into Ventricular Onset (VIVO™) technology with robotic catheter manipulation for the ablation of PVCs and VT in 26 patients. Data including procedural and fluoroscopy time as well as acute and long-term procedural success were recorded. Comparison of arrhythmia localization defined by the site of successful ablation was made between both VIVO™ as well as physician-based prediction.

**Results:** Twenty-six arrhythmias were targeted for ablation. Twenty-four (92%) were considered partial or complete success. In those patients, only 1 patient had recurrent arrhythmia at follow-up. The VIVO™ system correctly identified the arrhythmia location as a “perfect” match in 21/26 (81%) of cases, compared to 11/26 (42%) of cases based on physician prediction.

**Conclusion:** The VIVO™ system appears highly accurate at predicting the location of PVCs and VT. When used in combination with robotic catheter manipulation, there is a high likelihood of procedural success.

### Introduction

Catheter ablation is an accepted treatment for patients with symptomatic or high-burden premature ventricular complexes (PVCs)<sup>1, 2</sup>. Initial PVC localization is typically performed using qualitative assessment of surface electrocardiogram (ECG) tracings<sup>3</sup>. Despite the availability of several validated localization algorithms<sup>3,4</sup>, physician assessment of PVC location has limitations<sup>3-5</sup>. Additional localization performed using 3-dimensional (3D) electroanatomic mapping is used for selection of target ablation sites. This may be a time-consuming process and often requires mapping of multiple cardiac structures<sup>6,7</sup>.

The use of non-invasive ECG localization technology has been shown to provide accurate pre-procedural localization of PVCs and ventricular tachycardia<sup>4,5,7</sup>. The View Into Ventricular Onset (VIVO™) technology uses anatomical imaging from computed tomography (CT) or magnetic resonance imaging coupled with patient-specific lead

positioning for collection of ECG data<sup>5,8,9</sup>. This technology allows for appropriate procedural planning and may facilitate a targeted mapping approach. The use of this technology has been described in patients with and without structural heart disease for arrhythmias arising from the outflow tracts, papillary muscles, and other cardiac structures<sup>8,9</sup>.

In addition, the use of robotic catheter manipulation with the Stereotaxis system has been well described for use in ablation of ventricular arrhythmias<sup>10,11</sup>. The VIVO™ tool is able to merge with electroanatomic mapping data and then be integrated into the robotic navigation window in Stereotaxis. This model allows the operator to rapidly and accurately navigate inside the targeted chamber, further accelerating the localization of the PVC origin. Such a combined use of non-invasive ECG localization with robotic catheter manipulation has not been well described. In this report, we describe our initial experience combining these two technologies for ablation of PVCs and ventricular tachycardia (VT).

### Key Words

Ablation; Ventricular Arrhythmia; Electrocardiogram; Electrophysiology Mapping

### Corresponding Author

Michael Hoskins, MD  
502 Elm St. Albuquerque, NM 87102.

### Methods

Twenty-six consecutive patients who underwent ablation for PVCs or VT using the combined approach of stereotaxis and VIVO™ in our center were reviewed. All patients were deemed appropriate for ablation and had either symptomatic and/or high-burden PVCs or VT

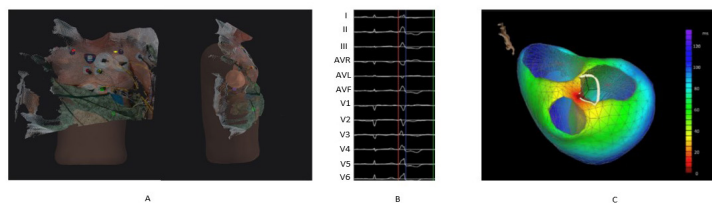


Figure 1:

**A) Example of a real-time photo image of a patient with ECG leads in place. The photo has been taken with the Intel® RealSense™ Depth Camera. This image is then overlaid upon a previously obtained CT image of the patient. The VIVO™ system then correlates ECG and anatomic positioning (AP and right lateral views shown). B) A real-time sample of the arrhythmia ECG is imported. C) Final VIVO™ 3D image is created with activation map of the arrhythmia.**

Abbreviation: AP= anteroposterior

refractory to medical therapy. Pre-procedural imaging with cardiac CT was performed on all patients.

### VIVO™ analysis

Non-invasive ECG localization was performed in all cases using the VIVO™ system. All patients underwent gated cardiac CT scans prior to the procedure. DICOM images were used to create tissue identification and segmentation to generate a 3-dimensional model for each patient. A real-time photo image of the patient with ECG leads positioned is taken with the Intel® RealSense™ Depth Camera. This image is then merged with the patient's torso anatomy obtained by CT and is used to identify patient-specific ECG location relative to cardiac structures (Figure 1). That model was then merged with the 3D model created using electroanatomic mapping and intracardiac echocardiography (ICE) images.

An ECG tracing of the clinical PVC or VT is imported and the QRS of interest is analyzed by the VIVO™ software. The activation sequence is then created by combining the ECG and 3D model data and the point of earliest activation is identified in the model (Figure 2).

### Anatomic location of arrhythmia

The anatomic location of the clinical PVC/VT was defined as the site of successful ablation as identified using electroanatomic mapping (Figure 3). In cases where acute success was not achieved, the anatomic location was defined as that with the earliest recorded EGMs. A clinical determination of the location of PVC or VT in each case was generated by consensus of two electrophysiologists who were both blinded to each case. A comparison was then made between the anatomic location as defined by electroanatomic mapping and those determined by both VIVO™ and physician consensus. A "perfect match" was defined as precise correlation, whereas those cases that did not meet these criteria were defined as "mismatch".

### Ablation

The ablation procedure was conducted according to our institutional standards. Right ventricular mapping was performed via femoral venous access. Left ventricular and aortic mapping were performed using transseptal or retrograde techniques. Intracardiac echocardiography was used in all cases. Mapping was performed using the CARTO 3 system (Biosense Webster, Inc.). Target ablation sites for PVCs were identified by those with unipolar electrograms (EGMs) >30 msec pre-QRS and/

or at sites where pacing at 10mA resulted in QRS complexes with ≥95% match to the clinical arrhythmia. Target ablation sites for VT were identified by the presence of mid-diastolic signals, entrainment criteria indicating the presence of a critical isthmus, or sites identified as an isthmus using 3D electroanatomic mapping. Ablation was performed with an RMT Thermocool catheter using the Stereotaxis system. One-half normal saline was used for irrigation and energy delivery up to 50 W was used unless otherwise directed by the physician.

### Results

Twenty-six patients underwent ablation using the combination of VIVO™ and Stereotaxis technologies. One patient had two PVC morphologies which were targeted and, in that patient, each morphology was considered individually in this analysis. Fifteen patients (58%) were male and the mean age was 68 years. The mean ejection fraction was 50%. Four patients (15%) had a diagnosis of coronary disease. Mean PVC burden was 24%; three patients had sustained ventricular tachycardia.

In one patient, ablation was deferred due to infrequent PVCs. Twenty-six arrhythmias were ablated. Twenty-two of these (85%) were considered acutely successful, 2 (8%) were considered partially successful, and 2 (8%) were considered not successful. Of the 22 arrhythmias with acutely successful procedures, one (4%) had recurrent PVCs at 6-week follow-up; the other patients remained free of clinical PVCs. Complications included the development of right bundle branch block in one patient and another requiring pacemaker insertion two days after PVC ablation.

The average procedure time was 156 minutes. Three patients had additional arrhythmias ablated during the index procedure (AV node reentry in two and atrial fibrillation in the other). An additional patient underwent attempted ethanol ablation of a left ventricular summit PVC. Mean fluoroscopy time was 1.4 minutes.

The baseline and procedural characteristics of each arrhythmia are listed in Table 1.

### Accuracy of anatomic location using VIVO™

VIVO™ correctly identified the anatomic location as a "perfect match" in 21/26 cases (81%) and "mismatch" in 5/26 cases (19%). In comparison, the physician-determined location resulted in a "perfect match" in 11 patients (42%) and "mismatch" in 15 cases (58%). (Table 2.)

### Use of Stereotaxis

All patients underwent mapping and ablation with the Stereotaxis system. In one patient, transition to a manual catheter was required. This was due to difficulty robotically manipulating the catheter into the anterior intraventricular vein (AIV).

### Discussion

In this report, we describe our experience of patients undergoing ablation of ventricular arrhythmias using a combination of non-invasive arrhythmia localization using VIVO™ technology and robotic catheter manipulation using the Stereotaxis system. To our knowledge, this is the largest cohort of patients to date using this combination.

**Table 1: Baseline clinical and procedural characteristics.**

Case number	Gender	Age (years)	Ejection fraction (%)	Prior ablation	PVC%	Symptoms	Location	Procedure acute success	Procedure long-term success	Procedure time (min)	Fluoroscopy time (min)	Additional arrhythmia	Complication
1	Male	76	70	No	15	Yes	MCV	Yes	Yes	273	2.2	AVNRT	
2	Male	75	40	No	5	Yes	RVOT	Yes	Yes	116	0.1		
3	Male	76	35	No	VT	Yes	LV apical septum	Partial	Unknown	95	0.9		
4	Female	64		No	VT	Yes	RVOT septum	Yes	Yes	104	7.4		
5	Male	75	60	Yes	15	Yes	Aortic cusp (LCC-RCC)	Yes	Yes	210	0.8		
6	Male	73	68	No	28	Yes	LCC	Yes	Yes	170	0.2		
7	Male	52	35	No	VT	Yes	LV apex	Yes	Unknown	170	2.4		
8	Male	81	55	No	38	Yes	Posteroseptal PM	Yes	No	134	0.1		
9	Female	59	56	No	7	Yes	N/A	Aborted	N/A		0.1		
10	Female	64	60	No	N/A	Yes	Para-Hisian	Yes	Unknown	120	0.1		RBBB
11	Female	87	40	No	34	Yes	Para-Hisian	Yes	Yes	174	0.1		Pacemaker
12	Male	66	55	Yes	32	Yes	RVOT	Yes	Yes	140	0.1		
13	Male	53	20	No	31	Yes	Anterior MA	Yes	Yes	96	0.1		
14	Female	39	60	Yes	15	Yes	RVOT free wall	Yes	Yes	73	0.1		
15	Male	83	60	No	20	Yes	AMC	Yes	Yes	192	0.1	AVNRT	
16	Female	75	45	No	19	Yes	AIV	Yes	Yes	184	0.2		
17-1	Male	74	40	No	21	Yes	AMC	Yes	No	150	0.1		
17-2	-	-	-	-	-	-	Posterior MA	Yes	No	-	-		
18	Male	84	55	No	24	Yes	Anterior MA	Yes	Yes	85	0.1		
19	Female	61	55	No	44	Yes	RVOT septum	Partial	No	188	0.1		
20	Female	74	44	No	13	Yes	LVOT	No	No	203	0.1		
21	Female	62	45	No	30	Yes	Aortic cusp	Yes	Yes	95	0.1		
22	Male	74	60	No	18	Yes	LCC	Yes	Unknown	107	0.1		
23	Female	81	58	No	40	Yes	LV summit	No	No	360	21.7		
24	Male	65	55	No	30	No	Tricuspid inflow	Yes	Yes	112	0.1		
25	Male	46	29	No	40	Yes	AIV	Yes	Unknown	140	0.1		
26	Female	57	45	No	13	Yes	AIV	Yes	Unknown	210	0.1	AF	

Abbreviations: MCV = middle cardiac vein, RVOT = right ventricular outflow tract, LV = left ventricle, LCC = left coronary cusp, RCC = right coronary cusp, PM = papillary muscle, RBBB = right bundle branch block, MA = mitral annulus, AMC = aorto-mitral continuity, AIV = anterior intraventricular vein, AVNRT = AV node reentry tachycardia, AF = atrial fibrillation.

Remote catheter manipulation using the Stereotaxis system has been broadly used for the mapping and ablation of ventricular arrhythmias<sup>10-12</sup>. This system has several advantages over manual catheter manipulation, including stable catheter contact and positioning, ease of positioning in certain anatomic areas, limiting excessive catheter force, and reducing operator fatigue<sup>11-13</sup>. One of the critical elements when using this system is proper procedural planning based on predicted anatomic location of the target arrhythmia. This facilitates choosing access approach (transvenous-transseptal or retrograde aortic) and use of additional equipment such as deflectable or fixed-curve sheaths. Choosing the correct procedural approach from the onset may reduce procedural time consumed during mapping and reduce the need for alternating access approaches. Both of these components may increase the likelihood of procedural success.

Determination of arrhythmia location by physician analysis of the surface ECG may be limited by several factors including anatomical variations, patient positioning, and difference in ECG lead location.

Non-invasive ECG analysis using real-time imaging may reduce the impact of these variables. In this series, The VIVO™ system consistently and accurately predicted the anatomic location of the target arrhythmia (“perfect match”) in 81% of cases, compared to 42% in the case of the physician prediction. The procedural success in this series was high (overall 94%) and is consistent with other series in the literature<sup>8,13,14</sup>. Our experience is that integration of the Stereotaxis and VIVO™ systems enhances the efficiency that each tool brings to this procedure. The increased anatomic accuracy allowed by the VIVO™ tool integrated with excellent catheter precision from the Stereotaxis system results in a complementary effect that enhances the likelihood of procedural success.

In one case in this series, a change to a manual catheter was required. This was due to difficulty accessing the AIV with the Stereotaxis system. Being able to accurately predict this location during preprocedural planning may influence the type of catheter chosen (manual vs. robotic).

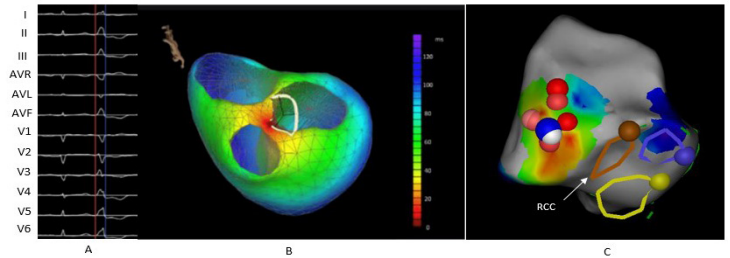
In our experience, there are several limitations to the use of the



**Table 2: Comparison of arrhythmia anatomic location based on VIVO™, electroanatomic mapping, and physician prediction**

Case number	VIVO™ location	EAM location	Physician prediction	VIVO™ -EAM correlation	Physician-EAM correlation
1	RV septum	MCV	RV septum	0	0
2	RVOT	RVOT	RCC	1	0
3	LV apical septum	LV apical septum	RV apex	1	0
4	RVOT septum	RVOT septum	RVOT septum	1	1
5	Aortic cusp	Aortic cusp (LCC-RCC)	AMC	1	0
6	LCC	LCC	AIV	1	0
7	LV apex	LV apex	LV apex	1	1
8	Posteroseptal PM	Posteroseptal PM	Posteroseptal PM	1	1
9	LV septum	N/A (procedure aborted)	Anterolateral MA	N/A	N/A
10	Para-Hisian	Para-Hisian	Para-Hisian	1	1
11	Para-Hisian	Para-Hisian	Para-Hisian	1	1
12	RVOT	RVOT	Anterior LVOT	1	0
13	Anterior MA	Anterior MA	Lateral MA	1	0
14	RVOT Free wall	RVOT free wall	RVOT free wall	1	1
15	AMC	AMC	AMC	1	1
16	AIV	AIV	Lateral MA	1	0
17-1	AMC	AMC	AMC	1	1
17-2	Posterior MA	Posterior MA	LV inferoseptal	1	0
18	Posterior MA	Anterior MA	Anterior MA	0	1
19	RVOT septum	RVOT septum	RCC	1	0
20	LVOT	LVOT	RCC	1	0
21	Aortic cusp	Aortic cusp	RVOT septum	1	0
22	LVOT	LCC	RVOT septum	0	0
23	RCC	LV summit	LCC	0	0
24	Tricuspid inflow	Tricuspid inflow	RCC	1	0
25	RVOT septum	AIV	AIV	0	1
26	AIV	AIV	AIV	1	1

Correlation key: 1= "perfect match" 0= "mismatch"  
 Abbreviations: EAM= electroanatomic mapping, RV= right ventricle, MCV= middle cardiac vein, RVOT= right ventricular outflow tract, RCC= right coronary cusp, LV= left ventricle, LCC= left coronary cusp, AMC= aorto-mitral continuity, AIV= anterior intraventricular vein, PM= papillary muscle, MA= mitral annulus, LVOT= left ventricular outflow tract.



**Figure 3:** A) PVC originating from RCC. A sample sinus beat is provided for comparison. B) VIVO™ map of RCC PVC (superior view). C) Activation map and site of successful ablation of RCC PVC (LAO view)

Abbreviation: RCC= right coronary cusp

VIVO™ technology. First, the need for pre-procedural CT or MRI imaging is an added step for patients. This may increase the cost and inconvenience for patients and has not been previously used routinely in our practice. Second, the development of the VIVO™ anatomic model requires staff who are trained in this step. Third, the fusion of the 3D model with the electroanatomic mapping system is currently performed manually and is therefore dependent on the skill of the personnel involved. This can generally be done successfully and may conceivably become automated in future generations of the technology. Finally, there are anatomic limitations we have experienced using VIVO™, particularly when near the aortic valve annulus and within the AIV. These limitations seem to be due to the segmentation process at the edge of the modelling software region of interest. Recognizing this limitation may aid in procedural planning.

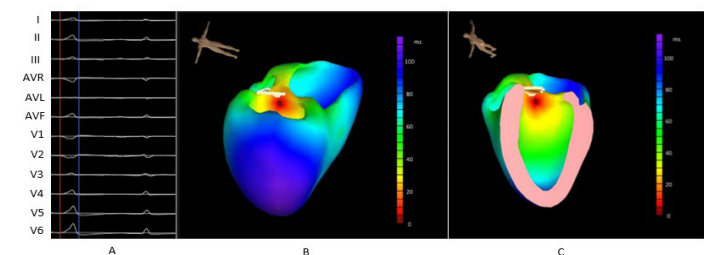
There are several limitations to this report. First, this is a single-center series involving five operators. While all five operators have significant experience using Stereotaxis, all were novice users of the VIVO™ system. This series therefore represents our initial experience with this combination. Further familiarity with this technology would seemingly be associated with improved outcomes. The use of the combination of VIVO™ and Stereotaxis may not be broadly applicable to other electrophysiology laboratories. Finally, while we theorize that the combined use of these technologies may reduce mapping and procedural times and increase success rate, we do not report dedicated mapping times and do not have a control cohort to compare overall procedural times.

**Conclusion**

In conclusion, we report our initial experience using a combination of VIVO™ and Stereotaxis technologies for the ablation of PVCs and VT. This combination appears to be effective at identifying arrhythmia location and ensuring procedural success and has additional benefit when compared to routine clinical assessment of arrhythmia location. Further experience is needed when using these two technologies in tandem.

**Acknowledgments**

We would like to acknowledge Ian Resweber, Tracy Ginnings, and Emma Sullivan for their assistance with obtaining images.




**Figure 2:** A) LVOT PVC with associated sinus rhythm beat. B) VIVO™ activation map for LVOT PVC, and C) with a lateral LV wall cutout.

Abbreviation: LVOT= left ventricular outflow tract, LV= left ventricle

## References

1. Sharma E, Arunachalam K, Di M, Chu A and Maan A. PVCs, PVC-Induced Cardiomyopathy, and the Role of Catheter Ablation. *Crit Path Cardiol.* 2017;16:76-80.
2. Al-Khatib SM, Stevenson WG, Ackerman MJ, Bryant WJ, Callans DJ, Curtis AB, Deal BJ, Dickfeld T, Field ME, Fonarow GC, Gillis AM, Granger CB, Hammill SC, Hlatky MA, Joglar JA, Kay GN, Matlock DD, Myerburg RJ and Page RL. 2017 AHA/ACC/HRS Guideline for Management of Patients With Ventricular Arrhythmias and the Prevention of Sudden Cardiac Death: A Report of the American College of Cardiology/American Heart Association Task Force on Clinical Practice Guidelines and the Heart Rhythm Society. *J Am Coll Cardiol.* 2018;72:e91-e220.
3. Hutchinson MD and Garcia FC. An organized approach to the localization, mapping, and ablation of outflow tract ventricular arrhythmias. *J Cardiovasc Electrophysiol.* 2013;24:1189-97.
4. van Dam PM, Boyle NG, Laks MM and Tung R. Localization of premature ventricular contractions from the papillary muscles using the standard 12-lead electrocardiogram: a feasibility study using a novel cardiac isochrone positioning system. *Europace.* 2016;18:iv16-iv22.
5. Misra S, van Dam P, Chrispin J, Assis F, Keramati A, Kolandaivelu A, Berger R and Tandri H. Initial validation of a novel ECGI system for localization of premature ventricular contractions and ventricular tachycardia in structurally normal and abnormal hearts. *J Electrocardiol.* 2018;51:801-808.
6. Lin AN, Shirai Y, Liang JJ, Chen S, Kochar A, Hyman MC, Santangeli P, Schaller RD, Frankel DS, Arkles JS, Kumareswaran R, Garcia FC, Riley MP, Nazarian S, Lin D, Zado EC, Callans DJ, Marchlinski FE, Supple GE and Dixit S. Strategies for Catheter Ablation of Left Ventricular Papillary Muscle Arrhythmias: An Institutional Experience. *JACC Clin Electrophysiol.* 2020;6:1381-1392.
7. Oosterhoff P, Meijborg VM, van Dam PM, van Dessel PF, Belterman CN, Streekstra GJ, de Bakker JM, Coronel R and Oostendorp TF. Experimental Validation of Noninvasive Epicardial and Endocardial Activation Imaging. *Circ ArrhythmElectrophysiol.* 2016;9:e004104.
8. Nguyen D, Jeudy J, Restrepo AJ and Dickfeld TM. A Novel Use of Noninvasive Registered Electrocardiographic Imaging Map for Localization of VT and PVC. *JACC Case Rep.* 2021;3:591-593.
9. Vali Z, Mistry A, Velu S, Sidhu B, Li X, Pooranachandran V, Lazdam M, Ibrahim M, Sandilands A, Somani R, Stafford P and Ng GA. 128Non-invasive 3D mapping of earliest activation of premature ventricular complexes originating from intracardiac structures to guide catheter ablation. *EP Europace.* 2020;22.
10. Aagaard P, Natale A, Briceno D, Nakagawa H, Mohanty S, Gianni C, Burkhardt JD and L DIB. Remote Magnetic Navigation: A Focus on Catheter Ablation of Ventricular Arrhythmias. *J Cardiovasc Electrophysiol.* 2016;27 Suppl 1:S38-44.
11. Guckel D, Niemann S, Ditzhaus M, Molatta S, Bergau L, Fink T, Sciacca V, El Hamriti M, Imnadze G, Steinhauer P, Braun M, Khalaph M, Nölker G, Sommer P and Sohns C. Long-Term Efficacy and Impact on Mortality of Remote Magnetic Navigation Guided Catheter Ablation of Ventricular Arrhythmias. *J Clin Med.* 2021;10.
12. Bennett RG, Campbell T, Sood A, Bhaskaran A, De Silva K, Davis L, Qian P, Sivagangabalan G, Cooper MJ, Chow CK, Thiagalingam A, Denniss AR, Thomas SP, Kizana E and Kumar S. Remote magnetic navigation compared to contemporary manual techniques for the catheter ablation of ventricular arrhythmias in structural heart disease. *Heliyon.* 2021;7:e08538.
13. Turagam MK, Atkins D, Tung R, Mansour M, Ruskin J, Cheng J, Di Biase L, Natale A and Lakkireddy D. A meta-analysis of manual versus remote magnetic navigation for ventricular tachycardia ablation. *J Interv Card Electrophysiol.* 2017;49:227-235.
14. Chrispin J, Mazur A, Winterfield J, Nazeri A, Valderrabano M and Tandri H. Non-invasive localization of premature ventricular focus: A prospective multicenter study.

*J Electrocardiol.* 2022;72:6-12.



## Telerobotic Navigation – A Comparison of Remote Magnetic Navigation in A Phantom with Operators 1200 km Apart

Stefan Ailoeai<sup>1,2</sup>, Sam Griffiths<sup>1,2</sup>, Piers Wright<sup>1,2</sup>, Sabine Ernst<sup>1,2</sup>

<sup>1</sup>Royal Brompton Hospital, Guys and St. Thomas' NHS Foundation Trust, London, United Kingdom

<sup>2</sup>National Heart and Lung Institute, Imperial College, London, United Kingdom

### Abstract

**Background:** Robotic systems have been used in a diverse spectrum of cardiac interventions, mainly in the field of invasive cardiology, namely interventional cardiology and electrophysiology (EP). The state-of-the-art robotic systems allow mapping and ablation of various arrhythmias without the need for manual conventional catheter steering. The aim of robotic procedures is to achieve the same effectiveness and safety as conventional procedures, whilst reducing the radiation exposure for patients and operators, and to be able to reach targets within the heart that are otherwise unreachable conventionally with greater precision and catheter stability.

**Purpose:** We aimed to demonstrate the feasibility of 3D electroanatomical mapping (EAM) using the remote magnetic navigation (RMN) system (Niobe ES, Stereotaxis Inc) by comparing the mapping performance of 2 operators (one located in the electrophysiology catheter lab control room and the second ~1200 km away via remote online connection).

**Methods:** Two operators were tasked to perform 3D fast anatomical maps (FAM, CARTO 3 RMT, Biosense Webster) of the right and left atrial and ventricular chambers, as well as the aorta of a 3D phantom representing normal cardiac anatomy. All procedures were recorded on the Odyssey Cinema system for further analysis. Parameters compared were duration of FAM, total volume acquired and average distance of surface match to a contrast enhanced computed tomography (CT) of the same phantom. A composite endpoint of map completeness, mapping time and surface match accuracy was calculated to demonstrate if quality of the maps between operators were comparable.

**Results:** A total of 60 maps were created (6 maps for each right atrium (RA), left atrium (LA), right ventricle (RV), left ventricle (LV) and aorta (Ao) per operator) in an alternating fashion. Average mapping time was 16:08±3:36 min for all chambers with shorter mapping times for right atrial chamber 14:28±3:47 min. Total volumes did not significantly differ between operators. Match statistics also revealed no difference between map completeness. Comparing the composite endpoint, both operators achieved the same accuracy.

**Conclusion:** A distant operator located more than 1200 km away from the RMN laboratory connected online to perform 3D electroanatomical maps of all cardiac chambers of a phantom with equal accuracy and procedure parameters as compared to an operator located in the control room. These results support the feasibility of truly remote-controlled procedures which would allow an expert operator to actively support a local team in EP interventions.

### Introduction

Robotic systems have been used in a diverse spectrum of cardiac interventions, mainly in the field of invasive cardiology, namely interventional cardiology and electrophysiology<sup>1-4</sup>. In EP, telerobotic interventions have been largely limited to few reports on limited patient cohorts<sup>5-10</sup>. The state-of-the-art robotic systems allow mapping

and ablation of various arrhythmias without the need for manual conventional catheter steering<sup>11,12</sup>. The aim of robotic procedures is to achieve at least the same effectiveness and safety as the conventional procedures, whilst reducing the radiation exposure for patients and operators, and to be able to reach targets within the heart that are otherwise unreachable conventionally with greater precision and catheter stability<sup>13-18</sup>.

### Key Words

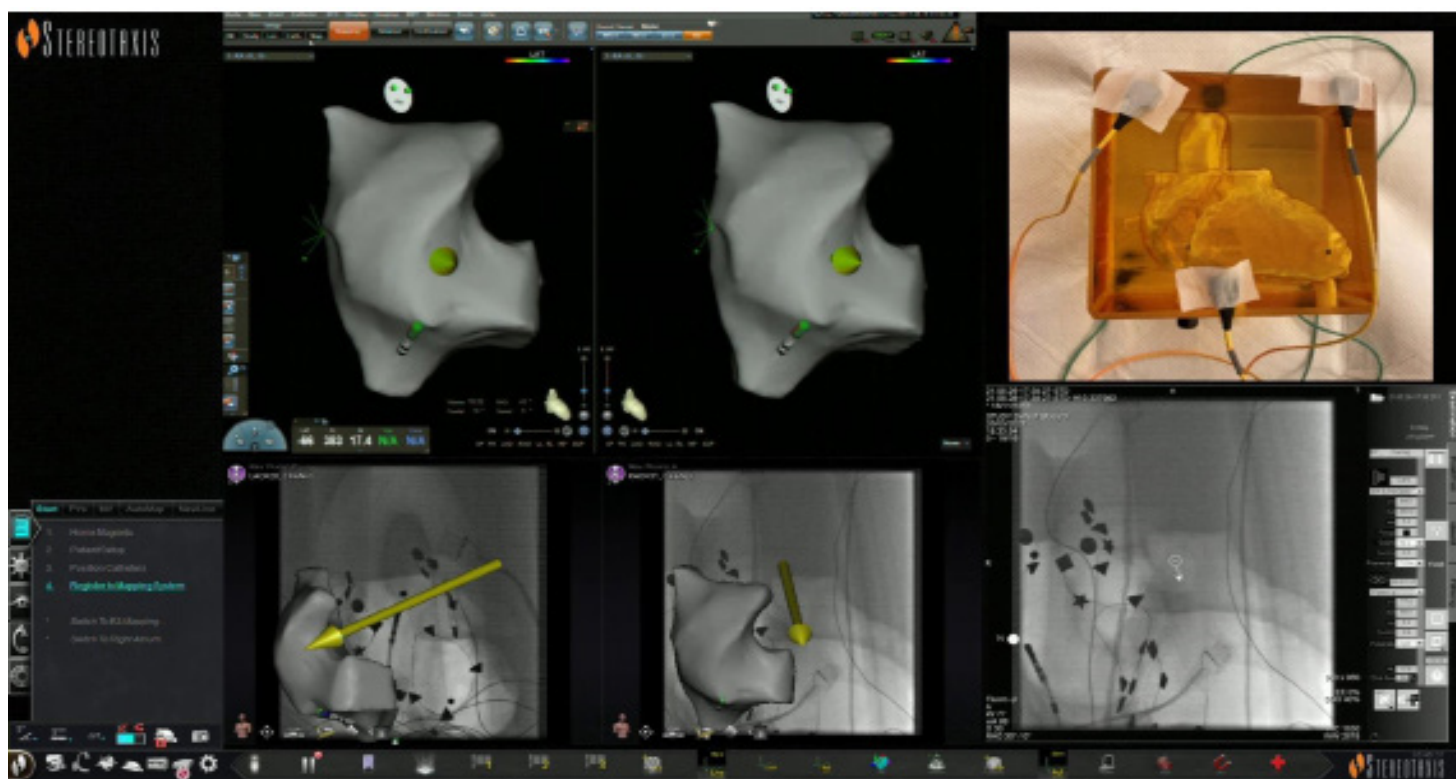
Telerobotic Navigation; Remote Magnetic Navigation; Comparison

### Corresponding Author

Sabine Ernst, MD PhD  
Professor of Practice (Cardiology), Consultant Cardiologist/Electrophysiologist  
National Heart and Lung Institute, Imperial College, Royal Brompton and Harefield Hospital  
Sydney Street, SW3 6NP, London, United Kingdom.

Performing interventions with an operator from a distance supporting the local team (telesupport procedures), still remains a challenge and an area highly underexplored. Until this point in time, expert operators mostly support the local team verbally only by case observation, without being able to directly interact with the patient.





**Figure 1:** 3D phantom.

Typical display of the 3D electroanatomical mapping system (top left), the navigation reference projections (bottom left and middle), as well as the fluoroscopy information on the workstation (Odyssey, Stereotaxis Inc.) which is identical for the local and distant operator. The right upper insert shows the hollow 3D phantom.

Recently, telesteering or rPCI procedures have been reported, but still have a relatively high conversion rate to manual<sup>14,19,20</sup>. RMN in principle allows a distantly located operator to take control of catheter manipulation and the electro anatomical mapping (EAM) of cardiac chambers. Thus, there is a need to perform a systematic investigation of the feasibility and quality of this remote support with the ability to directly interact if needed.

In our study, we aimed to demonstrate the accuracy of acquiring 3D maps by both a local and a distantly located operator using the RMN system in a 3D phantom setting.

## Methods

### Phantom mapping

Using a hollow 3D phantom derived from a CT scan of a human with a normal cardiac anatomy, EAM (CARTO 3 RMT, Bio sense Webster) was enabled in the clinical EP laboratory of the Royal Brompton Hospital in London, UK. The phantom allowed to individually map each chamber of the heart (right and left atria and ventricles and the aorta). The phantom was positioned on the cath lab table and connected to both the EAM and the RMN system (Niobe ES, Stereotaxis, St. Louis, MO). The magnetically enabled catheter was introduced via either the IVC or retrograde via the aorta descending. The catheter was manipulated using the magnetic field directions via a dedicated platform, which also displayed the EAM, fluoroscopy and EP tracings (Odyssey Cinema, Stereotaxis Inc.). Advancing and retraction of the mapping catheter is enabled via a mechanical drive (Cardiodrive,

Stereotaxis Inc.) and connected to the wheel of the operator's mouse.

### Set-up of distantly located operator

The distant operator connected via 2 different commercially available personal computers (PC) from Tyrol (Austria, ca 1200 km distance) to the hospital. The first PC consisted of average-speed office PC (Lenovo idea-PC, Intel Core i5-3330S CPU@2.70 GHz with 4.0 GB of RAM) and was used for the first 15 maps. The second PC was a high performance PC (Alienware Aurora R9, Intel Core i9-9900K CPU @3.6GHz with 64GB of RAM). Both PCs connected through the same internet connection using glass fiber connection via the Windows 10 remote desktop program and a protected VPN (Global Protect). Audio and visual link to the lab was established via a Teams session using the same connection. Mapping sessions were conducted after normal lab procedures had ended, typically around 19.00h local time.

	RA		LA		RV		LV		Aorta	
Average surface match (mm)	1.86 ± 1.55	1.94 ± 1.47	2.14 ± 1.71	2.11 ± 1.72	1.71 ± 1.42	2.19 ± 1.75	1.93 ± 1.75	1.97 ± 1.59	2.16 ± 2.96	1.50 ± 1.32
Volume mapped (ml)	73.14 ± 6.46	70.29 ± 3.48	72.17 ± 9.12	66.37 ± 2.64	110.24 ± 7.14	96.20 ± 7.33	85.02 ± 8.67	92.36 ± 6.29	99.11 ± 4.54	101.75 ± 4.59
Time (min)	16:12 ± 5:16	13:25 ± 2:18	17:23 ± 3:34	14:00 ± 2:01	16:47 ± 5:41	17:35 ± 5:44	13:17 ± 3:21	17:12 ± 2:34	17:06 ± 3:18	18:32 ± 2:13

**Table 1:** Average results for each chamber and operator

Mean parameters for each chamber mapped; white=on-site operator; grey=distant operator

### 3D electro anatomical mapping (EAM) tasks

3D EAM was performed by the two operators monitoring 3 key parameters: time, volume mapped, and average surface area mapped using the fast anatomical mapping (FAM) feature. Each operator acquired 3D maps of the RA, LA, RV, LV as well as the entire aorta (Ao) with the aorta descending until the level of the diaphragm (Figure 2). Mapping time was measured from start of the 3D FAM until the 3D map of the respective chamber was deemed completely reconstructed by the respective operator. Settings for surface reconstruction resolution were kept equal for both operators. The LV was mapped in a retrograde fashion via the Ao. Mapping volumes were recorded from the 3D EAM system. In order to assess map completeness, a 3D reconstruction of a CT scan of the same phantom was merged using initially the "3 landmarks method". Subsequently, surface matching was applied and the average surface match statistics were recorded for each map. Both operators mapped all chambers 6 times in alternating order on different days.

Operators were free to use intermittent fluoroscopy as needed which could only be initiated by the operator on site after verbal instructions by the distant operator.

### Detailed comparison

Three key parameters were assessed: time (seconds), volume (millilitres, as provided by the 3D mapping system), and average surface area mismatch (millimetres, as compared to the 3D reconstructed CT scan of the phantom). The merge between the FAM and the CT scan was performed using landmarks and then matching them using the CARTO surface match. The exclusion of excessive FAM (artefact from CT scan) was performed by shaving it off.

We investigated the two different computer setups for the remote operator to assess the performance. In order to assess the quality of the acquired maps, we created a composite endpoint of mapping time, difference of acquired to maximum volume (derived from CT scan) as well as best surface match statistics for each map, in which each of the three variables were equally weighted.

### Statistical analysis

The statistical analysis was performed using IBM SPSS Statistics version 20. The skewness of the time, volume and surface was found to be -.51, .03 and 0.9, respectively, indicating that the distribution was fairly symmetrical. An independent T-test was used to compare the results between the two operators.

We used three simple algorithms to determine the efficiency of each operator for each parameter separately. We used an algorithm to assign a score for the surface match of each chamber (percentage from 0 to 100%) depending on the error of the acquired value of each operator, compared to the best surface match which has an error equal to 0. Thus, using a numeric scale from 0 to 3, with 0 being the 100% on the grading system, we further split the scale into 300 equal units (100 units between each two numbers from 0 to 3) and determined the value of each single unit. The score for each chamber mapped by each operator was given by subtracting from 100 the number resulted by multiplying the value of the surface area match error with 100, further multiplied

by the value of each unit. Therefore, the bigger the error, the lower the score for each operator.

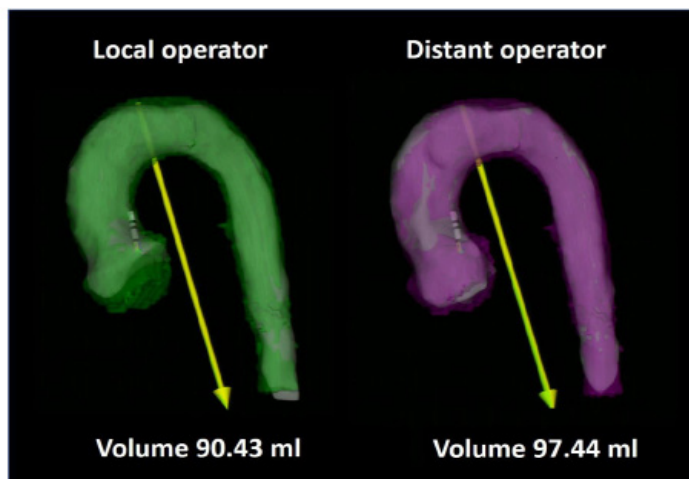
The score for the volume mapped was assigned by reporting the percentage of the volume of the FAM mapped by each operator to the total volume of each chamber of the Phantom as measured by the CT scan (RA 96.9 ml; LA 85.8 ml; RV 137 ml; LV 112 ml, Ao 130 ml).

Finally, considering the time (in seconds) that each operator needed for the intervention, we designed a grading algorithm based on the mean number of seconds that each operator needed to complete the FAM of each chamber, compared to the best achieved and the worst achieved times. We took the best time achieved, which we annotated as MIN (in seconds) and the worst time, annotated as MAX (in seconds) and subtracted the MIN from the MAX, to identify the range of seconds between the two, which was then assigned a value from 0 to 100. We compared each of the times we wanted to grade (annotated as X) with the MIN to determine how many extra seconds did one operator take for the intervention, compared to the best achieved time. Then we took the number of seconds obtained and multiplied it by the number of grading points we previously achieved ( $100/((MAX-MIN))$ ). Since the longer the time needed, the lower the grade, we reversed the percentage by subtracting our obtained value from 100% in order to achieve our final grade. Therefore, the equation used is:

$$\text{Score} = 100 - (X - \text{MIN}) \times (100/((\text{MAX}-\text{MIN})))$$

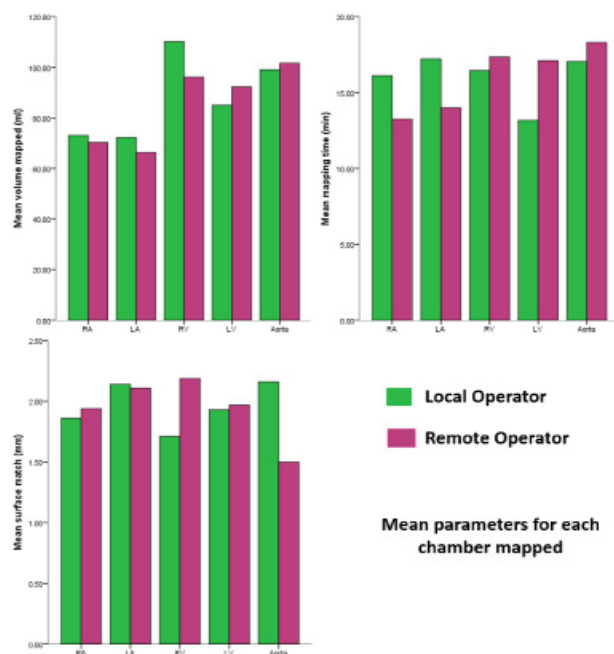
### Results

The two operators created 30 maps each, with 6 maps of each chamber per operator. The average mapping time was 16:08 min for all chambers. The mean volumes obtained for both operators were for RA 71.7±4.97 ml, LA 69.3±5.88 ml, RV 103.2±7.2 ml, LV 88.7±7.48 ml, and 100.4±4.5 ml for the aorta. The mean times for each chamber were 14:28±3:47 min for RA, 15:41±2:47 min for LA, 17:11±5:42 min for RV, 15:14±2:57 min for LV and 17:49±2:45 min for the aorta. The mean average surface mismatch were 1.90±1.51 mm for the RA, 2.12±1.7 mm for LA, 1.95±1.58 mm for RV, 1.95±1.67 mm for LV and 1.83±2.14 mm for the aorta.



**Figure 2:** Example of 3D maps acquired remote-controlled with 3 landmarks registration followed by surface map

Anatomical aorta maps acquired using the magnetic navigation system in the control room of the catheter lab (green) and via a remote online connection by a distantly located operator (pink)



**Figure 3:** Comparison of maps acquired locally (green) or distantly (pink) for RA, LA, RV, LV and aorta

Mean parameters for each chamber mapped by each operator. Green= local operator; LA= left atrium; LV= left ventricle; Pink= remote operator; RA= right atrium; RV= right ventricle.

Comparing overall results, mapping time and completeness when performed by the distant operator was not inferior to the local operator and both did not require any additional radiation exposure during the mapping process. Table 1 demonstrates the mean parameters for each chamber, respectively. Figure 3 demonstrates the comparison for the mean parameters between the two operators.

The distant operator used two different computer setups for the mapping sessions: one low performance for the first 15 maps and another high performance for the latter 15 maps. However, the performance of the two different computer setups did not make a significant difference in the composite endpoint (Figure 4).

In addition, there was no interruption of the mapping process for both operators in all the sessions. The overall session times exceeded 3 hours, which was similar to real EP procedures. Average uploads and download speed varied between 40 – 450 megabits per second and above 10 megabits per second, respectively (measurement lab report).

### Composite endpoint of map quality

There was not a significant difference in the scores for the composite endpoint of the local operator ( $M=61.72$ ,  $SD=3.562$ ) and of the distant operator ( $M=61.02$ ,  $SD=7.095$ ) conditions;  $t(0.196)$ ,  $p=0.850$ . These results suggest that the quality of the acquired maps between the two operators was as good when the mapping was either performed locally, with the operator on site, or when it was performed remotely, with the operator located more than 1200 km away controlling the RMN system via a stable internet connection.

Thus, distant mapping did not significantly differ compared to local remote mapping in terms of duration, total volume mapped and average

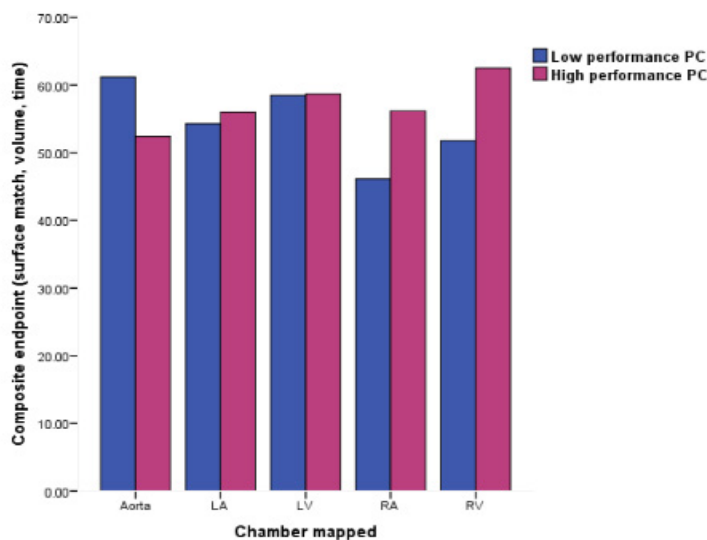
surface area match for each of the five chambers. Figure 5. demonstrates the comparison of the composite endpoints for each chamber mapped by the two operators.

In addition, the two different computer setups that the remote operator used did not make a significant difference in the composite endpoint for the low-performance PC ( $M=54.35$ ,  $SD=5.87$ ) and for the high-performance PC ( $M=57.14$ ,  $SD=3.71$ ) conditions;  $t(-.896)$ ,  $p=0.396$ . These results suggest that the quality of the acquired maps was similar for both computer specifications.

### Discussion

We report on our telerobotic interventional project imitating the 3D mapping typically performed during invasive EP procedures. Using a 3D phantom, 2 different operators mapped from either the control room or from a distant location all cardiac chambers. There was no significant difference between the mapping time, the 3D volume of the maps or average surface match, both for the individual parameters or the composite endpoint. In addition, the performance of the 2 different computer setups for the distantly located operator did not make a significant difference. However, the key for a successful remote mapping session is the speed and stability of the internet connection. Importantly, there were no interruptions of the connection in all mapping sessions, with similar session times compared to conventional EP procedures.

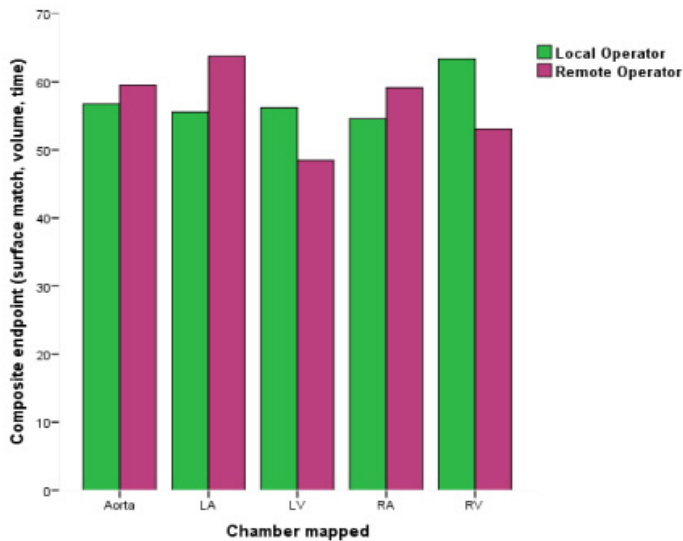
Our aim was to demonstrate the feasibility of telerobotic procedures in the EP setting and to compare the mapping performance of 2 operators, one located locally in the EP catheter lab control room and the second ~1200 km away connecting online. In this pilot-study, the results showed the non-inferiority of map quality for the remote operator as compared to the one on-site. This provides initial evidence that a distant operator can safely manipulate a magnetic EP catheter. The ability to provide expert remote support to on-site



**Figure 4:** Bar graphs for volume, mapping time, and surface match for both operators for all chambers

Composite endpoint (surface match, volume, time) for the remote operator on a scale from 0 to 100%. There was no significant statistical difference between the low and high-performance PC. LA= left atrium; LV= left ventricle; RA= right atrium; RV= right ventricle.





**Figure 5: Composite endpoint results**

Composite endpoint (surface match, volume, time) for each operator on a scale from 0 to 100%. There was no significant statistical difference between the two operators. Green= local operator; Pink= remote operator; LA= left atrium; LV= left ventricle; Pink= remote operator; RA= right atrium; RV= right ventricle.

teams for complex cases is a necessary development to continue the typical information provision of high quality of care for cardiac patients undergoing catheter ablation in times of limited domestic or international travel. This is particularly pertinent to catheter ablations using a RMN system which at our centre is utilised for more complex patients, such as those with congenital heart disease, that require the fluoroscopy image, EAM, EP recording system connected to a remotely located proctor<sup>6,21,22</sup>. RMN allows not only to observe but to directly interact and thereby support the local team with expert input of experienced physicians.

We demonstrated that distantly controlled mapping is feasible with the same accuracy results; however, the need for local teams is still manifest for positioning of the catheters, initiation of ablation and dealing with potential complications. Importantly, the distant operator cannot initiate the radiofrequency ablation via the remote connection, but can solely navigate the catheter to the ablation target. There is therefore still a requirement for local expert teams to work alongside remote operators. As a mean of safety during ablation, the local EP lab set-up will always override the distant operator as soon as the local team interacts with the system. Last but not least, optimal team cooperation is key for a successful procedure.

In this regard, RMN is especially well suited for telerobotic interventions as the Odyssey platform offers full disclosure of the 3D mapping and EP recordings with full interactivity. The soft-tipped nature of the magnetic catheter that has a very low contact force and a virtually zero risk of cardiac perforation adds to the safety of the procedure.

The future outlooks – global collaborations are possible across many time zones enabling expert teams to support complex procedures and further controlled trials involving different catheter types, simulations

of ablations and in vivo studies are needed to establish the role of telerobotic interventions in the usual practice of physicians around the world.

### Limitation

There was no proper assessment of the latency as the EP systems did not provide any direct assessment for this. Latency of the internet connection varied between 14 and 85 ms when tested. This study only looked at the mapping and diagnostics, whilst the therapeutic effect should be further assessed in other models.

### Conclusion

A distant operator located more than 1200 km away from the magnetic navigation lab connected online is able to perform 3D electro anatomical maps of all cardiac chambers of a phantom with equal accuracy and procedure parameters as compared to an operator located in the control room. These results support the feasibility of truly remote-controlled procedures which would allow an expert operator to actively support a local team in EP interventions. However, in this study only mapping was assessed, whilst the therapeutic effect should be further assessed in a similar model or animal models.

### References

- Madder, R.D., et al., Robotic telesteering performance in transcontinental and regional pre-clinical models. *Catheter Cardiovasc Interv*, 2021. 97(3): p. E327-E332.
- Mahmud, E., et al., Robotic Peripheral Vascular Intervention With Drug-Coated Balloons is Feasible and Reduces Operator Radiation Exposure: Results of the Robotic-Assisted Peripheral Intervention for Peripheral Artery Disease (RAPID) Study II. *J Invasive Cardiol*, 2020. 32(10): p. 380-384.
- Patel, T.M., S.C. Shah, and S.B. Pancholy, Long Distance Tele-Robotic-Assisted Percutaneous Coronary Intervention: A Report of First-in-Human Experience. *EClinicalMedicine*, 2019. 14: p. 53-58.
- Pereira, V., et al., First-in-human, robotic-assisted neuroendovascular intervention. *Journal of NeuroInterventional Surgery*, 2020. 12: p. neurintsurg-2019.
- Pappone, C., et al., Robotic magnetic navigation for atrial fibrillation ablation. *J Am Coll Cardiol*, 2006. 47(7): p. 1390-400.
- Schmidt, B., et al., Remote navigation systems in electrophysiology. *Europace*, 2008. 10 Suppl 3: p. iii57-61.
- Shurrab, M., et al., Robotics in invasive cardiac electrophysiology. *Expert Rev Med Devices*, 2014. 11(4): p. 375-81.
- Wang, N., et al., Robot-assisted Hybrid Coronary Revascularisation: Systematic Review. *Heart Lung Circ*, 2015. 24(12): p. 1171-9.
- Adachi, T., et al., Audiovisual telesupport system for cardiovascular catheter interventions: A preliminary report on the clinical implications. *Catheter Cardiovasc Interv*, 2020. 95(5): p. 906-910.
- Shinoda, Y., et al., Early clinical experience of radiofrequency catheter ablation using an audiovisual telesupport system. *Heart Rhythm*, 2020. 17(5 Pt B): p. 870-875.
- Ernst, S., et al., Initial experience with remote catheter ablation using a novel magnetic navigation system: magnetic remote catheter ablation. *Circulation*, 2004. 109(12): p. 1472-5.
- Faddis, M.N. and B.D. Lindsay, Magnetic catheter manipulation. *Coron Artery Dis*, 2003. 14(1): p. 25-7.
- Weisz, G., et al., Safety and feasibility of robotic percutaneous coronary intervention: PRECISE (Percutaneous Robotically-Enhanced Coronary Intervention) Study. *J Am Coll Cardiol*, 2013. 61(15): p. 1596-600.
- Pourdjabbar, A., et al., Robotics in percutaneous cardiovascular interventions. *Expert*

- Rev Cardiovasc Ther, 2017. 15(11): p. 825-833.
15. Wegermann, Z.K., R.V. Swaminathan, and S.V. Rao, Cath Lab Robotics: Paradigm Change in Interventional Cardiology? *Curr Cardiol Rep*, 2019. 21(10): p. 119.
  16. Aagaard, P., et al., Remote Magnetic Navigation: A Focus on Catheter Ablation of Ventricular Arrhythmias. *J Cardiovasc Electrophysiol*, 2016. 27 Suppl 1: p. S38-44.
  17. Nagarajan, V.D., et al., Artificial intelligence in the diagnosis and management of arrhythmias. *Eur Heart J*, 2021.
  18. Weiss, J.P., Partnering with robotic technology in electrophysiology: have we arrived at a tipping point? *Curr Opin Cardiol*, 2020. 35(1): p. 8-12.
  19. Mahmud, E., et al., Robotic technology in interventional cardiology: Current status and future perspectives. *Catheter Cardiovasc Interv*, 2017. 90(6): p. 956-962.
  20. Mangels, D.R., et al., Robotic-assisted percutaneous coronary intervention. *Catheter Cardiovasc Interv*, 2017. 90(6): p. 948-955.
  21. Ernst, S., Robotic approach to catheter ablation. *Curr Opin Cardiol*, 2008. 23(1): p. 28-31.
  22. Ernst, S., Magnetic and robotic navigation for catheter ablation: "joystick ablation". *J Interv Card Electrophysiol*, 2008. 23(1): p. 41-4.